Ha`awina 13: HLTH 140

The Skeletal System

Hō`ulu`ulu Pōkole (Overview)

The skeletal system includes all of the bones, cartilages, and ligaments of the body that support and give shape to the body and body structures. The skeleton consists of the bones of the body. For adults, there are 206 bones in the skeleton. Younger individuals have higher numbers of bones because some bones fuse together during childhood and adolescence to form an adult bone. The primary functions of the skeleton are to provide a rigid, internal structure that can support the weight of the body against the force of gravity, and to provide a structure upon which muscles can act to produce movements of the body. The lower portion of the skeleton is specialized for stability during walking or running. In contrast, the upper skeleton has greater mobility and ranges of motion, features that allow you to lift and carry objects or turn your head and trunk.

In addition to providing for support and movements of the body, the skeleton has protective and storage functions. It protects the internal organs, including the brain, spinal cord, heart, lungs, and pelvic organs. The bones of the skeleton serve as the primary storage site for important minerals such as calcium and phosphate. The bone marrow found within bones stores fat and houses the blood-cell producing tissue of the body.

The skeleton is subdivided into two major divisions—the axial and appendicular.

Ke Haumana ka `apo (Student Learning Outcomes)

1. Describe the primary functions of the musculoskeletal system
2. Apply word building skills to the terminology of the musculoskeletal system.
3. Describe common abbreviations associated with the musculoskeletal system
4. Recognize, define, and pronounce medical terminology associated with the musculoskeletal system correctly.

The Axial and Appendicular Skeleton

The skeleton is subdivided into two major divisions—the axial and appendicular. The axial skeleton forms the vertical, central axis of the body and includes all bones of the head, neck, chest, and back (Figure). It serves to protect the brain, spinal cord, heart, and lungs. It also serves as the attachment site for muscles that move the head, neck, and back, and for muscles that act across the shoulder and hip joints to move their corresponding limbs.

The axial skeleton of the adult consists of 80 bones, including the skull, the vertebral column, and the thoracic cage. The skull is formed by 22 bones. Also associated with the head are an additional seven bones, including the hyoid bone and the ear ossicles (three small bones found in each middle ear). The vertebral column consists of 24 bones, each called a vertebra, plus the sacrum and coccyx. The thoracic cage includes the 12 pairs of ribs, and the sternum, the flattened bone of the anterior chest.

The appendicular skeleton includes all bones of the upper and lower limbs, plus the bones that attach each limb to the axial skeleton. There are 126 bones in the appendicular skeleton of an adult. The bones of the appendicular skeleton are covered in later section on bones of the upper extremities and the lower extremities.

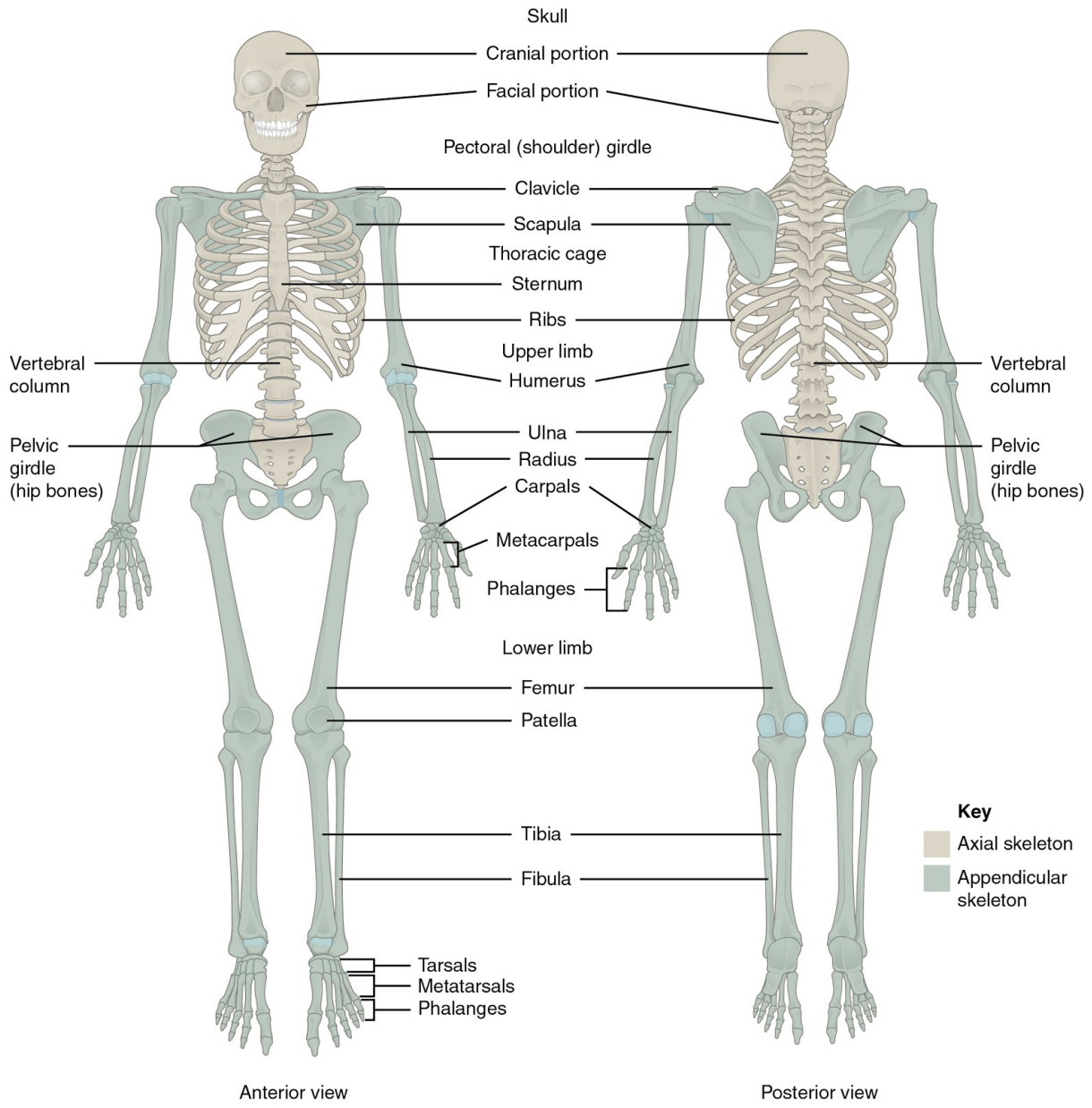

The Skull

The cranium (skull) is the skeletal structure of the head that supports the face and protects the brain. It is subdivided into the facial bones and the brain case, or cranial vault (Figure). The facial bones underlie the facial structures, form the nasal cavity, enclose the eyeballs, and support the teeth of the upper and lower jaws. The rounded brain case surrounds and protects the brain and houses the middle and inner ear structures.

In the adult, the skull consists of 22 individual bones, 21 of which are immobile and united into a single unit. The 22nd bone is the mandible (lower jaw), which is the only moveable bone of the skull.

Parts of the Skull

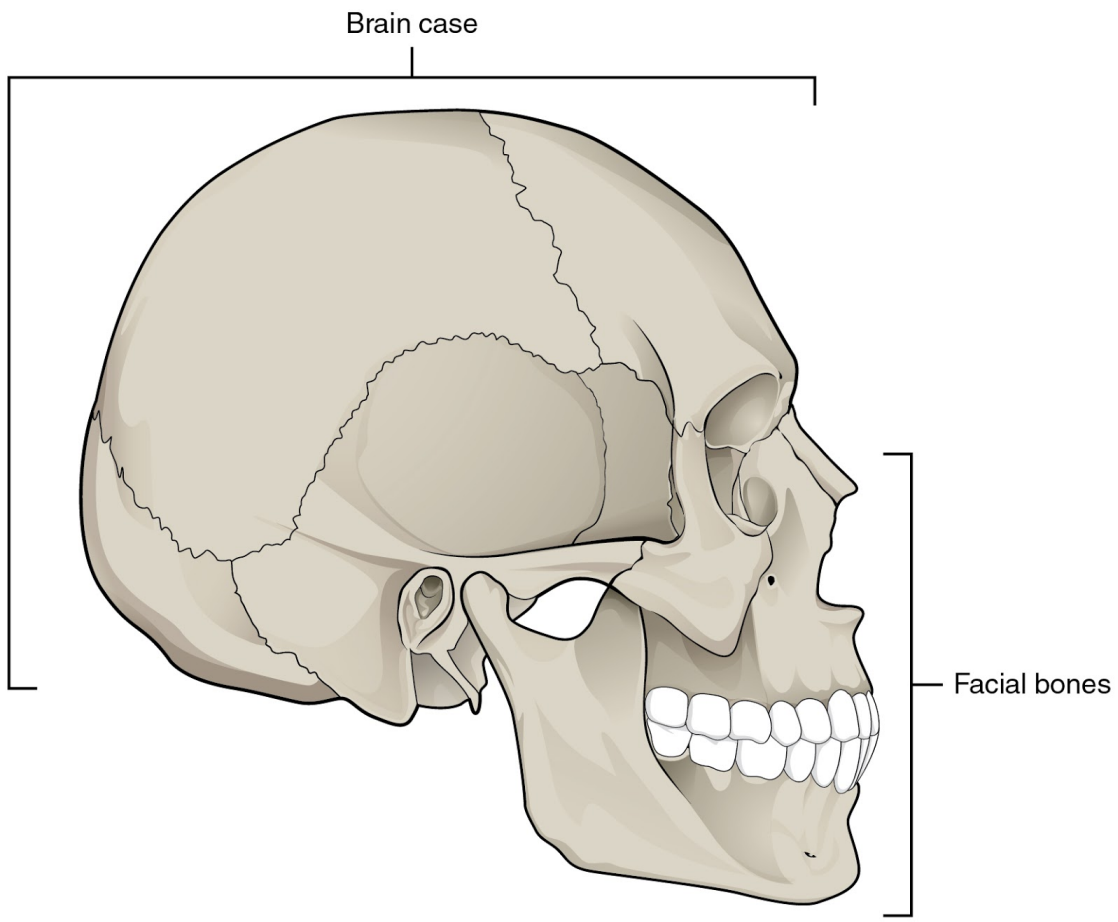

The skull consists of the rounded brain case that houses the brain and the facial bones that form the upper and lower jaws, nose, orbits, and other facial structures.

Watch this video to view a rotating and exploded skull, with color-coded bones. Which bone (yellow) is centrally located and joins with most of the other bones of the skull?

Anterior View of Skull

The anterior skull consists of the facial bones and provides the bony support for the eyes and structures of the face. This view of the skull is dominated by the openings of the orbits and the nasal cavity. Also seen are the upper and lower jaws, with their respective teeth (Figure).

The orbit is the bony socket that houses the eyeball and muscles that move the eyeball or open the upper eyelid. The upper margin of the anterior orbit is the supraorbital margin. Located near the midpoint of the supraorbital margin is a small opening called the supraorbital foramen. This provides for passage of a sensory nerve to the skin of the forehead. Below the orbit is the infraorbital foramen, which is the point of emergence for a sensory nerve that supplies the anterior face below the orbit.

Anterior View of Skull

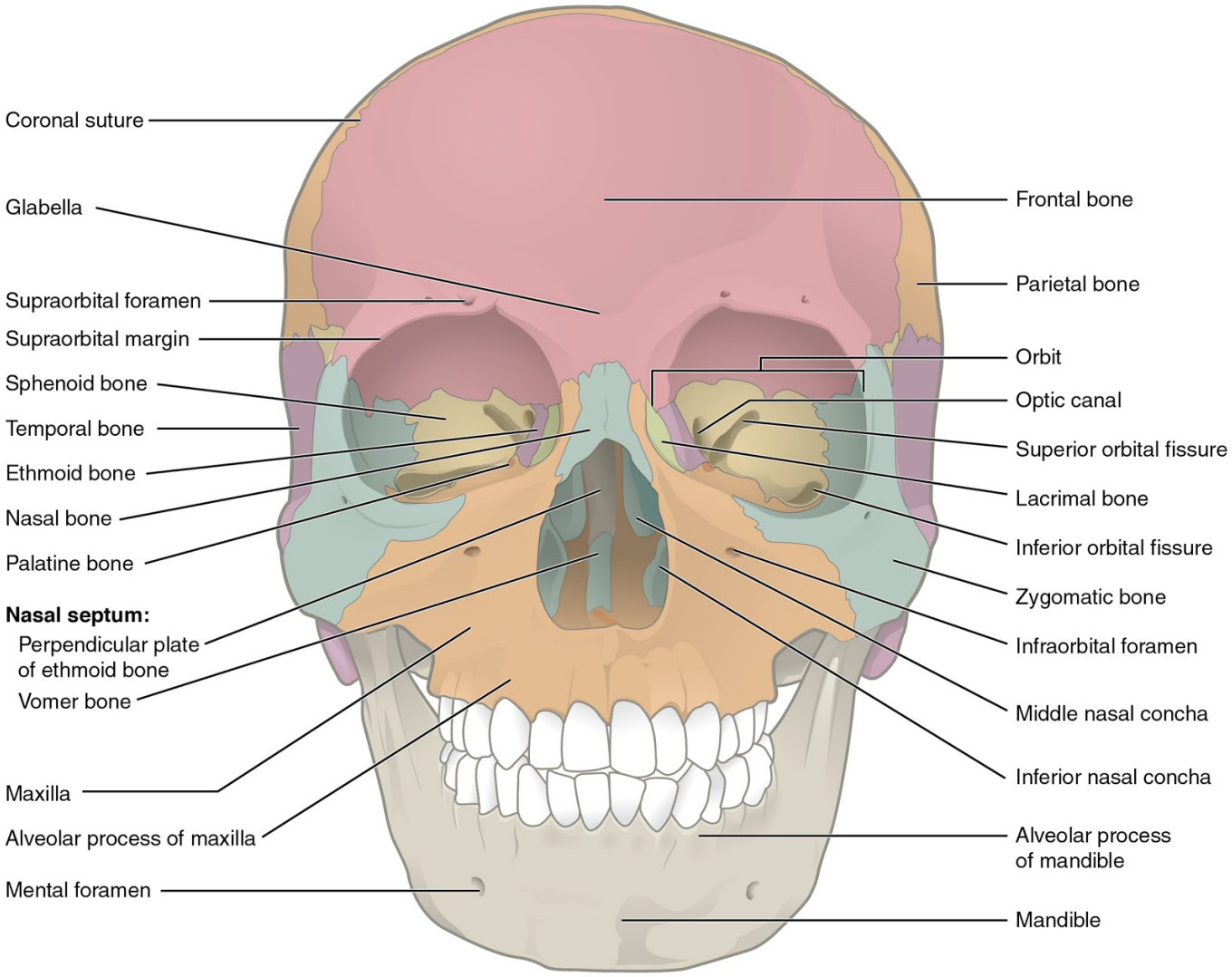

Anterior view

An interior view of the skull shows the bones that form the forehead, orbits (eye sockets), nasal cavity, nasal septum, and upper and lower jaws.

Lateral View of Skull

A view of the lateral skull is dominated by the large, rounded brain case above and the upper and lower jaws. Separating these areas is the bridge of bone called the zygomatic arch. The zygomatic arch is the bony arch on the side of skull that spans from the area of the cheek to just above the ear canal. The temporal process (anteriorly) and the zygomatic process (posteriorly) join together, like the two ends of a drawbridge, to form the zygomatic arch.

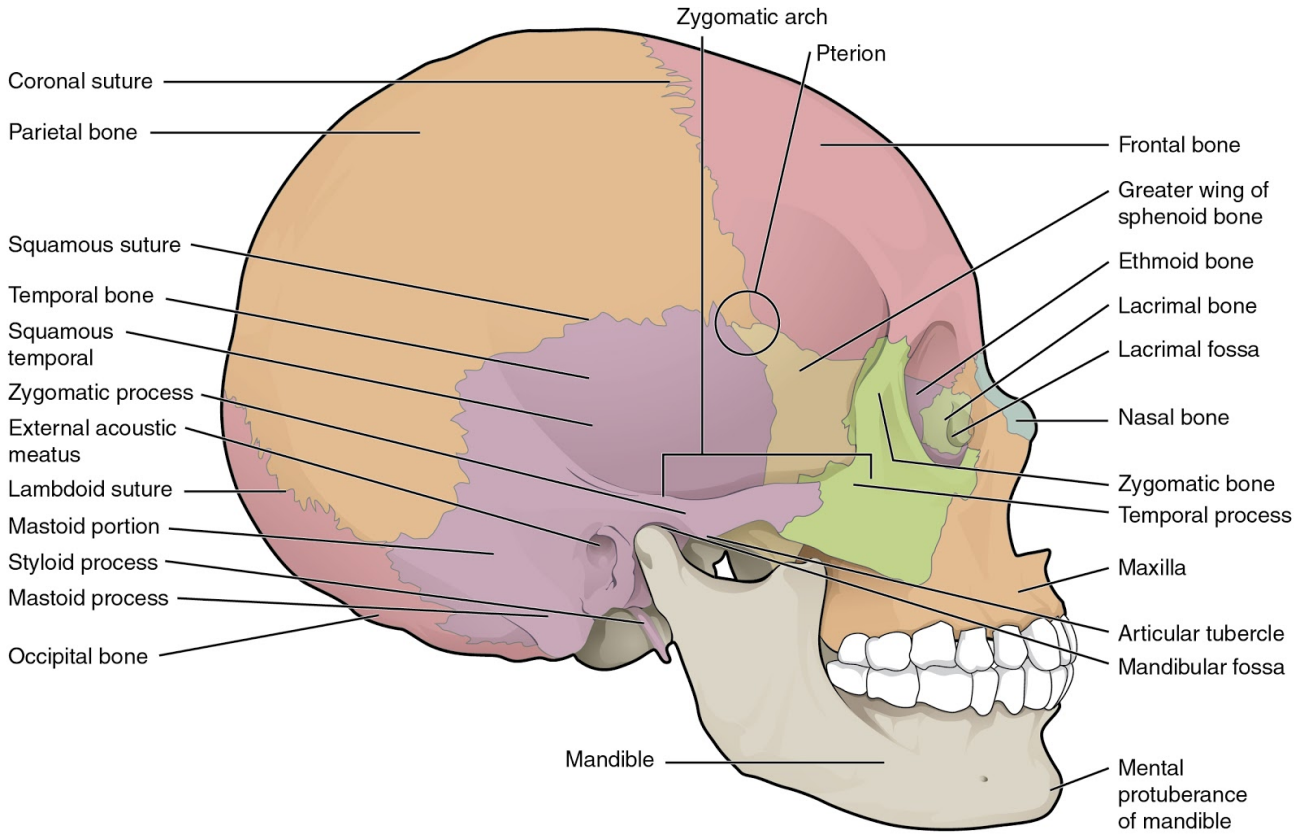

Right lateral view

Parietal Bone

The parietal bone forms most of the upper lateral side of the skull. These are paired bones, with the right and left parietal bones joining together at the top of the skull. Each parietal bone is also bounded anteriorly by the frontal bone, inferiorly by the temporal bone, and posteriorly by the occipital bone.

Temporal Bone

The temporal bone forms the lower lateral side of the skull (see Figure). Common wisdom has it that the temporal bone (temporal = "time") is so named because this area of the head (the temple) is where hair typically first turns gray, indicating the passage of time.

Projecting inferiorly from the temporal bone is a large prominence, the mastoid process, which serves as a muscle attachment site. The mastoid process can easily be felt on the side of the head just behind your earlobe. On the interior of the skull, the petrous portion of each temporal bone forms the prominent, diagonally oriented petrous ridge in the floor of the cranial cavity. Located inside each petrous ridge are small cavities that house the structures of the middle and inner ears.

Important landmarks of the temporal bone include the following:

- External acoustic meatus (ear canal)
- Internal acoustic meatus: This opening connects to the middle and inner ear cavities of the temporal bone.
- Mandibular fossa: The mandible (lower jaw) joins with the skull and allows opening and closing of the mouth.
- Articular tubercle:Both the articular tubercle and mandibular fossa provides lower jaw movement
- Styloid process: Named because it looks like a stylus (a pen or writing tool). This structure serves as an attachment for muscles and ligaments of the neck

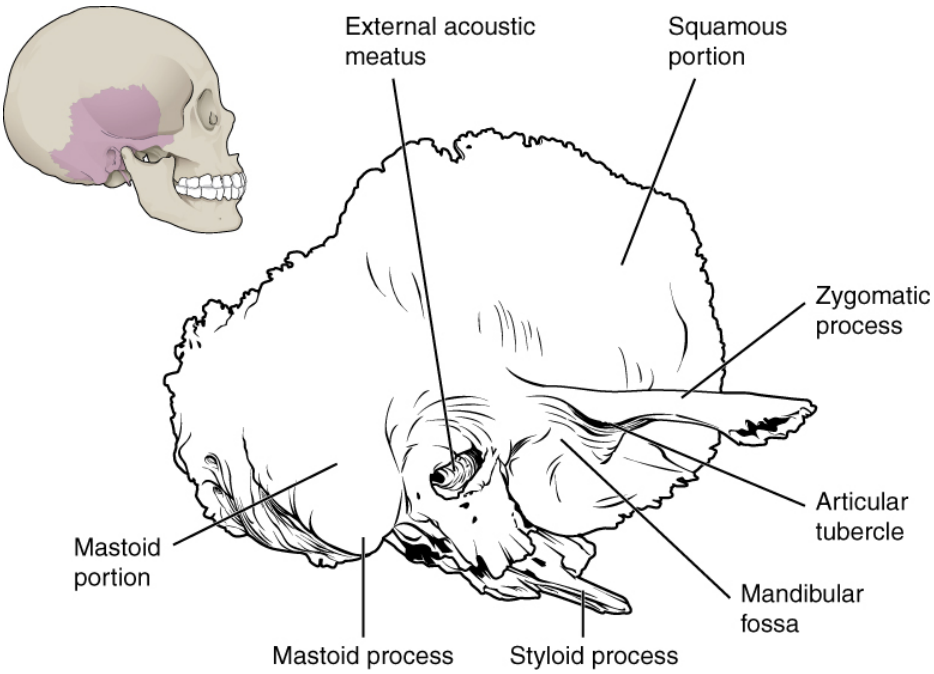

External and Internal Views of Base of Skull

Frontal Bone

The frontal bone is the single bone that forms the forehead. At its anterior midline, between the eyebrows, there is a slight depression called the glabella. The frontal bone also forms the supraorbital margin of the orbits of the eye sockets.

Occipital Bone

The occipital bone is the single bone that forms the posterior skull and posterior base of the cranial cavity. On its outside surface, at the posterior midline, is a small protrusion called the external

occipital protuberance, which serves as an attachment site for a ligament of the posterior neck. Lateral to either side of this bump is a superior nuchal line (nuchal = “nape” or “posterior neck”). On the base of the skull, the occipital bone contains the large opening of the foramen magnum, which allows for passage of the spinal cord as it exits the skull.Posterior View of Skull

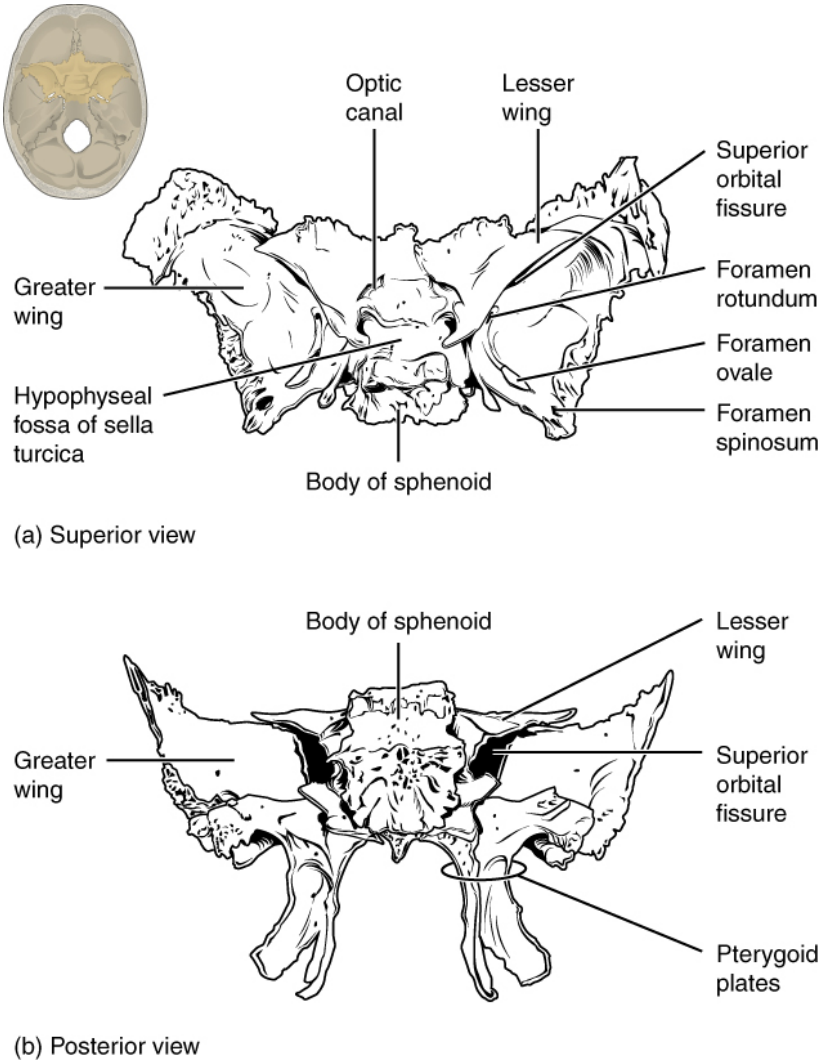

Sphenoid Bone

The sphenoid bone is a single, complex bone of the central skull (Figure). It serves as a “keystone” bone, because it joins with almost every other bone of the skull. The sella turcica (“Turkish saddle”) is located at the midline of the middle cranial fossa. This bony region of the sphenoid bone is named for its resemblance to the horse saddles used by the Ottoman Turks, with a high back and a tall front. The rounded depression in the floor of the sella turcica is the hypophyseal (pituitary) fossa, which houses the pea-sized pituitary (hypophyseal) gland.

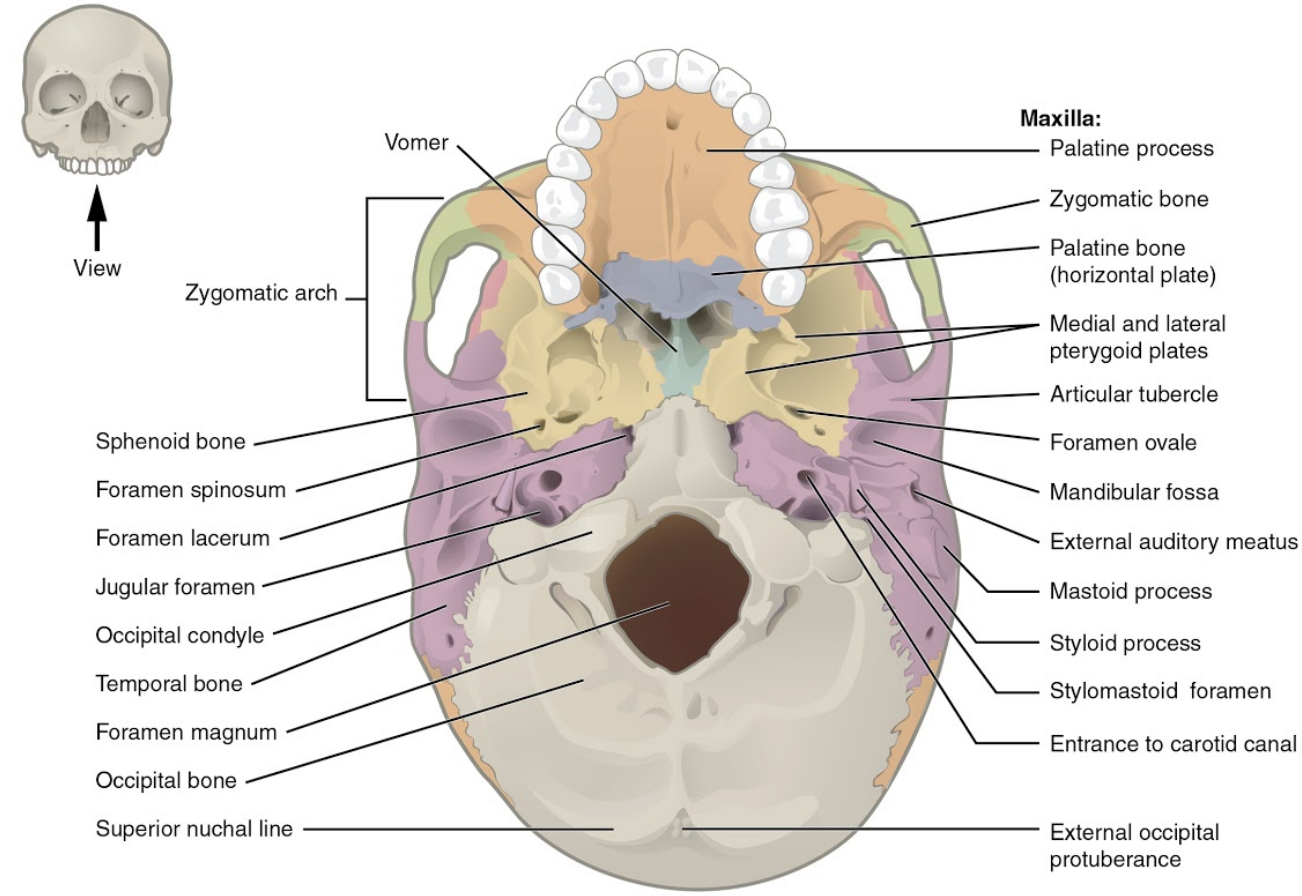

(a) Inferior view

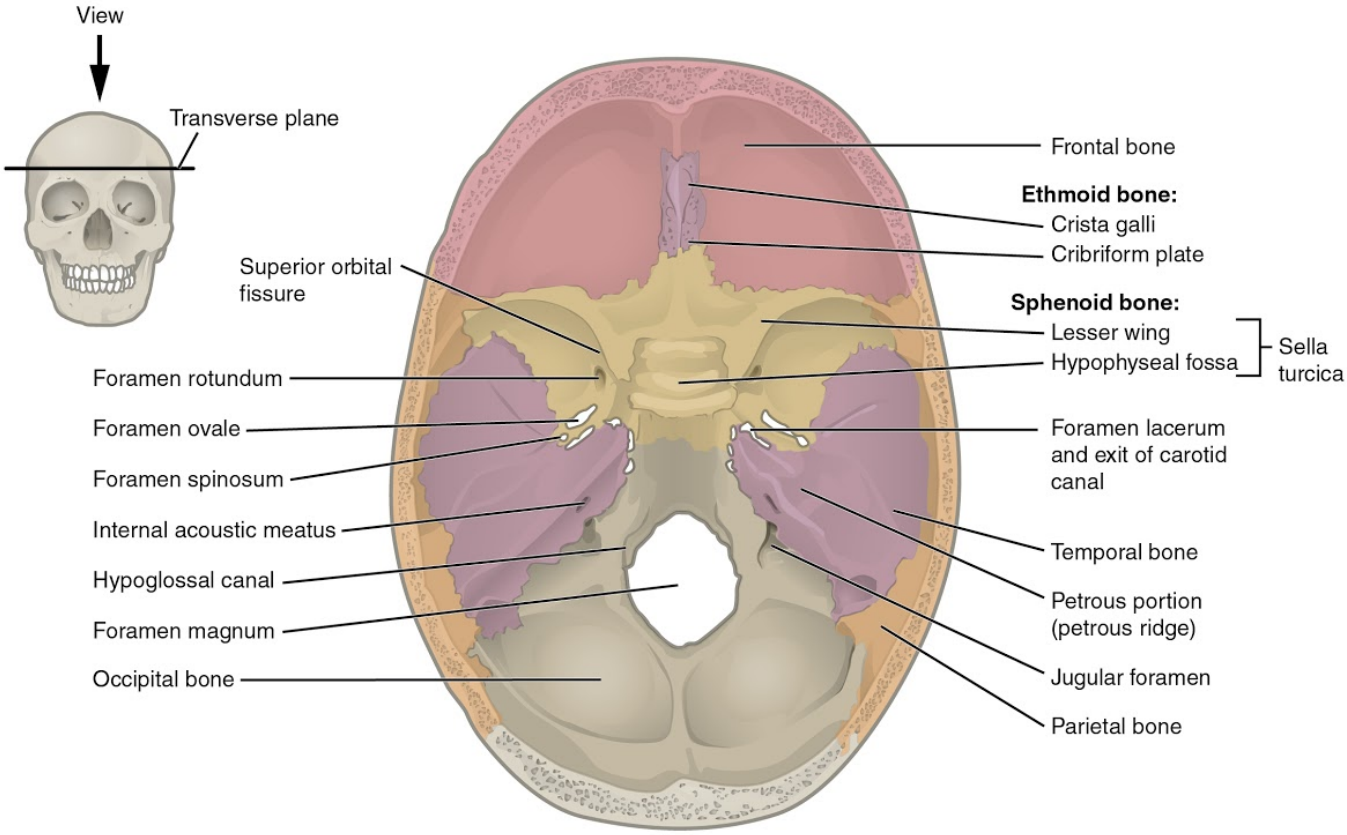

(b) Superior view

Ethmoid Bone

The ethmoid bone is a single, midline bone that forms the roof and lateral walls of the upper nasal cavity, the upper portion of the nasal septum, and contributes to the medial wall of the orbit (Figure and Figure). On the interior of the skull, the ethmoid also forms a portion of the floor of the anterior cranial cavity (see Figureb).

Within the nasal cavity, the perpendicular plate of the ethmoid bone forms the upper portion of the nasal septum. The ethmoid bone also forms the lateral walls of the upper nasal cavity. Extending from each lateral wall are the superior nasal concha and middle nasal concha, which are thin, curved projections that extend into the nasal cavity (Figure).

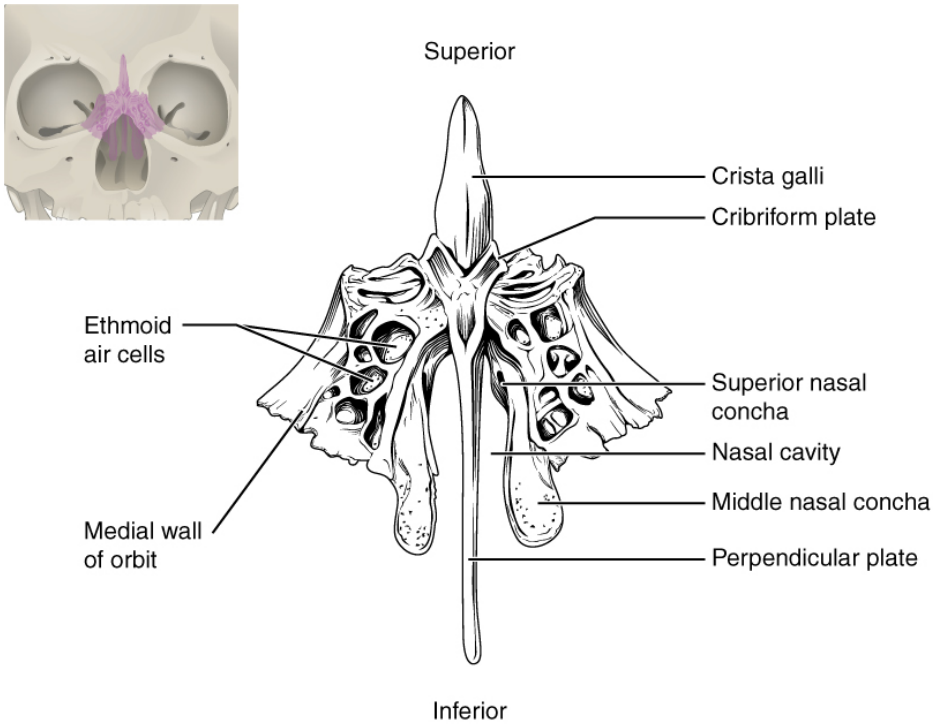

In the cranial cavity, the ethmoid bone forms a small area at the midline in the floor of the anterior cranial fossa. This region also forms the narrow roof of the underlying nasal cavity.

Sutures of the Skull

A suture is an immobile joint between adjacent bones of the skull. The narrow gap between the bones is filled with dense, fibrous connective tissue that unites the bones. The long sutures located between the bones of the brain case are not straight, but instead follow irregular, tightly twisting paths. These twisting lines serve to tightly interlock the adjacent bones, thus adding strength to the skull for brain protection.

The two suture lines seen on the top of the skull are the coronal and sagittal sutures. The coronal suture runs from side to side across the skull, within the coronal plane of section (see Figure). It joins the frontal bone to the right and left parietal bones. The sagittal suture extends posteriorly from the coronal suture, running along the midline at the top of the skull in the sagittal plane of section (see Figure). It unites the right and left parietal bones. On the posterior skull, the sagittal suture terminates by joining the lambdoid suture. The lambdoid suture extends downward and laterally to either side away from its junction with the sagittal suture. The lambdoid suture joins the occipital bone to the right and left parietal

and temporal bones. This suture is named for its upside-down "V" shape, which resembles the capital letter version of the Greek letter lambda (Λ). The squamous suture is located on the lateral skull. It unites the squamous portion of the temporal bone with the parietal bone (see Figure). At the intersection of four bones is the pterion, a small, capital-H-shaped suture line region that unites the frontal bone, parietal bone, squamous portion of the temporal bone, and greater wing of the sphenoid bone. It is the weakest part of the skull. The pterion is located approximately two finger widths above the zygomatic arch and a thumb's width posterior to the upward portion of the zygomatic bone.

DISORDERS OF THE…Skeletal System

Head and traumatic brain injuries are major causes of immediate death and disability, with bleeding and infections as possible additional complications. According to the Centers for Disease Control and Prevention (2010), approximately 30 percent of all injury-related deaths in the United States are caused by head injuries. The majority of head injuries involve falls. They are most common among young children (ages 0–4 years), adolescents (15–19 years), and the elderly (over 65 years). Additional causes vary, but prominent among these are automobile and motorcycle accidents.

Strong blows to the brain-case portion of the skull can produce fractures. These may result in bleeding inside the skull with subsequent injury to the brain. The most common is a linear skull fracture, in which fracture lines radiate from the point of impact. Other fracture types include a comminuted fracture, in which the bone is broken into several pieces at the point of impact, or a depressed fracture, in which the fractured bone is pushed inward. In a contrecoup (counterblow) fracture, the bone at the point of impact is not broken, but instead a fracture occurs on the opposite side of the skull. Fractures of the occipital bone at the base of the skull can occur in this manner, producing a basilar fracture that can damage the artery that passes through the carotid canal.

A blow to the lateral side of the head may fracture the bones of the pterion. The pterion is an important clinical landmark because located immediately deep to it on the inside of the skull is a major branch of an artery that supplies the skull and covering layers of the brain. A strong blow to this region can fracture the bones around the pterion. If the underlying artery is damaged, bleeding can cause the formation of a hematoma (collection of blood) between the brain and interior of the skull. As blood accumulates, it will put pressure on the brain. Symptoms associated with a hematoma may not be apparent immediately following the injury, but if untreated, blood accumulation will exert increasing pressure on the brain and can result in death within a few hours.

View this animation to see how a blow to the head may produce a contrecoup (counterblow) fracture of the basilar portion of the occipital bone on the base of the skull.

Facial Bones of the Skull

The facial bones of the skull form the upper and lower jaws, the nose, nasal cavity and nasal septum, and the orbit. The facial bones include 14 bones, with six paired bones and two unpaired bones. The paired bones are the maxilla, palatine, zygomatic, nasal, lacrimal, and inferior nasal conchae bones. The unpaired bones are the vomer and mandible bones. Although classified with the brain-case bones, the ethmoid bone also contributes to the nasal septum and the walls of the nasal cavity and orbit.

Maxillary Bone

The maxillary bone, often referred to simply as the maxilla (plural = maxillae), is one of a pair that together form the upper jaw, much of the hard palate, the medial floor of the orbit, and the lateral base of the nose (see Figure). The curved, inferior margin of the maxillary bone that forms the upper jaw and contains the upper teeth is the alveolar process of the maxilla (Figure). Each tooth is anchored into a deep socket called an alveolus. Each maxilla also forms the lateral floor of each orbit and the majority of the hard palate.

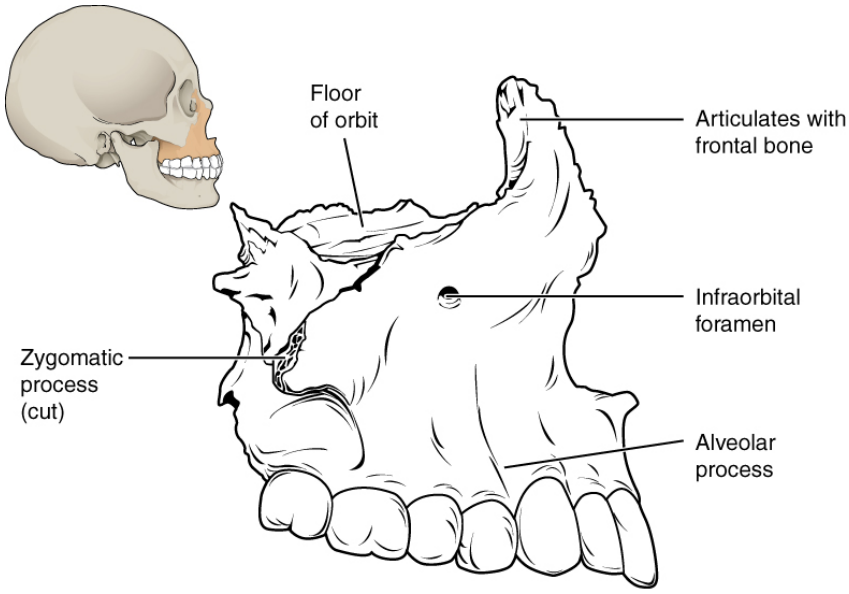

Right lateral view

Palatine Bone

The palatine bone is one of a pair of irregularly shaped bones that contribute small areas to the lateral walls of the nasal cavity and the medial wall of each orbit. The largest region of each of the palatine bone is the horizontal plate. The plates from the right and left palatine bones join together at the midline to form the posterior quarter of the hard palate (see Figurea). Thus, the palatine bones are best seen in an inferior view of the skull and hard palate.

HOMEOSTATIC IMBALANCES... Cleft Lip and Cleft Palate

During embryonic development, the right and left maxilla bones come together at the midline to form the upper jaw. At the same time, the muscle and skin overlying these bones join together to form the upper lip. Inside the mouth, the palatine processes of the maxilla bones, along with the horizontal plates of the right and left palatine bones, join together to form the hard palate. If an error occurs in these developmental processes, a birth defect of cleft lip or cleft palate may result.

Cleft lip is a common development defect that affects approximately 1:1000 births, most of which are male. This defect involves a partial or complete failure of the right and left portions of the upper lip to fuse together, leaving a cleft (gap).

A more severe developmental defect is cleft palate, which affects the hard palate. The hard palate is the bony structure that separates the nasal cavity from the oral cavity. It is formed during embryonic development by the midline fusion of the horizontal plates from the right and left palatine bones and the palatine processes of the maxilla bones. Cleft palate affects approximately 1:2500 births and is more common in females. It results from a

failure of the two halves of the hard palate to completely come together and fuse at the midline, thus leaving a gap between them. This gap allows for communication between the nasal and oral cavities. In severe cases, the bony gap continues into the anterior upper jaw where the alveolar processes of the maxilla bones also do not properly join together above the front teeth. If this occurs, a cleft lip will also be seen. Because of the communication between the oral and nasal cavities, a cleft palate makes it very difficult for an infant to generate the suckling needed for nursing, thus leaving the infant at risk for malnutrition. Surgical repair is required to correct cleft palate defects.

Zygomatic Bone

The zygomatic bone is also known as the cheekbone. Each of the paired zygomatic bones forms much of the lateral wall of the orbit and the lateral-inferior margins of the anterior orbital opening (see Figure). The short temporal process of the zygomatic bone projects posteriorly, where it forms the anterior portion of the zygomatic arch (see Figure).

Nasal Bone

The nasal bone is one of two small bones that articulate (join) with each other to form the bony base (bridge) of the nose. They also support the cartilages that form the lateral walls of the nose (see Figure). These are the bones that are damaged when the nose is broken.

Lacrimal Bone

Each lacrimal bone is a small, rectangular bone that forms the anterior, medial wall of the orbit (see Figure and Figure). The anterior portion of the lacrimal bone forms a shallow depression called the lacrimal fossa, and extending inferiorly from this is the nasolacrimal canal. The lacrimal fluid (tears of the eye), which serves to maintain the moist surface of the eye, drains at the medial corner of the eye into the nasolacrimal canal. This duct then extends downward to open into the nasal cavity, behind the inferior nasal concha. In the nasal cavity, the lacrimal fluid normally drains posteriorly, but with an increased flow of tears due to crying or eye irritation, some fluid will also drain anteriorly, thus causing a runny nose.

Inferior Nasal Conchae

The right and left inferior nasal conchae form a curved bony plate that projects into the nasal cavity space from the lower lateral wall (see Figure). The inferior concha is the largest of the nasal conchae and can easily be seen when looking into the anterior opening of the nasal cavity.

Vomer Bone

The unpaired vomer bone, often referred to simply as the vomer, is triangular-shaped and forms the posterior-inferior part of the nasal septum (see Figure). The vomer is best seen when looking from behind into the posterior openings of the nasal cavity (see Figurea). In this view, the vomer is seen to form the entire height of the nasal septum. A much smaller portion of the vomer can also be seen when looking into the anterior opening of the nasal cavity.

Mandible

The mandible forms the lower jaw and is the **only moveable bone of the skull**. At the time of birth, the mandible consists of paired right and left bones, but these fuse together during the first year to form the single U-shaped mandible of the adult skull. Each side of the mandible consists of a horizontal body and posteriorly, a vertically oriented ramus of the mandible (ramus = "branch"). The outside margin of the mandible, where the body and ramus come together is called the angle of the mandible (Figure).

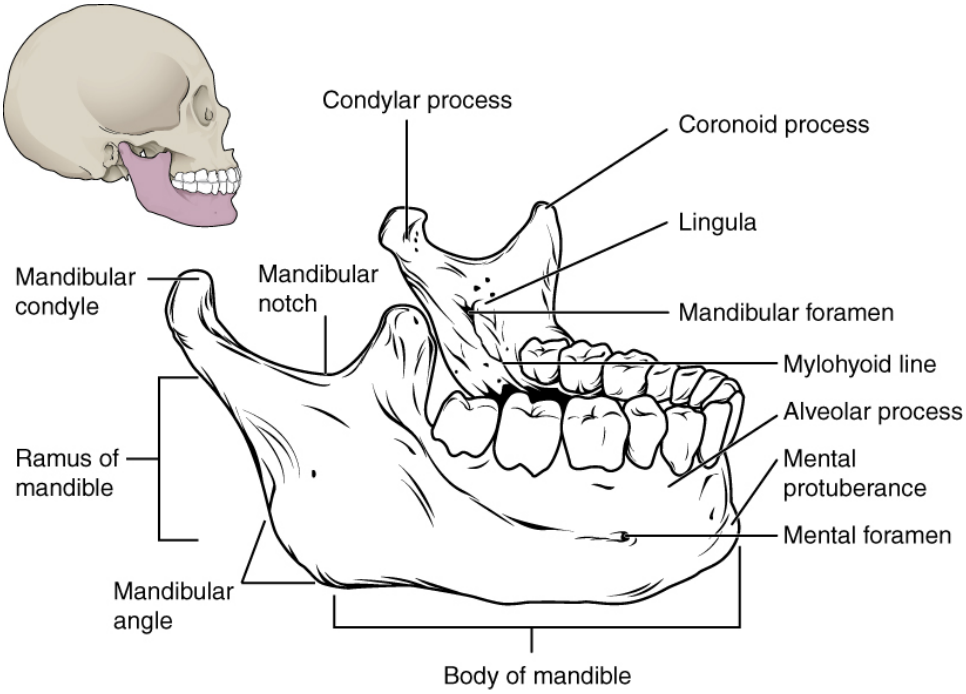

Right lateral view

The ramus on each side of the mandible has two upward-going bony projections. The more anterior projection is the flattened coronoid process of the mandible, which provides attachment for one of the biting muscles. The posterior projection is the condylar process of the mandible, which is topped by the oval-shaped condyle. The condyle of the mandible articulates (joins) with the mandibular fossa and articular tubercle of the temporal bone. Together these articulations form the temporomandibular joint, which allows for opening and closing of the mouth (see Figure). The broad U-shaped curve located between the coronoid and condylar processes is the mandibular notch.

Important landmarks for the mandible include the following:

- ❑ Alveolar process of the mandible—This is the upper border of the mandibular body and serves to anchor the lower teeth.
- ❑ Mental protuberance—The forward projection from the inferior margin of the anterior mandible that forms the chin (mental = "chin").
- ❑ Mental foramen—The opening located on each side of the anterior-lateral mandible, which is the exit site for a sensory nerve that supplies the chin.

- ❑ Mylohyoid line—This bony ridge extends along the inner aspect of the mandibular body (see Figure). The muscle that forms the floor of the oral cavity attaches to the mylohyoid lines on both sides of the mandible.
- ❑ Mandibular foramen—This opening is located on the medial side of the ramus of the mandible. The opening leads into a tunnel that runs down the length of the mandibular body. The sensory nerve and blood vessels that supply the lower teeth enter the mandibular foramen and then follow this tunnel. Thus, to numb the lower teeth prior to dental work, the dentist must inject anesthesia into the lateral wall of the oral cavity at a point prior to where this sensory nerve enters the mandibular foramen.
- ❑ Lingula—This small flap of bone is named for its shape (lingula = "little tongue"). It is located immediately next to the mandibular foramen, on the medial side of the ramus. A ligament that anchors the mandible during opening and closing of the mouth extends down from the base of the skull and attaches to the lingula.

The Orbit

The orbit is the bony socket that houses the eyeball and contains the muscles that move the eyeball or open the upper eyelid. Each orbit is cone-shaped, with a narrow posterior region that widens toward the large anterior opening. To help protect the eye, the bony margins of the anterior opening are thickened and somewhat constricted. The medial walls of the two orbits are parallel to each other but each lateral wall

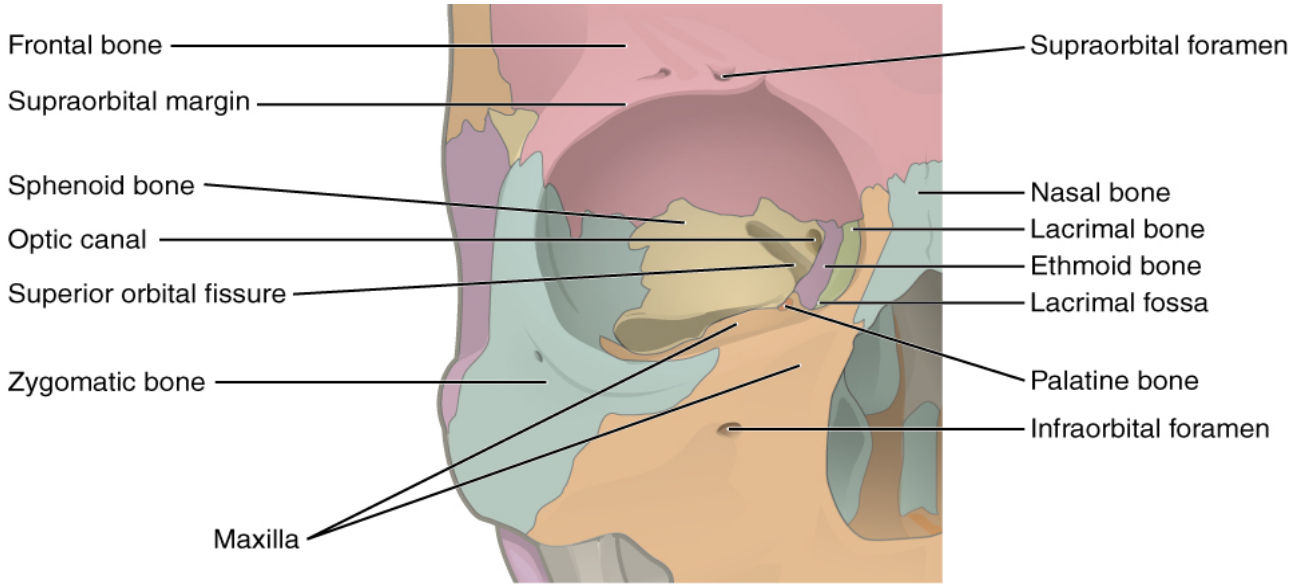

diverges away from the midline at a 45° angle. This divergence provides greater lateral peripheral vision. The walls of each orbit include contributions from seven skull bones (Figure). The frontal bone forms the roof and the zygomatic bone forms the lateral wall and lateral floor. The medial floor is primarily formed by the maxilla, with a small contribution from the palatine bone. The ethmoid bone and lacrimal bone make up much of the medial wall and the sphenoid bone forms the posterior orbit.

At the posterior apex of the orbit is the opening of the optic canal, which allows for passage of the optic nerve from the retina to the brain. Lateral to this is the elongated and irregularly shaped superior orbital

fissure, which provides passage for the artery that supplies the eyeball, sensory nerves, and the nerves that supply the muscles involved in eye movements. Seven skull bones contribute to the walls of the orbit. Opening into the posterior orbit from the cranial cavity are the optic canal and superior orbital fissure.

The Vertebral Column

The vertebral column is also known as the spinal column or spine (Figure). It consists of a sequence of **vertebrae** (singular = **vertebra**), each of which is separated and united by an intervertebral disc. Together, the vertebrae and intervertebral discs form the vertebral column. It is a flexible column that supports the head, neck, and body and allows for their movements. It also protects the spinal cord, which passes down the back through openings in the vertebrae.

Vertebral Column

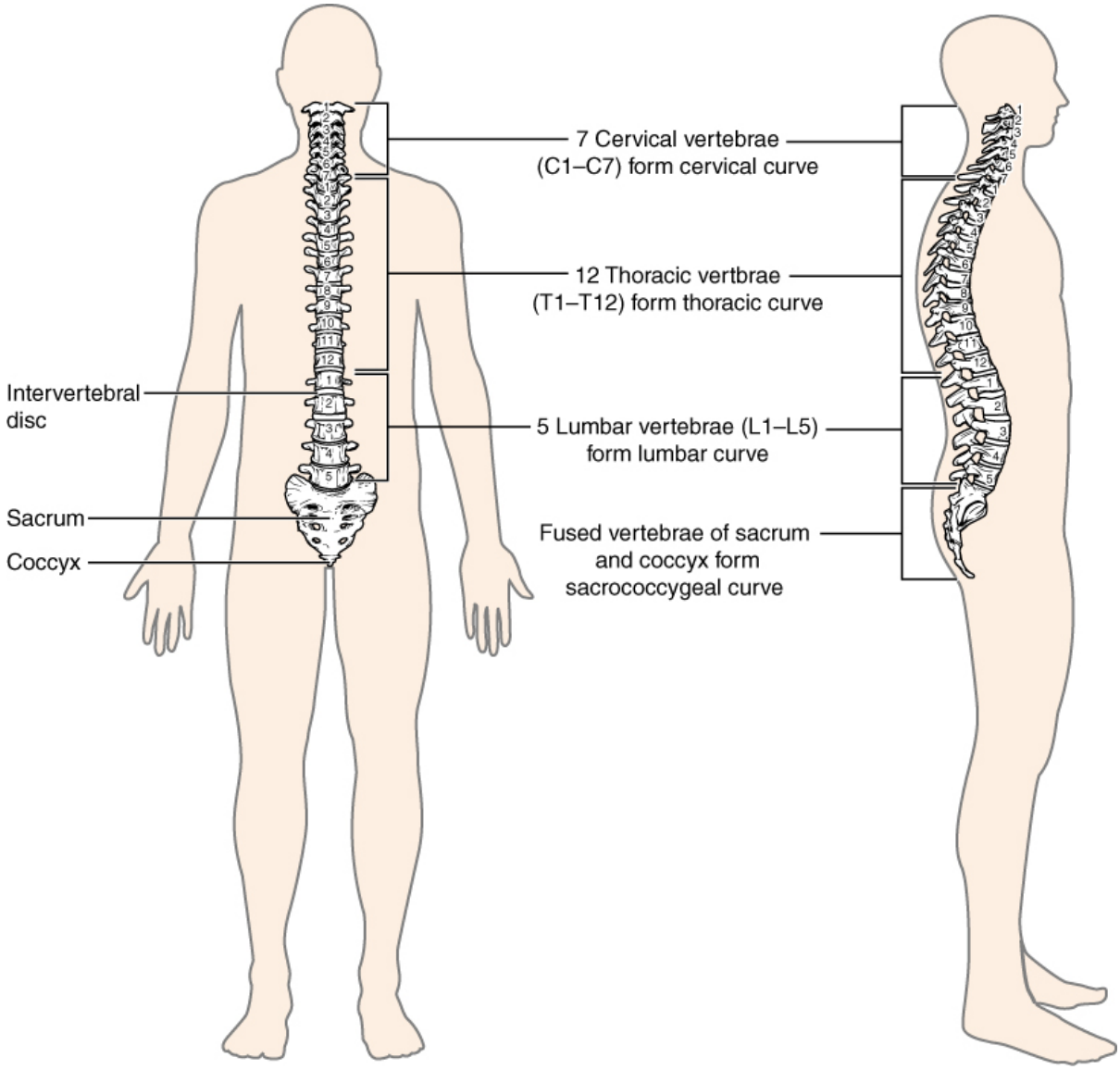

DISORDERS OF THE...Vertebral Column

Developmental anomalies, pathological changes, or obesity can enhance the normal vertebral column curves, resulting in the development of abnormal or excessive curvatures (Figure). Kyphosis, also referred to as humpback or hunchback, is an excessive posterior curvature of the thoracic region. This can develop when osteoporosis causes weakening and erosion of the anterior portions of the upper thoracic vertebrae, resulting in their gradual collapse (Figure). Lordosis, or swayback, is an excessive anterior curvature of the lumbar region and is most commonly associated with obesity or late pregnancy. The accumulation of body weight in the abdominal region results an anterior shift in the line of gravity that carries the weight of the body. This causes in an anterior tilt of the pelvis and a pronounced enhancement of the lumbar curve.

Scoliosis is an abnormal, lateral curvature, accompanied by twisting of the vertebral column. Compensatory curves may also develop in other areas of the vertebral column to help maintain the head positioned over the feet. Although most individuals do not require treatment, a back brace may be recommended for growing children. In extreme cases, surgery may be required.

Excessive vertebral curves can be identified while an individual stands in the anatomical position. Observe the vertebral profile from the side and then from behind to check for kyphosis or lordosis. Then have the person bend forward. If scoliosis is present, an individual will have difficulty in bending directly forward, and the right and left sides of the back will not be level with each other in the bent position.

Abnormal Curvatures of the Vertebral Column

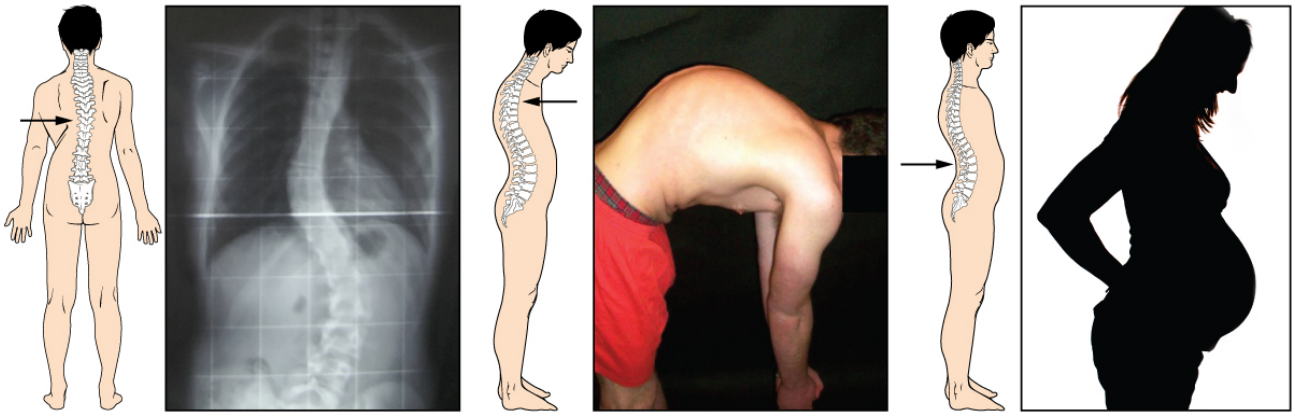

(a) Scoliosis (b) Kyphosis (c) Lordosis

(a) Scoliosis is an abnormal lateral bending of the vertebral column. (b) An excessive curvature of the upper thoracic vertebral column is called kyphosis. (c) Lordosis is an excessive curvature in the lumbar region of the vertebral column.

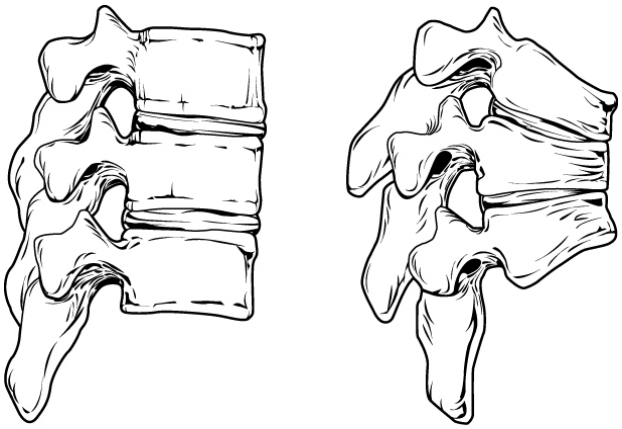

Osteoporosis

Osteoporosis is an age-related disorder that causes the gradual loss of bone density and strength. When the thoracic vertebrae are affected, there can be a gradual collapse of the vertebrae. This results in kyphosis, an excessive curvature of the thoracic region.

Structure of a Vertebra

A typical vertebra will consist of a body, a vertebral arch, and seven processes (Figure). The body is the anterior portion of each vertebra and is the part that supports the body weight. Because of this, the vertebral bodies progressively increase in size and thickness going down the vertebral column. The bodies of adjacent vertebrae are separated and strongly united by an intervertebral disc.

The large opening between the vertebral arch and body is the vertebral foramen, which contains the spinal cord. The vertebral foramina of all of the vertebrae align to form the vertebral (spinal) canal, which serves as the bony protection and passageway for the spinal cord down the back. Seven processes arise from the vertebral arch. The single spinous process (vertebral spine) projects posteriorly at the midline of the back. The vertebral spines can easily be felt as a series of bumps just under the skin down the middle of the back. The transverse and spinous processes serve as important muscle attachment sites.

Parts of a Typical Vertebra

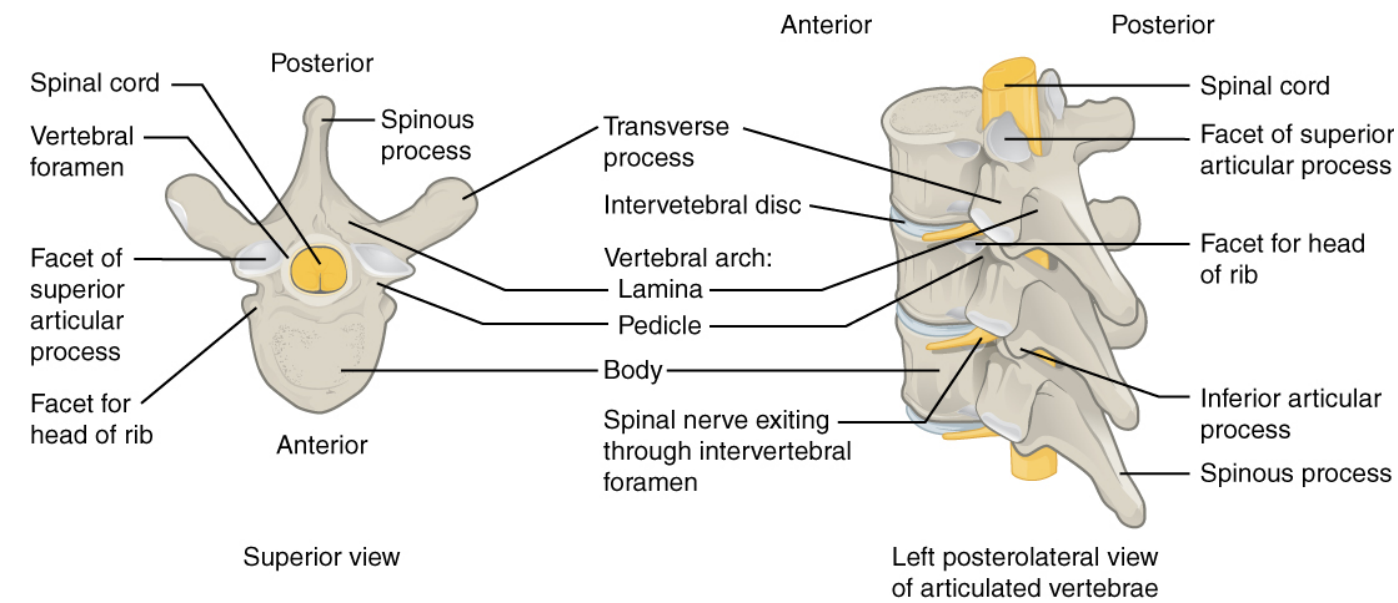

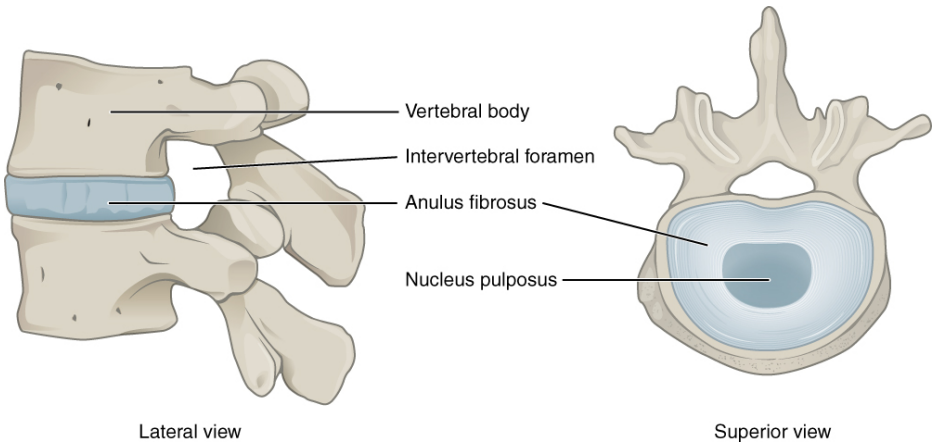

The bodies of adjacent vertebrae are separated and united by an intervertebral disc. The disc consists of a fibrous outer layer called the anulus fibrosus and a gel-like center called the nucleus pulposus. The intervertebral foramen is the opening formed between adjacent vertebrae for the exit of a spinal nerve.

Cervical Vertebrae

The first cervical (C1) vertebra is also called the atlas, because this is the vertebra that supports the skull on top of the vertebral column (in Greek mythology, Atlas was the god who supported the heavens on his shoulders). The C1 vertebra does not have a body or spinous process. Instead, it is ring-shaped, consisting of an anterior arch and a posterior arch. The transverse processes of the atlas are longer and extend more laterally than do the transverse processes of any other cervical vertebrae. The inferior articular processes are flat and face downward to join with the superior articular processes of the axis (C2) vertebra. The axis has the upward projecting dens, which articulates with the anterior arch of the atlas. The atlas allows the head to nod up and down, while the axis allows turning the head left and right. Together the atlas and axis are the most moveable vertebrae.

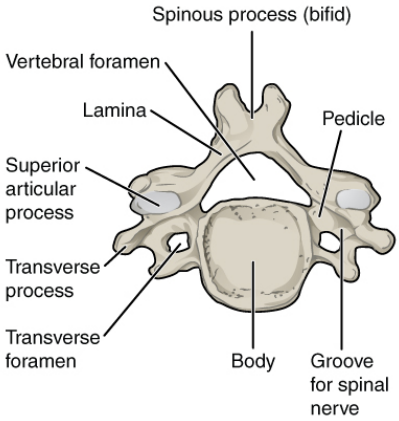

Structure of a typical cervical vertebra

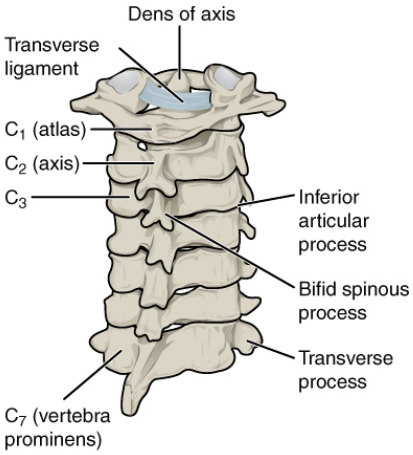

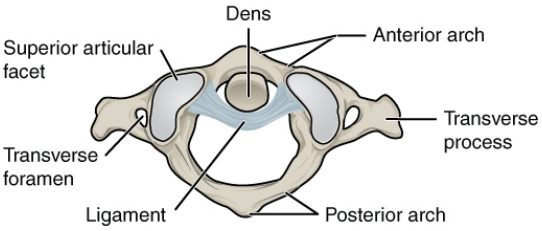

Superior view of atlas

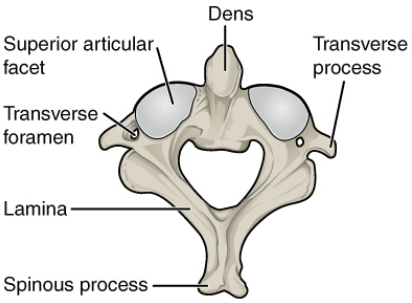

Superior view of axis

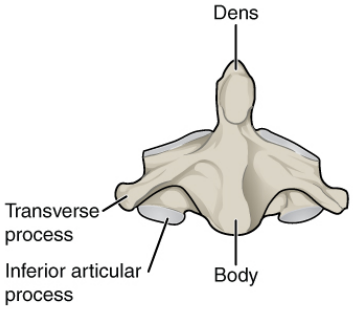

Anterior view of axis

Thoracic Vertebrae

The characteristic feature for a typical midthoracic vertebra is the spinous process, which is long and has a pronounced downward angle that causes it to overlap the next inferior vertebra. The superior articular processes of thoracic vertebrae face anteriorly and the inferior processes face posteriorly. These orientations are important determinants for the type and range of movements available to the upper back. Thoracic vertebrae have several additional articulation sites, called a facets, where a rib is attached.

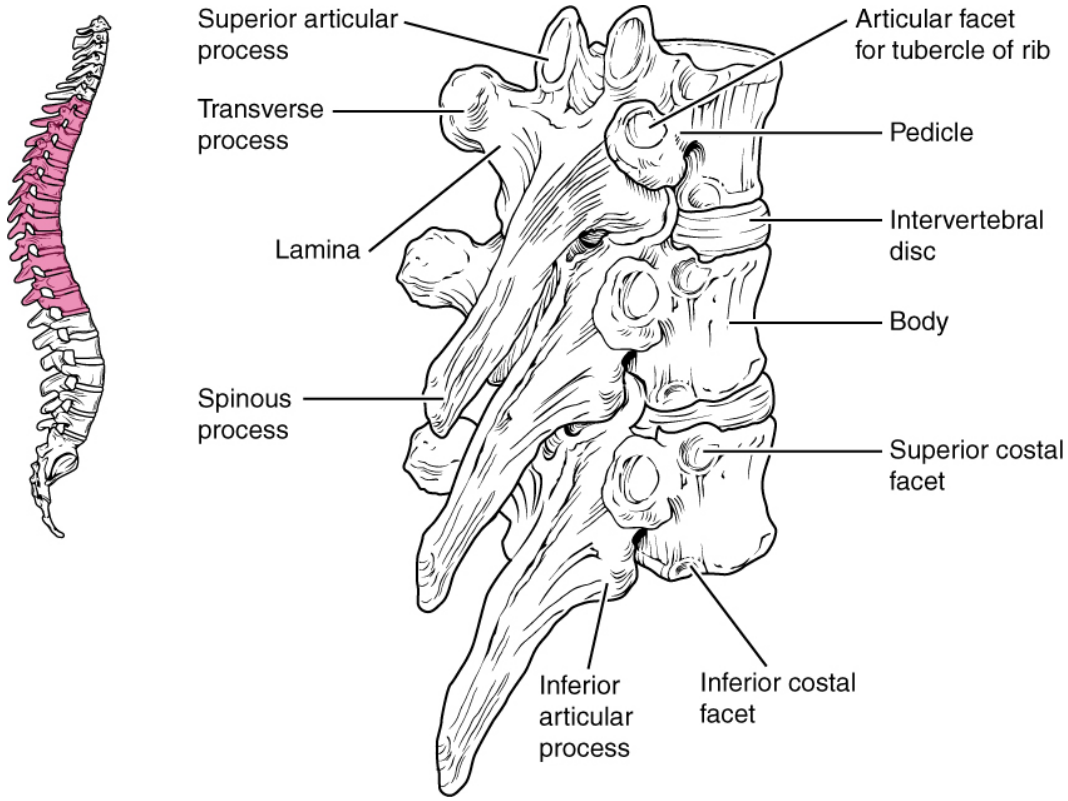

a

Thoracic Vertebrae

A typical thoracic vertebra is distinguished by the spinous process, which is long and projects downward to overlap the next inferior vertebra. It also has articulation sites (facets) on the vertebral body and transverse process for rib attachment.

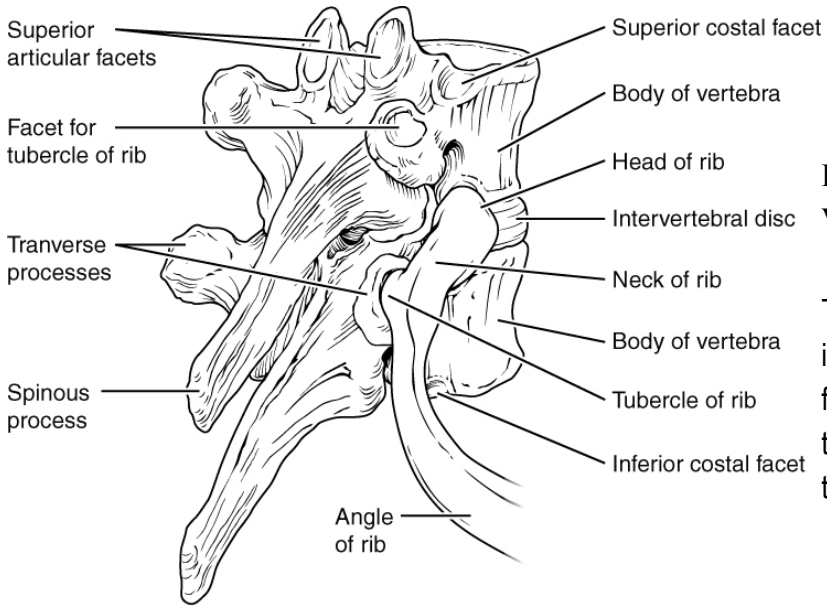

Rib Articulation in Thoracic Vertebrae

Thoracic vertebrae have superior and inferior articular facets on the vertebral body for articulation with the head of a rib, and a transverse process facet for articulation with the rib tubercle.

Lumbar Vertebrae

Lumbar vertebrae carry the greatest amount of body weight and are thus characterized by the large size and thickness of the vertebral body (Figure). They have short transverse processes and a short, blunt spinous process that projects posteriorly. The articular processes are large, with the superior process facing backward and the inferior facing forward.

Lumbar Vertebrae

Lumbar vertebrae are characterized by having a large, thick body and a short, rounded spinous process.

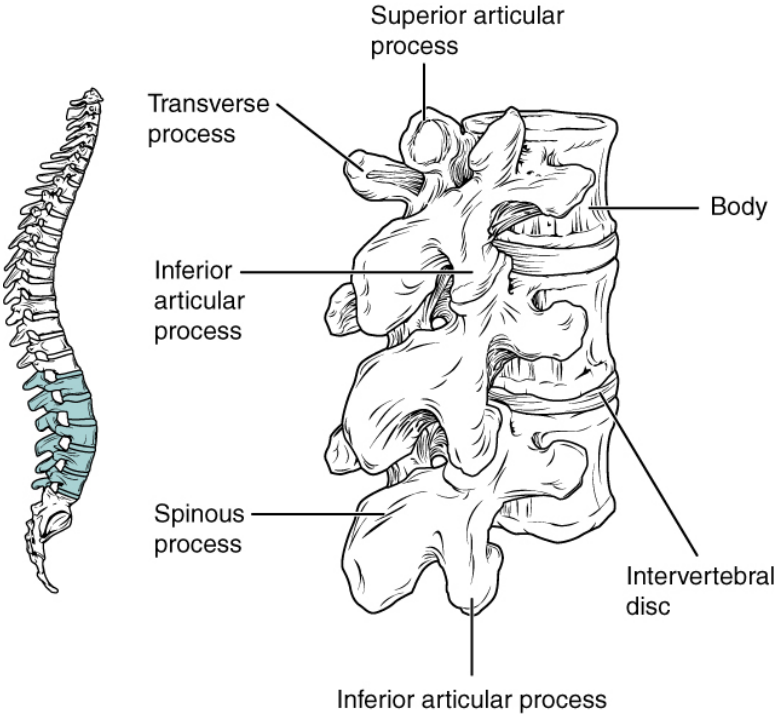

Sacrum and Coccyx

The sacrum is a triangular-shaped bone that is thick and wide across its superior base where it is weight bearing and then tapers down to an inferior, non-weight bearing apex (Figure). It is formed by the fusion of five sacral vertebrae, a process that does not begin until after the age of 20.The coccyx, or tailbone, is derived from the fusion of four very small coccygeal vertebrae (see Figure). It articulates with the inferior tip of the sacrum.

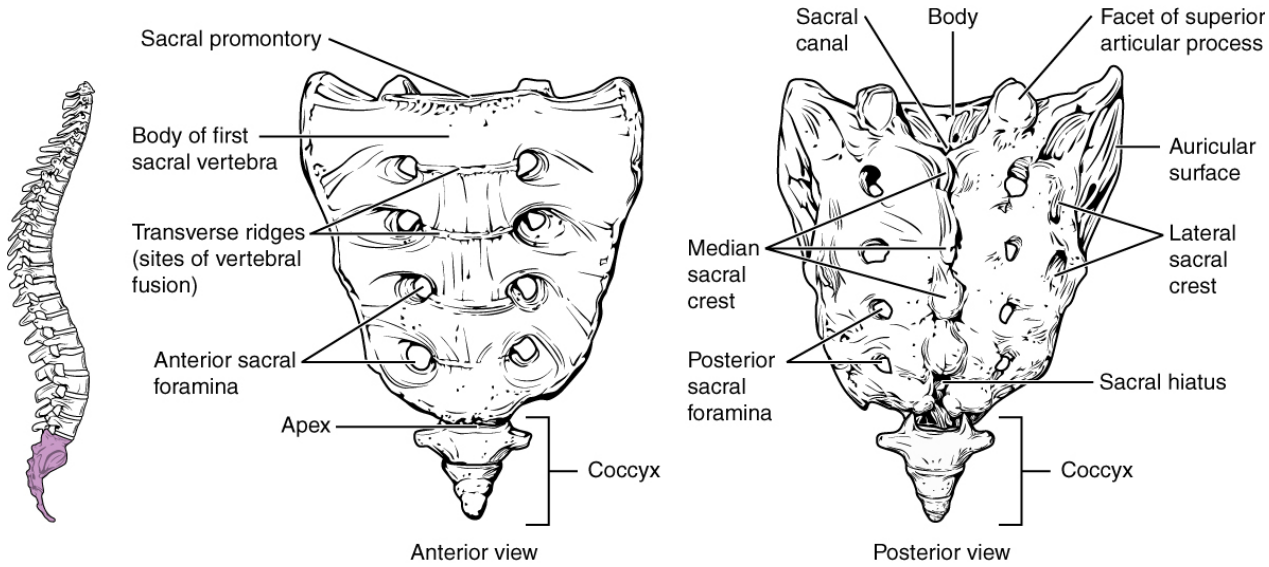

Intervertebral Discs and Ligaments of the Vertebral Column

The bodies of adjacent vertebrae are strongly anchored to each other by an intervertebral disc. This structure provides padding between the bones during weight bearing, and because it can change shape, also allows for movement between the vertebrae. Although the total amount of movement available between any two adjacent vertebrae is small, when these movements are summed together along the entire length of the vertebral column, large body movements can be produced. Ligaments that extend along the length of the vertebral column also contribute to its overall support and stability.

Clinical Connection...Herniated Vertebral Disc

If the posterior anulus fibrosus is weakened due to injury or increasing age, the pressure exerted on the disc when bending forward and lifting a heavy object can cause the nucleus pulposus to protrude posteriorly through the anulus fibrosus, resulting in a herniated disc ("ruptured" or "slipped" disc) (Figure). The posterior bulging of the nucleus pulposus can cause compression of a spinal nerve at the point where it exits through the intervertebral foramen, with resulting pain and/or muscle weakness in those body regions supplied by that nerve. The most common sites for disc herniation are the L4/L5 or L5/S1 intervertebral discs, which can cause sciatica, a widespread pain that radiates from the lower back down the thigh and into the leg. Similar injuries of the C5/C6 or C6/C7 intervertebral discs, following forcible hyperflexion of the neck from a collision accident or football injury, can produce pain in the neck, shoulder, and upper limb.

Herniated Intervertebral Disc

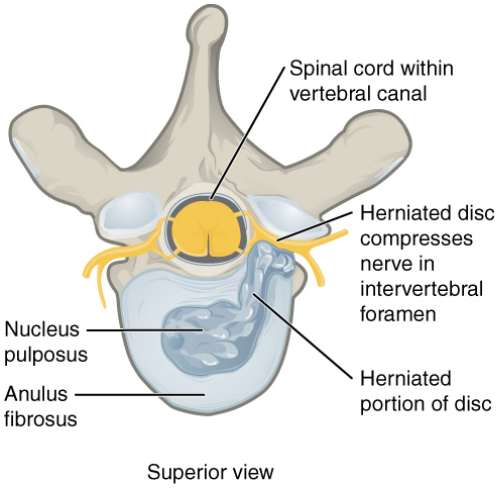

Weakening of the anulus fibrosus can result in herniation (protrusion) of the nucleus pulposus and compression of a spinal nerve, resulting in pain and/or muscle weakness in the body regions supplied by that nerve.

to

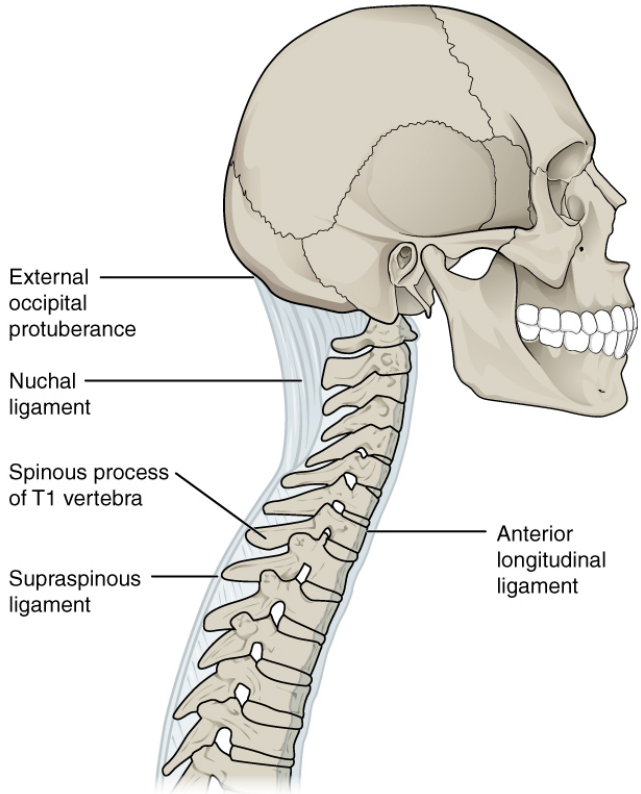

Ligaments of the Vertebral Column

Adjacent vertebrae are united by ligaments that run the length of the vertebral column along both its posterior and anterior aspects (Figure). These serve resist excess forward or backward bending movements of the vertebral column, respectively.

Ligaments of Vertebral Column

The anterior longitudinal ligament runs the length of the vertebral column, uniting the anterior sides of the vertebral bodies. The supraspinous ligament connects the spinous processes of the thoracic and lumbar vertebrae. In the posterior neck, the supraspinous ligament enlarges to form the nuchal ligament, which attaches to the cervical spinous processes and to the base of the skull.

CAREER CONNECTIONS...Chiropractor

Chiropractors are health professionals who use nonsurgical techniques to help patients with musculoskeletal system problems that involve the bones, muscles, ligaments, tendons, or nervous system. They treat problems such as neck pain, back pain, joint pain, or headaches. Chiropractors focus on the patient's overall health and can also provide counseling related to lifestyle issues, such as diet, exercise, or sleep problems. If needed, they will refer the patient to other medical specialists.

Chiropractors use a drug-free, hands-on approach for patient diagnosis and treatment. They will perform a physical exam, assess the patient's posture and spine, and may perform additional diagnostic tests, including taking X-ray images. They primarily use manual techniques, such as spinal manipulation, to adjust the patient's spine or other joints. They can recommend therapeutic or rehabilitative exercises, and some also include acupuncture, massage therapy, or ultrasound as part of the treatment program. In addition to those in general practice, some chiropractors specialize in sport injuries, neurology, orthopaedics, pediatrics, nutrition, internal disorders, or diagnostic imaging.

To become a chiropractor, students must have 3–4 years of undergraduate education, attend an accredited, four-year Doctor of Chiropractic (D.C.) degree program, and pass a licensure examination to be licensed for practice in their state. With the aging of the baby-boom generation, employment for chiropractors is expected to increase.

The Thoracic Cage

The thoracic cage (rib cage) forms the thorax (chest) portion of the body. It consists of the 12 pairs of ribs with their costal cartilages and the sternum (Figure). The ribs are anchored posteriorly to the 12 thoracic vertebrae (T1–T12). The thoracic cage protects the heart and lungs.

Thoracic Cage

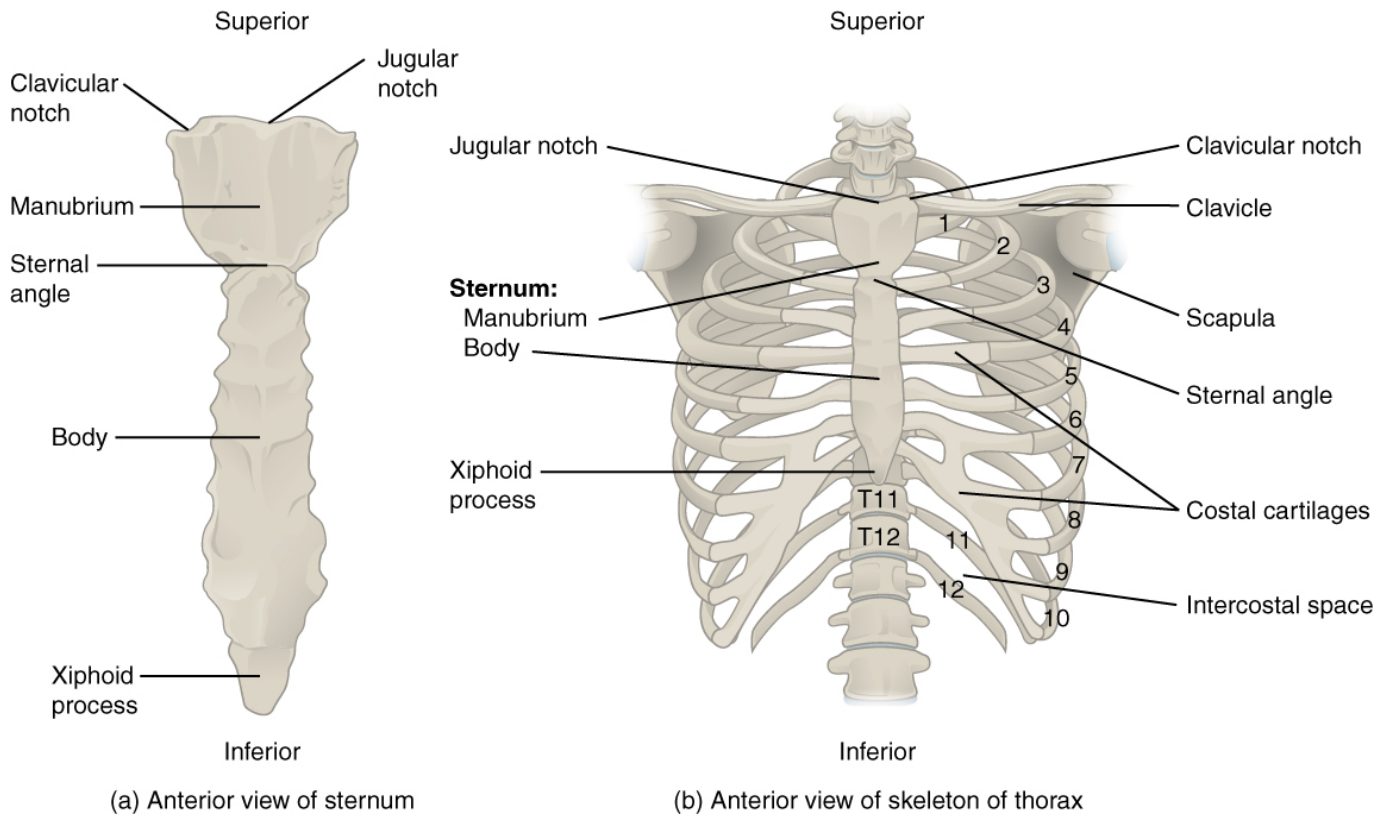

The thoracic cage is formed by the (a) sternum and (b) 12 pairs of ribs with their costal cartilages. The ribs are anchored posteriorly to the 12 thoracic vertebrae. The sternum consists of the manubrium, body, and xiphoid process. The ribs are classified as true ribs (1–7) and false ribs (8–12). The last two pairs of false ribs are also known as floating ribs (11–12).

Sternum

The sternum is the elongated bony structure that anchors the anterior thoracic cage. It consists of three parts: the **manubrium**, **body**, and **xiphoid process**. The manubrium is the wider, superior portion of the sternum. The top of the manubrium has a shallow, U-shaped border called the jugular (suprasternal) notch. This can be easily felt at the anterior base of the neck, between the medial ends of the clavicles. The clavicular notch is the shallow depression located on either side at the superior-lateral margins of the manubrium. This is the site of the sternoclavicular joint, between the sternum and clavicle. The first ribs also attach to the manubrium.

The elongated, central portion of the sternum is the body. The manubrium and body join together at the **sternal angle**, so called because the junction between these two components is not flat, but forms a slight bend. The second rib attaches to the sternum at the sternal angle. Since the first rib is hidden behind the clavicle, the second rib is the highest rib that can be identified by palpation. Thus, the sternal angle and second rib are important landmarks for the identification and counting of the lower ribs. Ribs 3–7 attach to the sternal body.

The inferior tip of the sternum is the xiphoid process. This small structure is cartilaginous early in life, but gradually becomes ossified starting during middle age.

Ribs

Each rib is a curved, flattened bone that contributes to the wall of the thorax. The ribs articulate posteriorly with the T1–T12 thoracic vertebrae, and most attach anteriorly via their costal cartilages to the sternum. There are 12 pairs of ribs. The ribs are numbered 1–12 in accordance with the **thoracic vertebrae**.

Parts of a Typical Rib

The posterior end of a typical rib is called the head of the rib (see [link]). This region articulates primarily with the costal facet located on the body of the same numbered thoracic vertebra and to a lesser degree, with the costal facet located on the body of the next higher vertebra. Lateral to the head is the narrowed neck of the rib. A small bump on the posterior rib surface is the tubercle of the rib, which articulates with the facet located on the transverse process of the same numbered vertebra. The remainder of the rib is the body of the rib (shaft).

Rib Classifications

- ❑ Ribs 1–7 are classified as true ribs (vertebrosternal ribs). The costal cartilage from each of these ribs attaches directly to the sternum.
- ❑ Ribs 8–12 are called false ribs (vertebrochondral ribs). The costal cartilages from these ribs do not attach directly to the sternum. For ribs 8–10, the costal cartilages are attached to the cartilage of the next higher rib. Thus, the cartilage of rib 10 attaches to the cartilage of rib 9, rib 9 then attaches to rib 8, and rib 8 is attached to rib 7.
- ❑ The last two false ribs (11–12) are also called floating ribs (vertebral ribs). These are short ribs that do not attach to the sternum at all. Instead, their small costal cartilages terminate within the musculature of the lateral abdominal wall.

The Appendicular Skeleton

The appendicular skeleton includes all of the limb bones, plus the bones that unite each limb with the axial skeleton (Figure).

The Pectoral Girdle

The bones that attach each upper limb to the axial skeleton form the pectoral girdle (shoulder girdle). This consists of two bones, the scapula and clavicle (Figure). The clavicle (collarbone) is an S-shaped bone located on the anterior side of the shoulder. It is attached on its medial end to the sternum of the thoracic cage, which is part of the axial skeleton. The lateral end of the clavicle articulates (joins) with the scapula just above the shoulder joint. You can easily palpate, or feel with your fingers, the entire length of your clavicle.

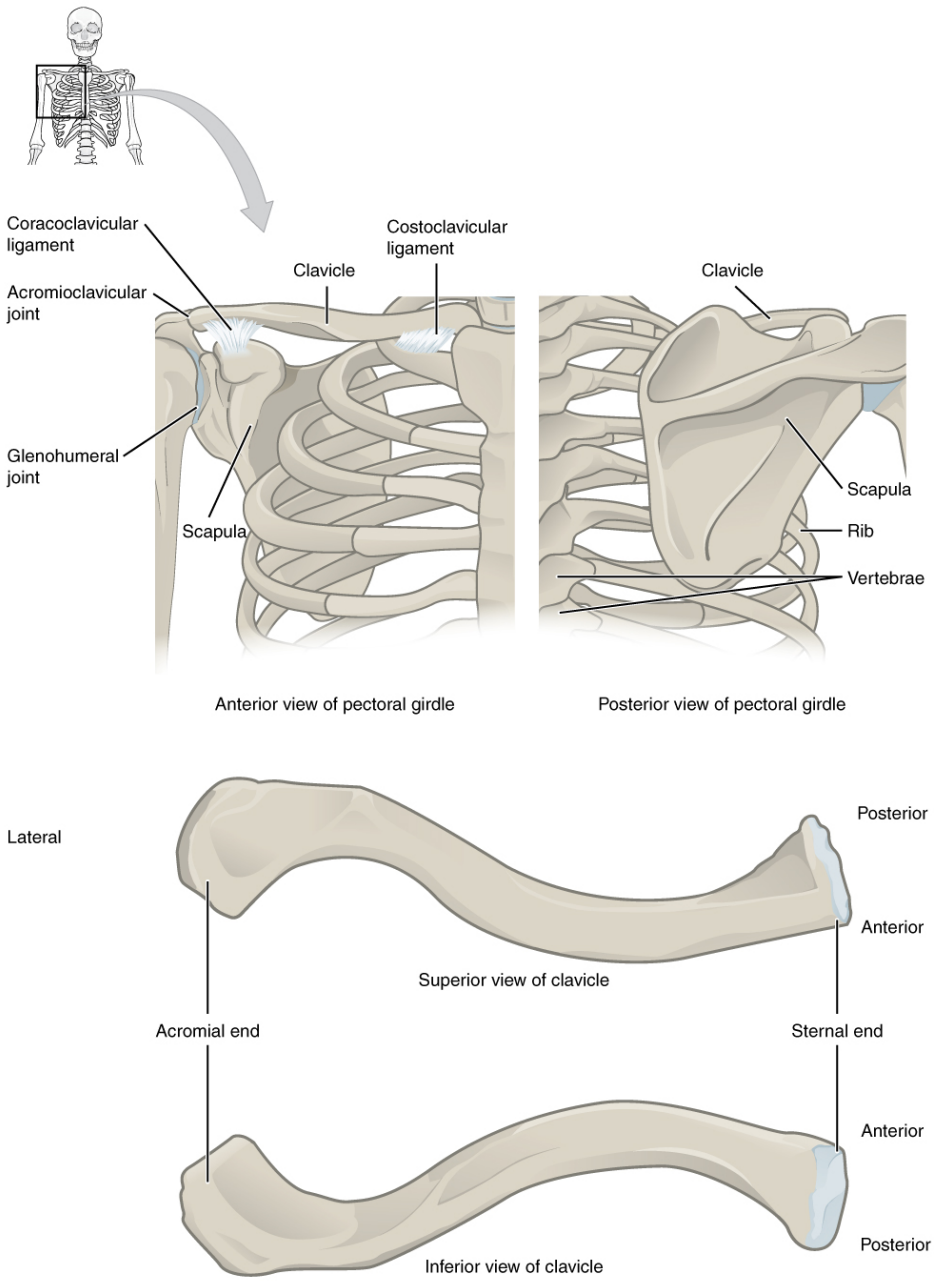

The **scapula** (shoulder blade) lies on the posterior aspect of the shoulder. It is supported by the clavicle, which also articulates with the humerus (arm bone) to form the shoulder joint. The scapula is a flat, triangular-shaped bone with a prominent ridge running across its posterior surface. This ridge extends out laterally, where it forms the bony tip of the shoulder and joins with the lateral end of the clavicle. By following along the clavicle, you can palpate out to the bony tip of the shoulder, and from there, you can move back across your posterior shoulder to follow the ridge of the scapula. Move your shoulder around and feel how the clavicle and scapula move

together as a unit. Both of these bones serve as important attachment sites for muscles that aid with movements of the shoulder and arm.

The right and left pectoral girdles are not joined to each other, allowing each to operate independently. In addition, the clavicle of each pectoral girdle is anchored to the axial skeleton by a single, highly mobile joint. This allows for the extensive mobility of the entire pectoral girdle, which in turn enhances movements of the shoulder and upper limb.

Clavicle

The clavicle is the only long bone that lies in a horizontal position in the body (see Figure). The clavicle has several important functions. First, anchored by muscles from above, it serves as a strut that extends laterally to support the scapula. This in turn holds the shoulder joint superiorly and laterally from the body trunk, allowing for maximal freedom of motion for the upper limb. The clavicle also transmits forces acting on the upper limb to the sternum and axial skeleton. Finally, it serves to protect the underlying nerves and blood vessels as they pass between the trunk of the body and the upper limb.

Clinical Connection.....Fractured Clavicle

The clavicle is the most commonly fractured bone in the body. Such breaks often occur because of the force exerted on the clavicle when a person falls onto his or her outstretched arms, or when the lateral shoulder receives a strong blow. Because the sternoclavicular joint is strong and rarely dislocated, excessive force results in the breaking of the clavicle, usually between the middle and lateral portions of the bone. If the fracture is complete, the shoulder and lateral clavicle fragment will drop due to the weight of the upper limb, causing the person to support the sagging limb with their other hand. Muscles acting across the shoulder will also pull the shoulder and lateral clavicle anteriorly and medially, causing the clavicle fragments to override. The clavicle overlies many important blood vessels and nerves for the upper limb, but fortunately, due to the anterior displacement of a broken clavicle, these structures are rarely affected when the clavicle is fractured.

Scapula

The scapula is also part of the pectoral girdle and thus plays an important role in anchoring the upper limb to the body. The scapula is located on the posterior side of the shoulder. It is surrounded by muscles on both its anterior (deep) and posterior (superficial) sides, and thus does not articulate with the ribs of the thoracic cage.

The suprascapular notch is located lateral to the midpoint of the superior border. The corners of the triangular scapula, at either end of the medial border, are the superior angle of the scapula, located between the medial and superior borders, and the inferior angle of the scapula, located between the medial and lateral borders. The inferior angle is the most inferior portion of the scapula, and is particularly important because it serves as the attachment point for several powerful muscles involved in shoulder and upper limb movements. The remaining corner of the scapula, between the superior and lateral borders, is the location of the glenoid cavity(glenoid fossa). This shallow depression articulates with the humerus bone of the arm to form the glenohumeral joint (shoulder

joint). The small bony bumps located immediately above and below the glenoid cavity are the supraglenoid tubercle and the infraglenoid tubercle, respectively. These provide attachments for muscles of the arm.

Scapula

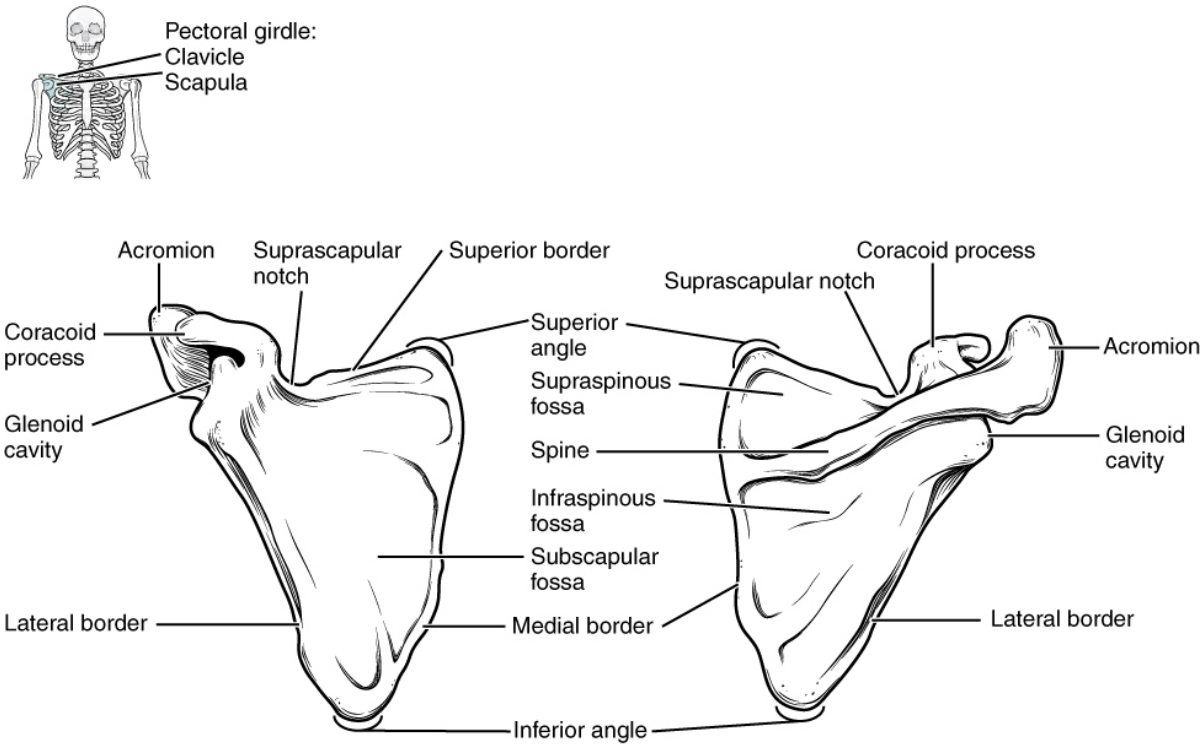

Right scapula, anterior aspect

Right scapula, posterior aspect

The scapula has two prominent projections.

- ❑ Toward the lateral end of the superior border, between the suprascapular notch and glenoid cavity, is the hook-like coracoid process (coracoid = “shaped like a crow’s beak”). This process projects anteriorly and curves laterally. At the shoulder, the coracoid process is located inferior to the lateral end of the clavicle. It is anchored to the clavicle by a strong ligament, and serves as the attachment site for muscles of the anterior chest and arm.
- ❑ On the posterior aspect, the spine of the scapula is a long and prominent ridge that runs across its upper portion. Together, the clavicle, acromion, and spine of the scapula form a V-shaped bony line that provides for the attachment of neck and back muscles that act on the shoulder, as well as muscles that pass across the shoulder joint to act on the arm.

Clinical connection...Shoulder Separation

Following a strong blow to the lateral shoulder, such as when a hockey player is driven into the boards, a complete dislocation of the acromioclavicular joint can result. In this case, the acromion is thrust under the acromial end of the clavicle, resulting in ruptures of both the acromioclavicular and coracoclavicular ligaments. The scapula then separates from the clavicle, with the weight of the upper limb pulling the shoulder downward. This dislocation injury of the acromioclavicular joint is known as a “shoulder separation” and is common in contact sports such as hockey, football, or martial arts.

Bones of the Upper Extremities (Arms and Hands)

Humerus

The humerus is the single bone of the upper arm region. At its proximal end is the head of the humerus. This is the large, round, smooth region that faces medially. The head articulates with the glenoid cavity of the scapula to form the glenohumeral (shoulder) joint. The margin of the smooth area of the head is the anatomical neck of the humerus. The surgical neck is a common site of arm fractures. The deltoid tuberosity is a roughened, V-shaped region located on the lateral side in the middle of the humerus shaft. As its name indicates, it is the site of attachment for the deltoid muscle.

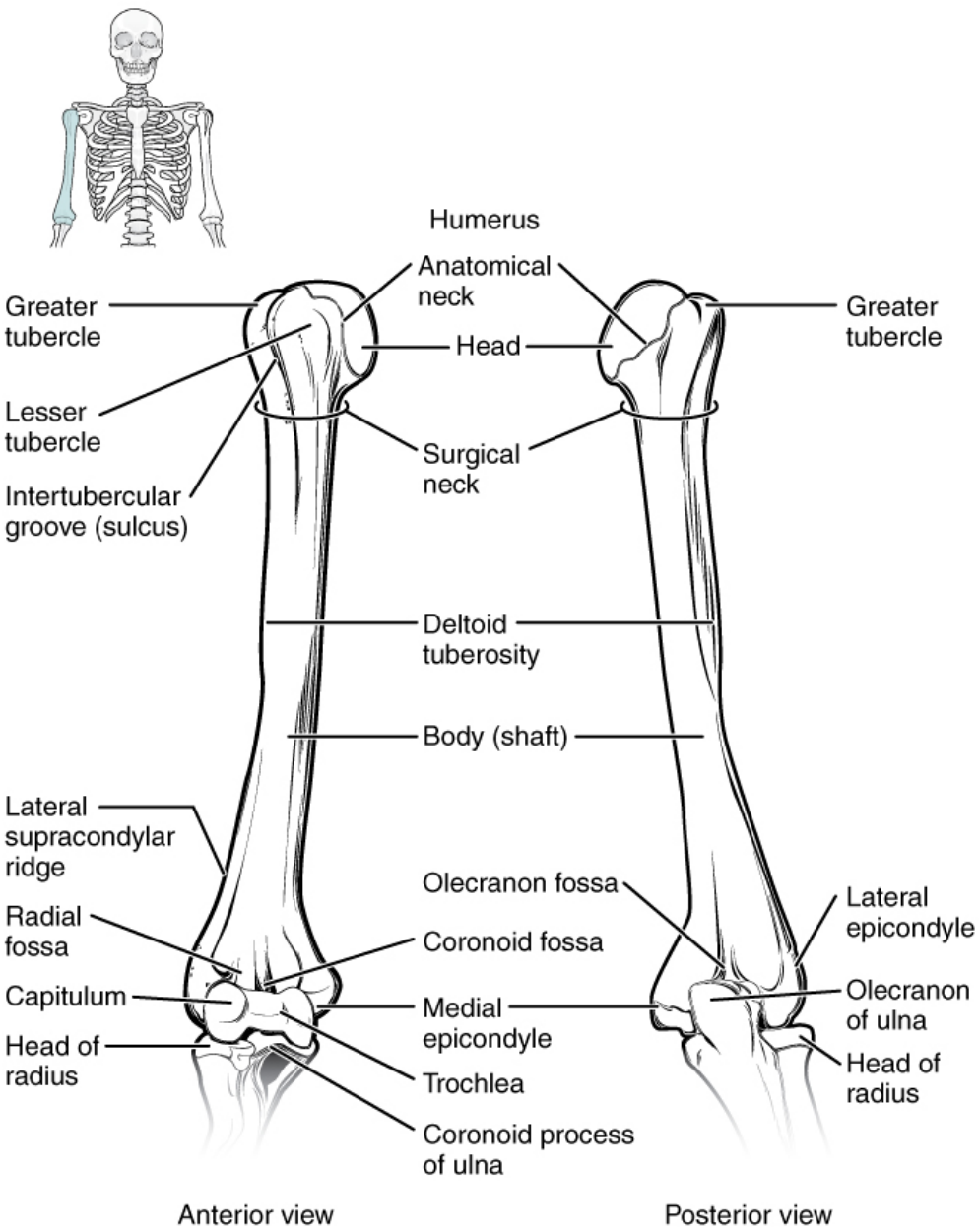

Ulna

The ulna is the medial bone of the forearm. It runs parallel to the radius, which is the lateral bone of the forearm (Figure). The proximal end of the ulna resembles a crescent wrench with its large, C-shaped trochlear notch. This region articulates with the trochlea of the humerus as part of the elbow joint. The inferior margin of the trochlear notch is formed by a prominent lip of bone called the coronoid process of the ulna. Just below this on the anterior ulna is a roughened area called the ulnar tuberosity. To the lateral

side and slightly inferior to the trochlear notch is a small, smooth area called the radial notch of the ulna. This area is the site of articulation between the proximal radius and the ulna, forming the proximal radioulnar joint. The posterior and superior portions of the proximal ulna make up the olecranon process, which forms the bony tip of the elbow.

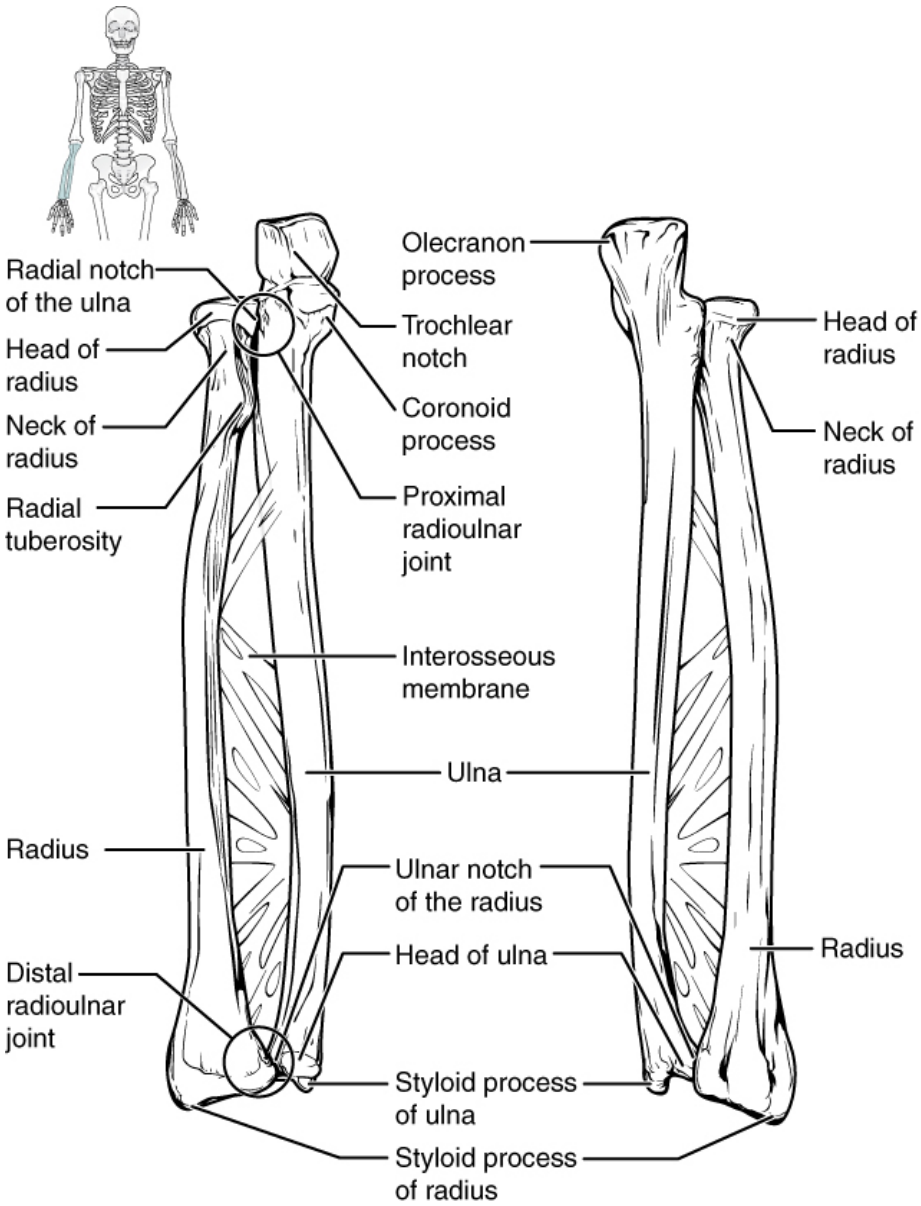

Ulna and Radius

The ulna is located on the medial side of the forearm, and the radius is on the lateral side. These bones are attached to each other by an interosseous membrane. More distal is the shaft of the ulna. The lateral side of the shaft forms a ridge called the interosseous border of the ulna. This is the line of attachment for the interosseous membrane of the forearm, a sheet of dense connective tissue that unites the ulna and radius bones. The small, rounded area that forms the distal end is the head of the ulna. Projecting from the posterior side of the ulnar head is the styloid process of the ulna, a short bony projection. This serves as an attachment point for a connective tissue structure that unites the distal ends of the radius

The **radius** runs parallel to the ulna, on the lateral (thumb) side of the forearm. The head of the radius is a disc-shaped structure that forms the proximal end. The small depression on the surface of the head articulates with the capitulum of the humerus as part of the elbow joint, whereas the smooth, outer margin of the head articulates with the radial notch of the ulna at the proximal radioulnar joint.

The lateral end of the radius has a pointed projection called the styloid process of the radius. This provides attachment for ligaments that support the lateral side of the wrist joint. Compared to the styloid process of the ulna, the styloid process of the radius projects more distally, thereby limiting the range of movement for lateral deviations of the hand at the wrist joint.

Carpal Bones

The wrist and base of the hand are formed by a series of eight small carpal bones (see Figure). The carpal bones are arranged in two rows, forming a proximal row of four carpal bones and a distal row of four carpal bones. The bones in the proximal row, running from the lateral (thumb) side to the medial side, are the scaphoid ("boat-shaped"), lunate ("moon-shaped"), triquetrum ("three-cornered"), and pisiform ("pea-shaped") bones. The small, rounded pisiform bone articulates with the anterior surface of the triquetrum bone. The pisiform thus projects anteriorly, where it forms the bony bump that can be felt at the medial base of your hand. The distal bones (lateral to medial) are the trapezium ("table"), trapezoid ("resembles a table"), capitate ("head-shaped"), and hamate ("hooked bone") bones. The hamate bone is characterized by a prominent bony extension on its anterior side called the hook of the hamate bone.

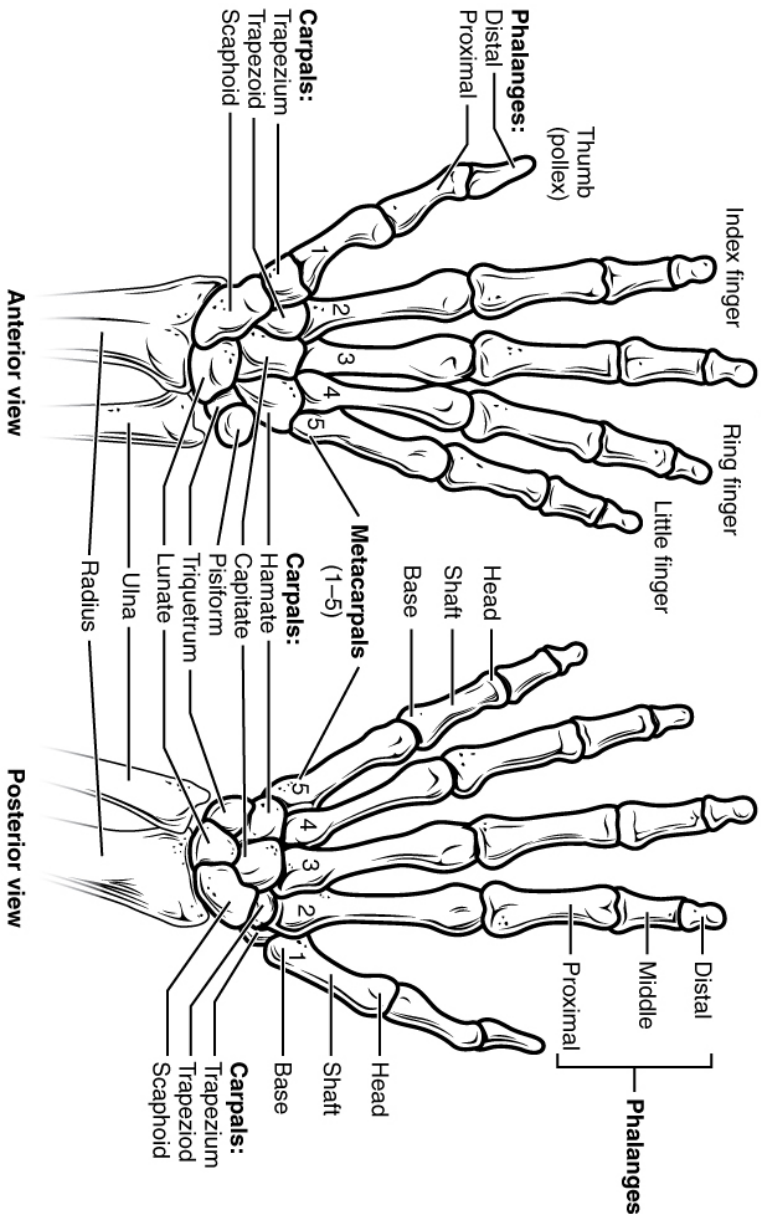

The eight carpal bones form the base of the hand. These are arranged into proximal and distal rows of four bones each. The metacarpal bones form the palm of the hand. The thumb and fingers consist of the phalanx bones.

The carpal bones form the base of the hand. This can be seen in the radiograph (X-ray image) of the hand that shows the relationships of the hand bones to the skin creases of the hand (see Figure). Within the carpal bones, the four proximal bones are united to each other by ligaments to form a unit. Only three of these bones, the scaphoid, lunate, and triquetrum, contribute to the radiocarpal joint. The scaphoid and lunate bones articulate directly with the distal end of the radius, whereas the triquetrum bone articulates with a fibrocartilaginous pad that spans the radius and styloid process of the ulna. The distal end of the ulna thus does not directly articulate with any of the carpal bones.

The four distal carpal bones are also held together as a group by ligaments. The proximal and distal rows of carpal bones articulate with each other to form the midcarpal joint Together, the radiocarpal and midcarpal joints are responsible for all movements of the hand at the wrist. The distal carpal bones also articulate with the metacarpal bones of the hand.

Bones of the Hand

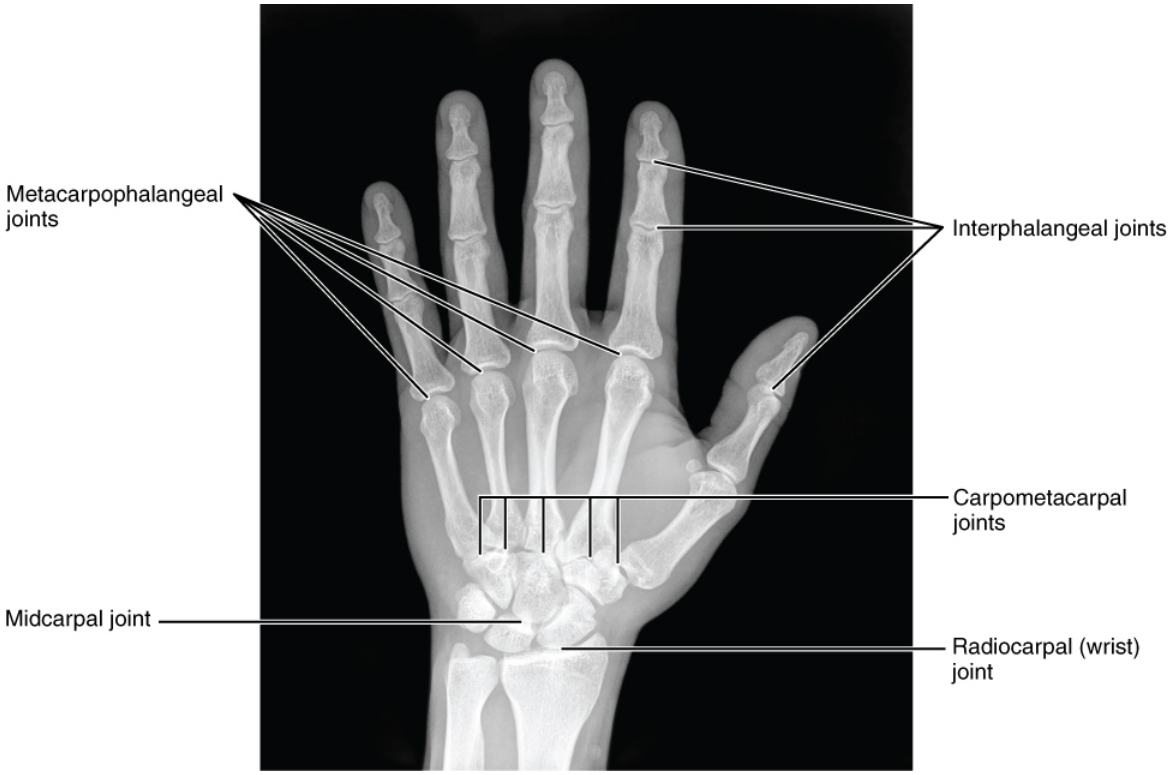

This radiograph shows the position of the bones within the hand. Note the carpal bones that form the base of the hand. (credit: modification of work by Trace Meek)

In the articulated hand, the carpal bones form a U-shaped grouping. A strong ligament called the flexor retinaculum spans the top of this U-shaped area to maintain this grouping of the carpal bones. The flexor retinaculum is attached laterally to the trapezium and scaphoid bones, and medially to the hamate and pisiform bones. Together, the carpal bones and the flexor retinaculum form a passageway called the carpal tunnel, with the carpal bones forming the walls and floor, and the flexor retinaculum forming the roof of this space (Figure).

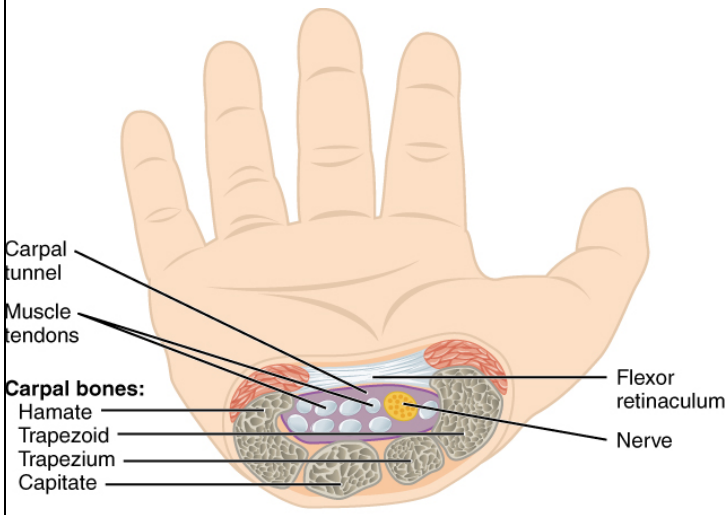

Clinical Connection...Carpal Tunnel Syndrome

The tendons of nine muscles of the anterior forearm and an important nerve pass through the carpal tunnel to enter the hand. Overuse of the muscle tendons or wrist injury can produce inflammation and swelling within this space. This produces compression of the nerve, resulting in carpal tunnel syndrome, which is characterized by pain or numbness, and muscle weakness in those areas of the hand supplied by this nerve.

Metacarpal Bones

The palm of the hand contains five elongated metacarpal bones. These bones lie between the carpal bones of the wrist and the bones of the fingers and thumb (see Figure). The proximal end of each metacarpal bone articulates with one of the distal carpal bones.

Phalanx Bones

The fingers and thumb contain 14 bones, each of which is called a phalanx bone (plural = phalanges), named after the ancient Greek phalanx (a rectangular block of soldiers). The thumb (pollex) is digit number 1 and has two phalanges, a proximal phalanx, and a distal phalanx bone (see Figure). Digits 2 (index finger) through 5 (little finger) have three phalanges each, called the proximal, middle, and distal phalanx bones.

DISORDERS OF THE…Appendicular System: Fractures of Upper Limb Bones

Due to our constant use of the hands and the rest of our upper limbs, an injury to any of these areas will cause a significant loss of functional ability. Many fractures result from a hard fall onto an outstretched hand. The resulting transmission of force up the limb may result in a fracture of the humerus, radius, or scaphoid bones. These injuries are especially common in elderly people whose bones are weakened due to osteoporosis.

Falls onto the hand or elbow, or direct blows to the arm, can result in fractures of the humerus (Figure). Following a fall, fractures at the surgical neck, the region at which the expanded proximal end of the humerus joins with the shaft, can result in an impacted fracture, in which the distal portion of the humerus is driven into the proximal portion. Falls or blows to the arm can also produce transverse or spiral fractures of the humeral shaft.

In children, a fall onto the tip of the elbow frequently results in a distal humerus fracture. In these, the olecranon of the ulna is driven upward, resulting in a fracture across the distal humerus, above both epicondyles (supracondylar fracture), or a fracture between the epicondyles, thus separating one or both of the epicondyles from the body of the humerus (intercondylar fracture). With these injuries, the immediate concern is possible compression of the artery to the forearm due to swelling of the surrounding tissues. If compression occurs, the resulting ischemia (lack of oxygen) due to reduced blood flow can quickly produce irreparable damage to the forearm muscles. In addition, four major nerves for shoulder and upper limb muscles are closely associated with different regions of the humerus, and thus, humeral fractures may also damage these nerves.

Another frequent injury following a fall onto an outstretched hand is a Colles fracture (“col-lees”) of the distal radius (see Figure). This involves a complete transverse fracture across the distal radius that drives the separated distal fragment of the radius posteriorly and superiorly. This injury results in a characteristic “dinner fork” bend of the forearm just above the wrist due to the posterior displacement of the hand. This is the most frequent forearm fracture and is a common injury in persons over the age of 50, particularly in older women with osteoporosis. It also commonly occurs following a high-speed fall onto the hand during activities such as snowboarding or skating.

The most commonly fractured carpal bone is the scaphoid, often resulting from a fall onto the hand. Deep pain at the lateral wrist may yield an initial diagnosis of a wrist sprain, but a radiograph taken

several weeks after the injury, after tissue swelling has subsided, will reveal the fracture. Due to the poor blood supply to the scaphoid bone, healing will be slow and there is the danger of bone necrosis and subsequent degenerative joint disease of the wrist.

Fractures of the Humerus and Radius

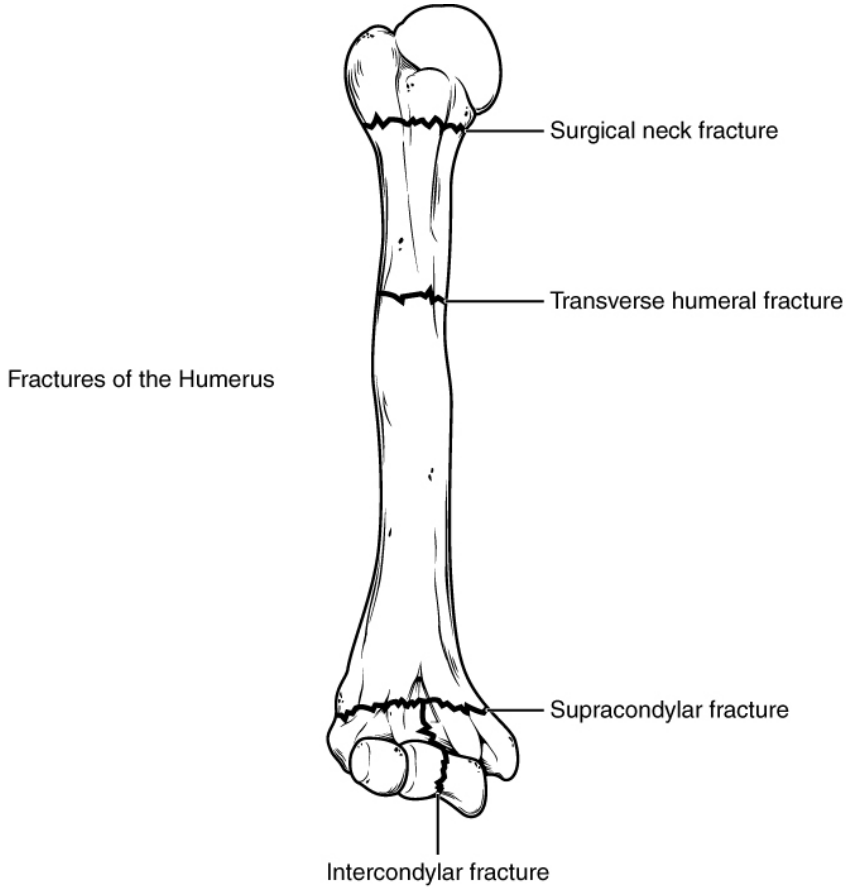

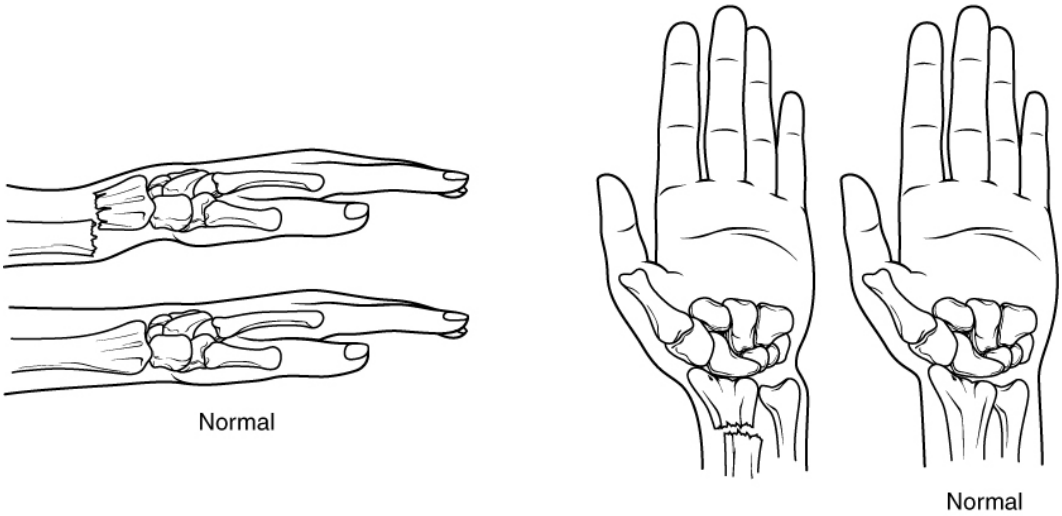

Colles Fracture of the Distal Radius

Falls or direct blows can result in fractures of the surgical neck or shaft of the humerus. Falls onto the elbow can fracture the distal humerus. A Colles fracture of the distal radius is the most common forearm fracture.

The Pelvic Girdle and Pelvis

The pelvic girdle (hip girdle) is formed by a single bone, the hip bone or coxal bone (coxal = "hip"), which serves as the attachment point for each lower limb. Each hip bone, in turn, is firmly joined to the axial skeleton via its attachment to the sacrum of the vertebral column. The right and left hip bones also converge anteriorly to attach to each other. The bony pelvis is the entire structure formed by the two hip bones, the sacrum, and, attached inferiorly to the sacrum, the coccyx (Figure).

Unlike the bones of the pectoral girdle, which are highly mobile to enhance the range of upper limb movements, the bones of the pelvis are strongly united to each other to form a largely immobile, weight-bearing structure. This is important for stability because it enables the weight of the body to be easily transferred laterally from the vertebral column, through the pelvic girdle and hip joints, and into either lower limb whenever the other limb is not bearing weight. Thus, the immobility of the pelvis provides a strong foundation for the upper body as it rests on top of the mobile lower limbs.

Pelvis



The pelvic girdle is formed by a single hip bone. The hip bone attaches the lower limb to the axial skeleton through its articulation with the sacrum. The right and left hip bones, plus the sacrum and the coccyx, together form the pelvis.

Hip Bone

The hip bone, or coxal bone, forms the pelvic girdle portion of the pelvis. The paired hip bones are the large, curved bones that form the lateral and anterior aspects of the pelvis. Each adult hip bone is formed by three separate bones that fuse together during the late teenage years. These bony components are the ilium, ischium, and pubis (Figure). These names are retained and used to define the three regions of the adult hip bone.

The Hip Bone

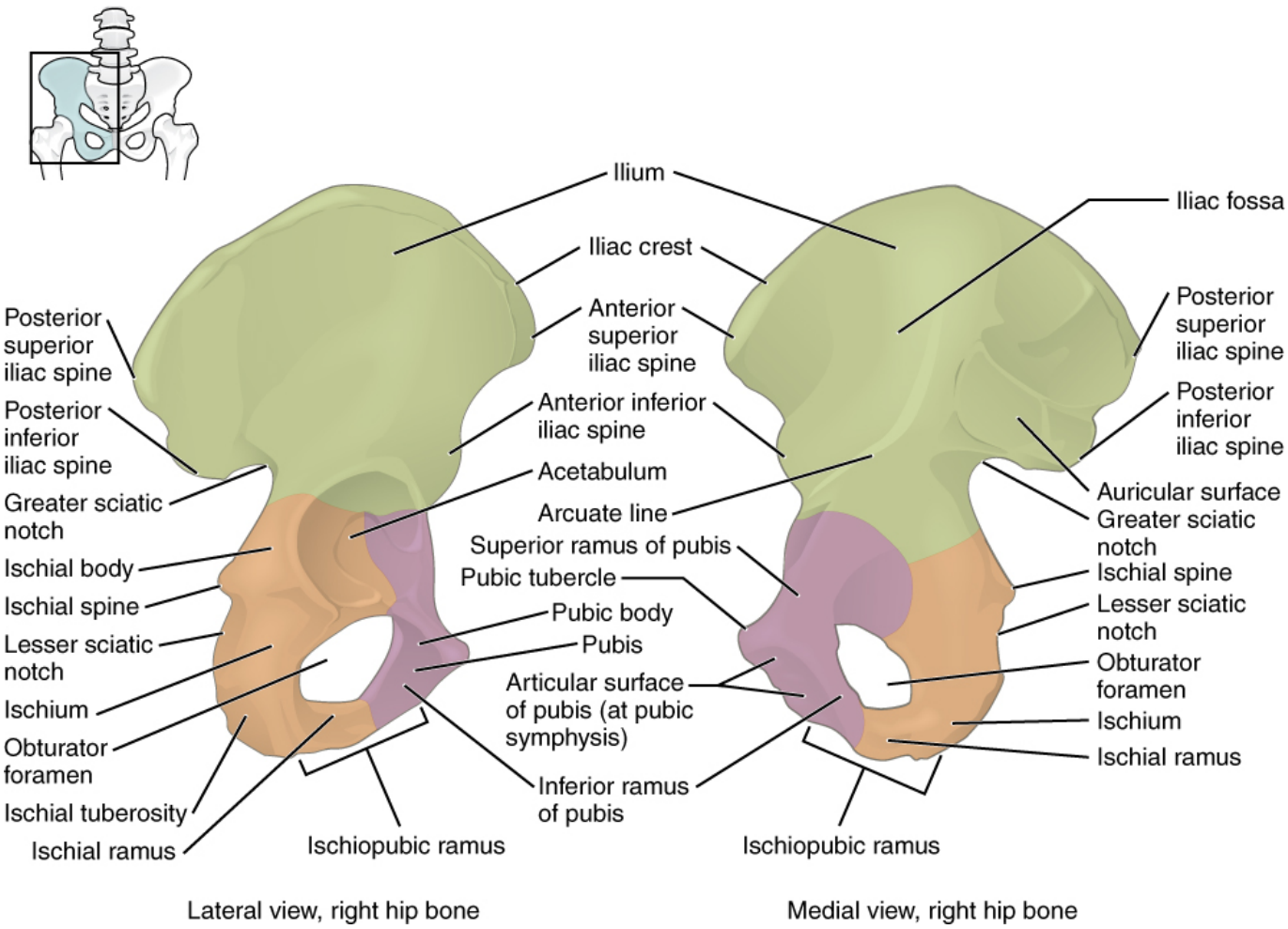

The adult hip bone consists of three regions. The ilium forms the large, fan-shaped superior portion, the ischium forms the posteroinferior portion, and the pubis forms the anteromedial portion.

- **Ilium**: the curved, superior margin of the ilium is the iliac crest. The rounded, anterior termination of the iliac crest is the anterior superior iliac spine. This important bony landmark can be felt at your anterolateral hip. Inferior to the anterior superior iliac spine is a rounded protuberance called the anterior inferior iliac spine. Both of these iliac spines serve as attachment points for muscles of the thigh.
- **Ischium**: The ischium forms the posterolateral portion of the hip bone (see Figure). The large, roughened area of the inferior ischium is the ischial tuberosity. This serves as the attachment for the posterior thigh muscles and also carries the weight of the body when sitting.

- **Pubis**: The pubis forms the anterior portion of the hip bone (see Figure). The enlarged medial portion of the pubis is the pubic body. Located superiorly on the pubic body is a small bump called the pubic tubercle. The superior pubic ramus is the segment of bone that passes laterally from the pubic body to join the ilium.

Pelvis

The pelvis consists of four bones: the right and left hip bones, the sacrum, and the coccyx (see Figure). The pelvis has several important functions.

- Its primary role is to support the weight of the upper body when sitting and to transfer this weight to the lower limbs when standing.
- It serves as an attachment point for trunk and lower limb muscles, and
- protects the internal pelvic organs.
- The three areas of each hip bone, the ilium, pubis, and ischium, converge centrally to form a deep, cup-shaped cavity called the acetabulum. This is located on the lateral side of the hip bone and is part of the hip joint.

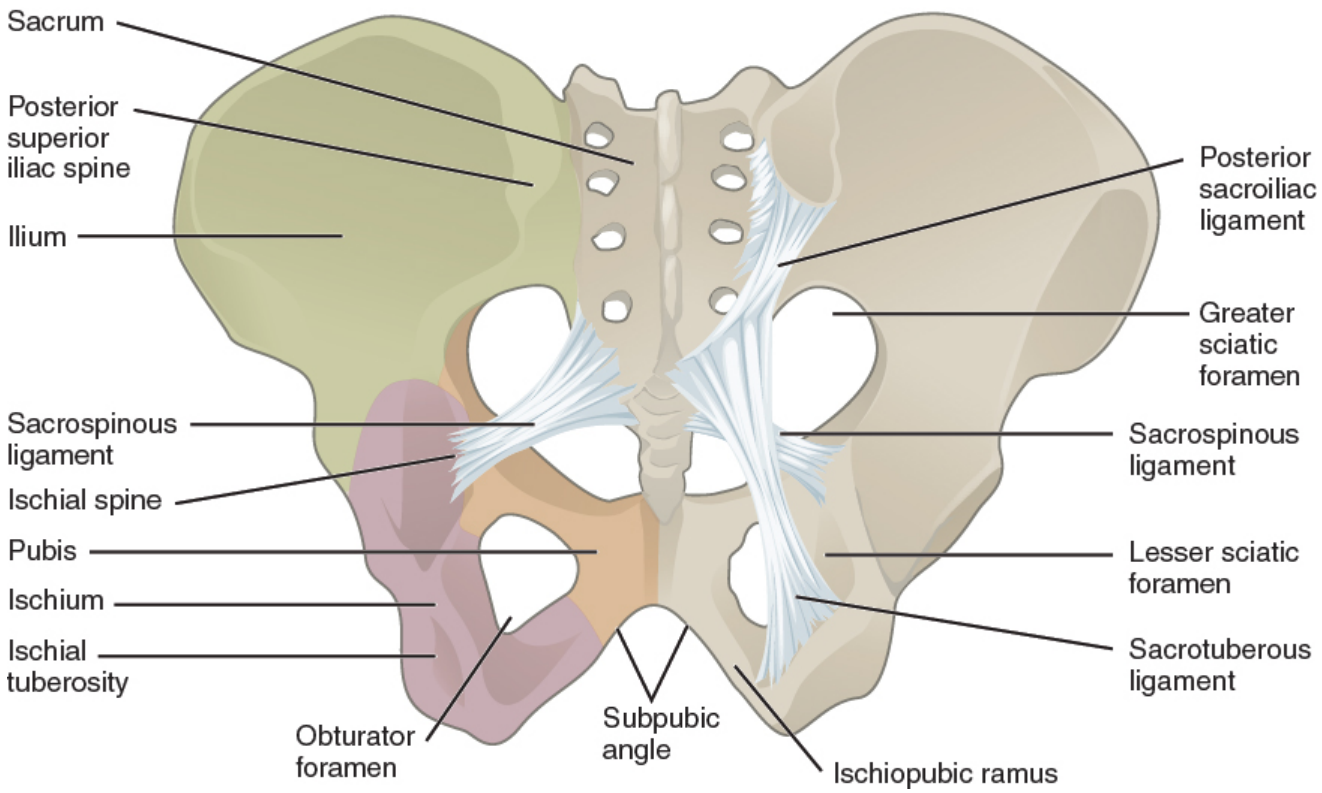

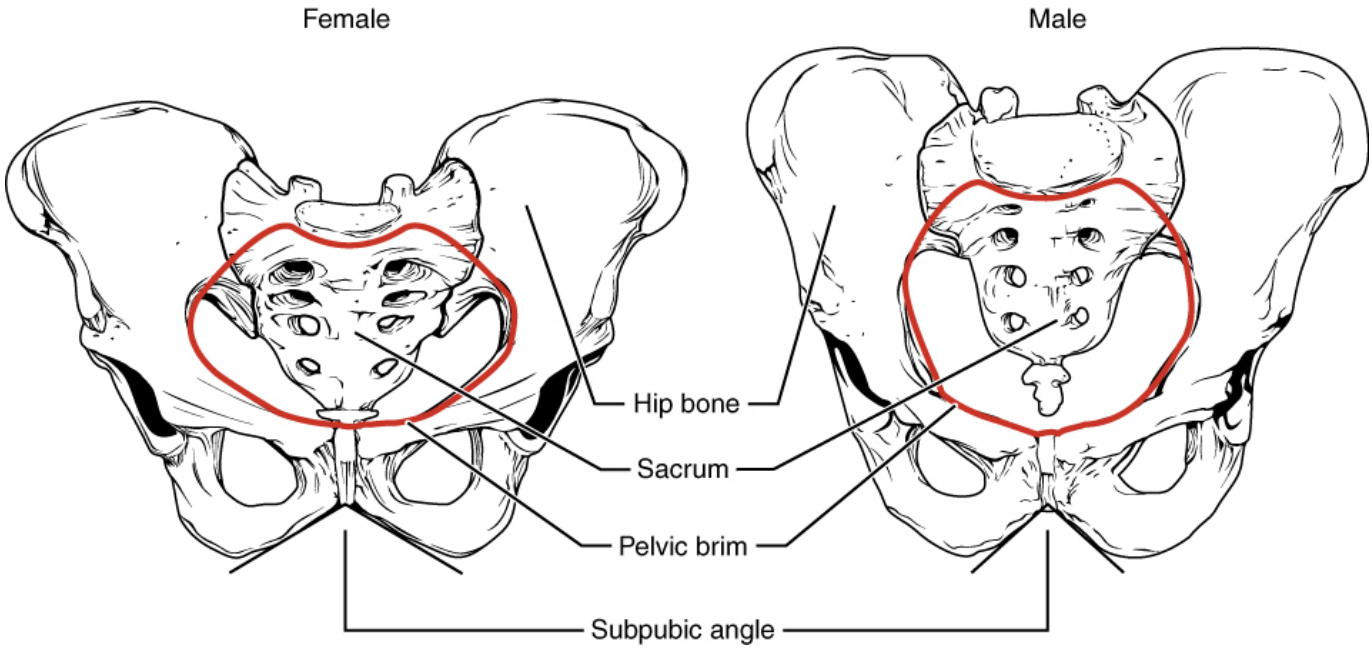

The female pelvis is adapted for childbirth and is broader, with a larger subpubic angle, a rounder pelvic brim, and a wider and more shallow lesser pelvic cavity than the male pelvis.

Comparison of the Female and Male Pelvis

The differences between the adult female and male pelvis relate to function and body size. In general, the bones of the male pelvis are thicker and heavier, adapted for support of the male's heavier physical build and stronger muscles. The greater sciatic notch of the male hip bone is narrower and deeper than the broader notch of females. Because the female pelvis is adapted for childbirth, it is wider than the male pelvis, as evidenced by the distance between the anterior superior iliac spines (see Figure). The ischial tuberosities of females are also farther apart, which increases the size of the pelvic outlet. Because of this increased pelvic width, the subpubic angle is larger in females (greater than 80 degrees) than it is in males (less than 70 degrees). The female sacrum is wider, shorter, and less curved, and the sacral promontory projects less into the pelvic cavity, thus giving the female pelvic inlet (pelvic brim) a more rounded or oval shape compared to males. The lesser pelvic cavity of females is also wider and more shallow than the narrower, deeper, and tapering lesser pelvis of males. Because of the obvious differences between female and male hip bones, this is the one bone of the body that allows for the most accurate sex determination.

CAREER CONNECTION...Forensic Pathology and Forensic Anthropology

A forensic pathologist (also known as a medical examiner) is a medically trained physician who has been specifically trained in pathology to examine the bodies of the deceased to determine the cause of death. A forensic pathologist applies his or her understanding of disease as well as toxins, blood and DNA analysis, firearms and ballistics, and other factors to assess the cause and manner of death. At times, a forensic pathologist will be called to testify under oath in situations that involve

a possible crime. Forensic pathology is a field that has received much media attention on television shows or following a high-profile death.

While forensic pathologists are responsible for determining whether the cause of someone's death was natural, a suicide, accidental, or a homicide, there are times when uncovering the cause of death is more complex, and other skills are needed. Forensic anthropology brings the tools and knowledge of physical anthropology and human osteology (the study of the skeleton) to the task of investigating a death. A forensic anthropologist assists medical and legal professionals in identifying human remains. The science behind forensic anthropology involves the study of archaeological excavation; the examination of hair; an understanding of plants, insects, and footprints; the ability to determine how much time has elapsed since the person died; the analysis of past medical history and toxicology; the ability to determine whether there are any postmortem injuries or alterations of the skeleton; and the identification of the decedent (deceased person) using skeletal and dental evidence.

Due to the extensive knowledge and understanding of excavation techniques, a forensic anthropologist is an integral and invaluable team member to have on-site when investigating a crime scene, especially when the recovery of human skeletal remains is involved. When remains are bought to a forensic anthropologist for examination, he or she must first determine whether the remains are in fact human. Once the remains have been identified as belonging to a person and not to an animal, the next step is to approximate the individual's age, sex, race, and height. The forensic anthropologist does not determine the cause of death, but rather provides information to the forensic pathologist, who will use all of the data collected to make a final determination regarding the cause of death.

Bones of the Lower Limb

Like the upper limb, the lower limb is divided into three regions. The thigh is that portion of the lower limb located between the hip joint and knee joint. The leg is specifically the region between the knee joint and the ankle joint. Distal to the ankle is the foot. The lower limb contains 30 bones. These are the femur, patella, tibia, fibula, tarsal bones, metatarsal bones, and phalanges (see [link]). The femur is the single bone of the thigh. The patella is the kneecap and articulates with the distal femur. The tibia is the larger, weight-bearing bone located on the medial side of the leg, and the fibula is the thin bone of the lateral leg. The bones of the foot are divided into three groups. The posterior portion of the foot is formed by a group of seven bones, each of which is known as a tarsal bone, whereas the mid-foot contains five elongated bones, each of which is a metatarsal bone. The toes contain 14 small bones, each of which is a phalanx bone of the foot.

Femur

The femur is the single bone of the thigh region. It articulates superiorly with the hip bone at the hip joint, and inferiorly with the tibia at the knee joint. The patella only articulates with the distal end of the femur.

The narrowed region below the head is the neck of the femur. This is a common area for fractures of the femur. The greater trochanter is the large, upward, bony projection located above the base of the neck. Multiple muscles that act across the hip joint attach to the greater trochanter, which, because of its projection from the femur, gives additional leverage to these muscles. The greater trochanter can be felt just under the skin on the lateral side of your upper thigh. The lesser trochanter is a small, bony prominence that lies on the medial aspect of the femur, just below the neck. A single, powerful muscle attaches to the lesser trochanter. Running between the greater and lesser trochanters on the anterior side of the femur is the roughened intertrochanteric line. The trochanters are also connected on the posterior side of the femur by the larger intertrochanteric crest.

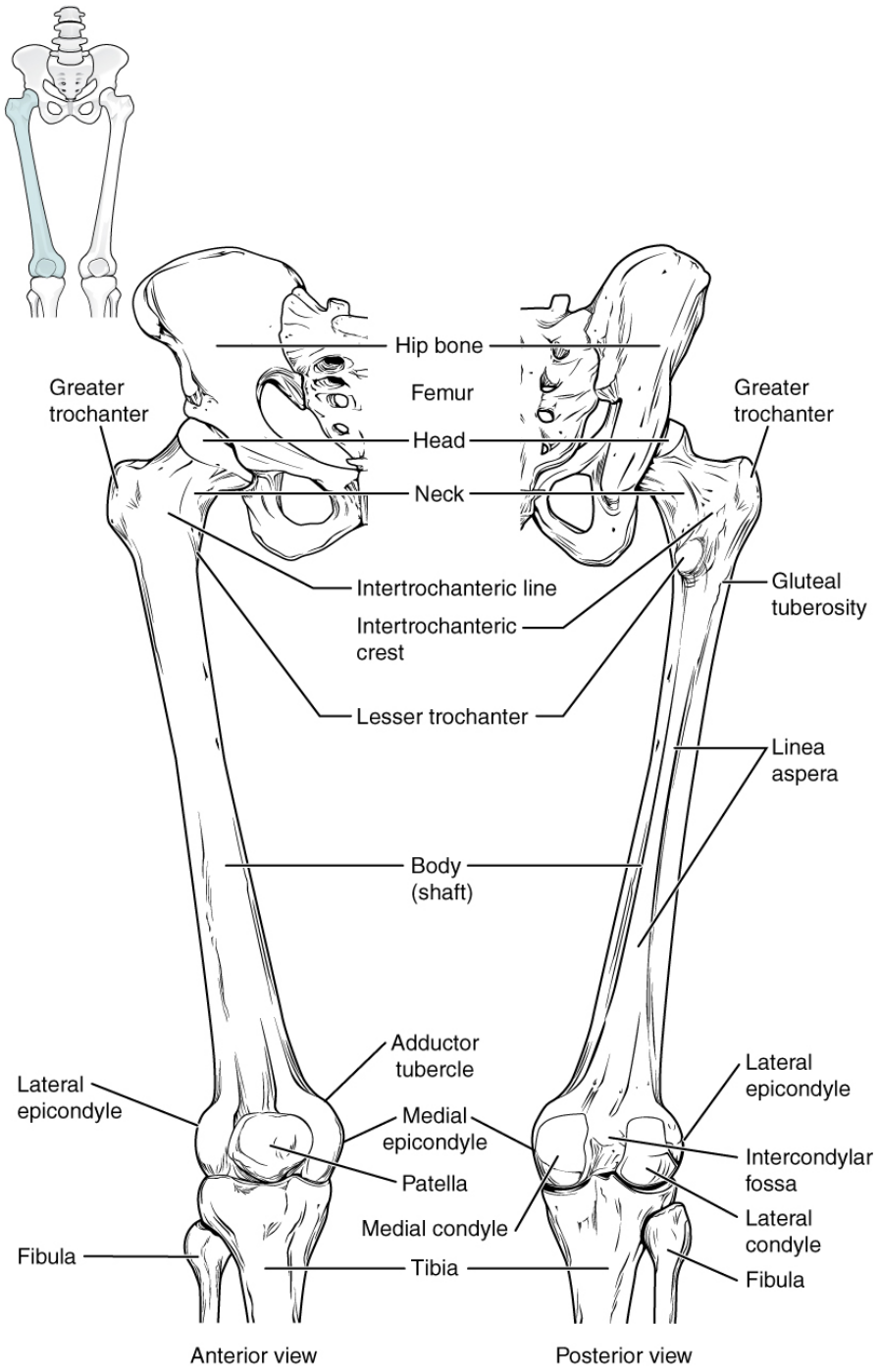

Patella

The patella (kneecap) is largest sesamoid bone of the body (see Figure). A sesamoid bone is a bone that is incorporated into the tendon of a muscle where that tendon crosses a joint. The sesamoid bone articulates with the underlying bones to prevent damage to the muscle tendon due to rubbing against the bones during movements of the joint. The patella is found in the tendon of the quadriceps femoris muscle, the large muscle of the anterior thigh that passes across the anterior knee to attach to the tibia. The patella articulates with the patellar surface of the femur and thus prevents rubbing of the muscle tendon against the distal femur. The patella also lifts the tendon away from the knee joint, which increases the leverage power of the quadriceps femoris muscle as it acts across the knee. The patella does not articulate with the tibia.

Tibia

The tibia (shin bone) is the medial bone of the leg and is larger than the fibula, with which it is paired (Figure). The tibia is the main weight-bearing bone of the lower leg and the second longest bone of the body, after the femur. The medial side of the tibia is located immediately under the skin, allowing it to be easily palpated down the entire length of the medial leg.

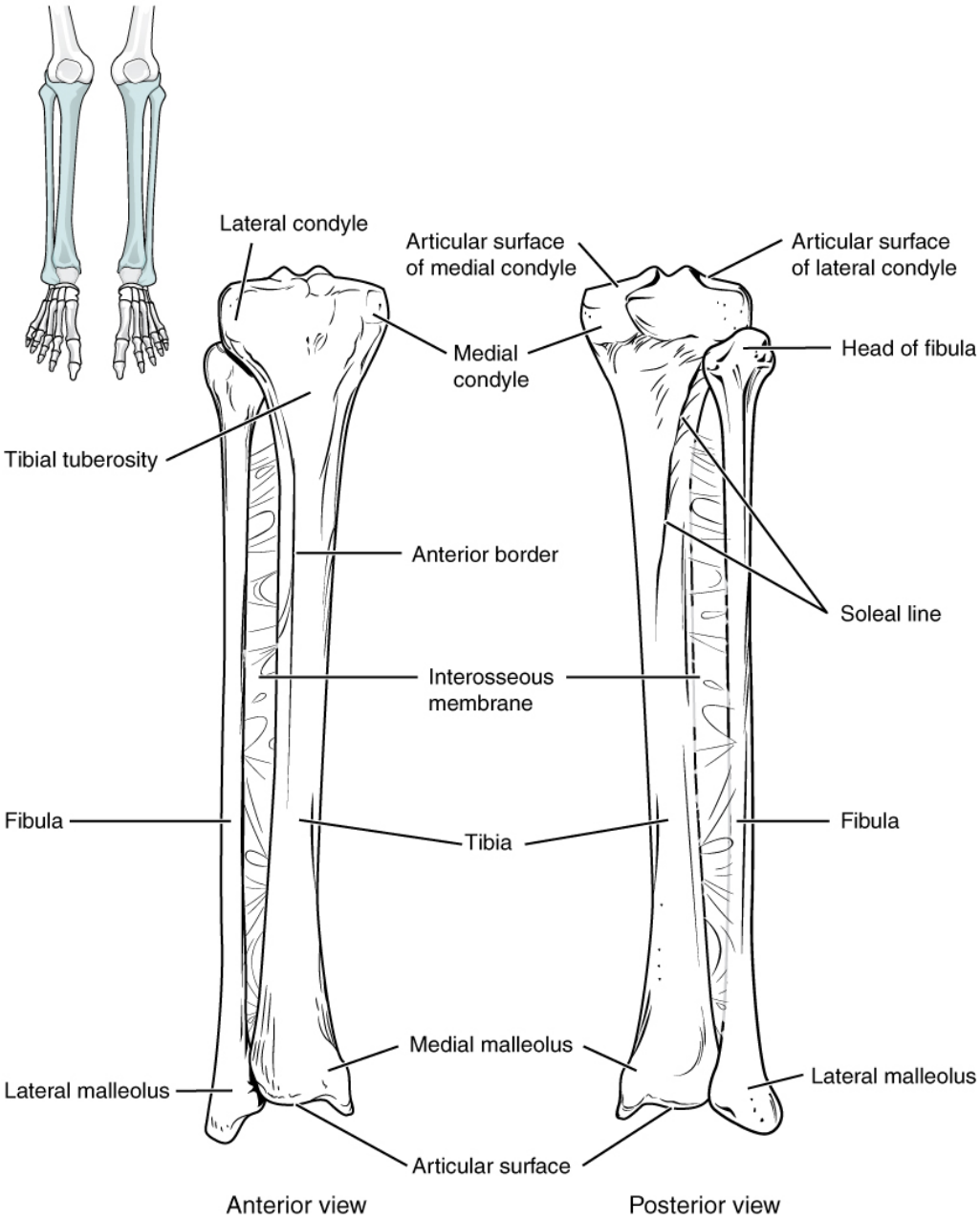

Fibula

The fibula is the slender bone located on the lateral side of the leg (see Figure). The fibula does not bear weight. It serves primarily for muscle

attachments and thus is largely surrounded by muscles. Only the proximal and distal ends of the fibula can be palpated.

Tarsal Bones

The posterior half of the foot is formed by seven tarsal bones (Figure). The most superior bone is the talus. This has a relatively square-shaped, upper surface that articulates with the tibia and fibula to form the ankle joint. Three areas of articulation form the ankle joint: The superomedial surface of the talus bone articulates with the medial malleolus of the tibia, the top of the talus articulates with the distal end of the tibia, and the lateral side of the talus articulates with the lateral malleolus of the fibula. Inferiorly, the talus articulates with the calcaneus (heel bone), the largest bone of the foot, which forms the heel. Body weight is transferred from the tibia to the talus to the calcaneus, which rests on the ground. The medial calcaneus has a prominent bony extension called the sustentaculum tali ("support for the talus") that supports the medial side of the talus bone.

Bones of the Foot

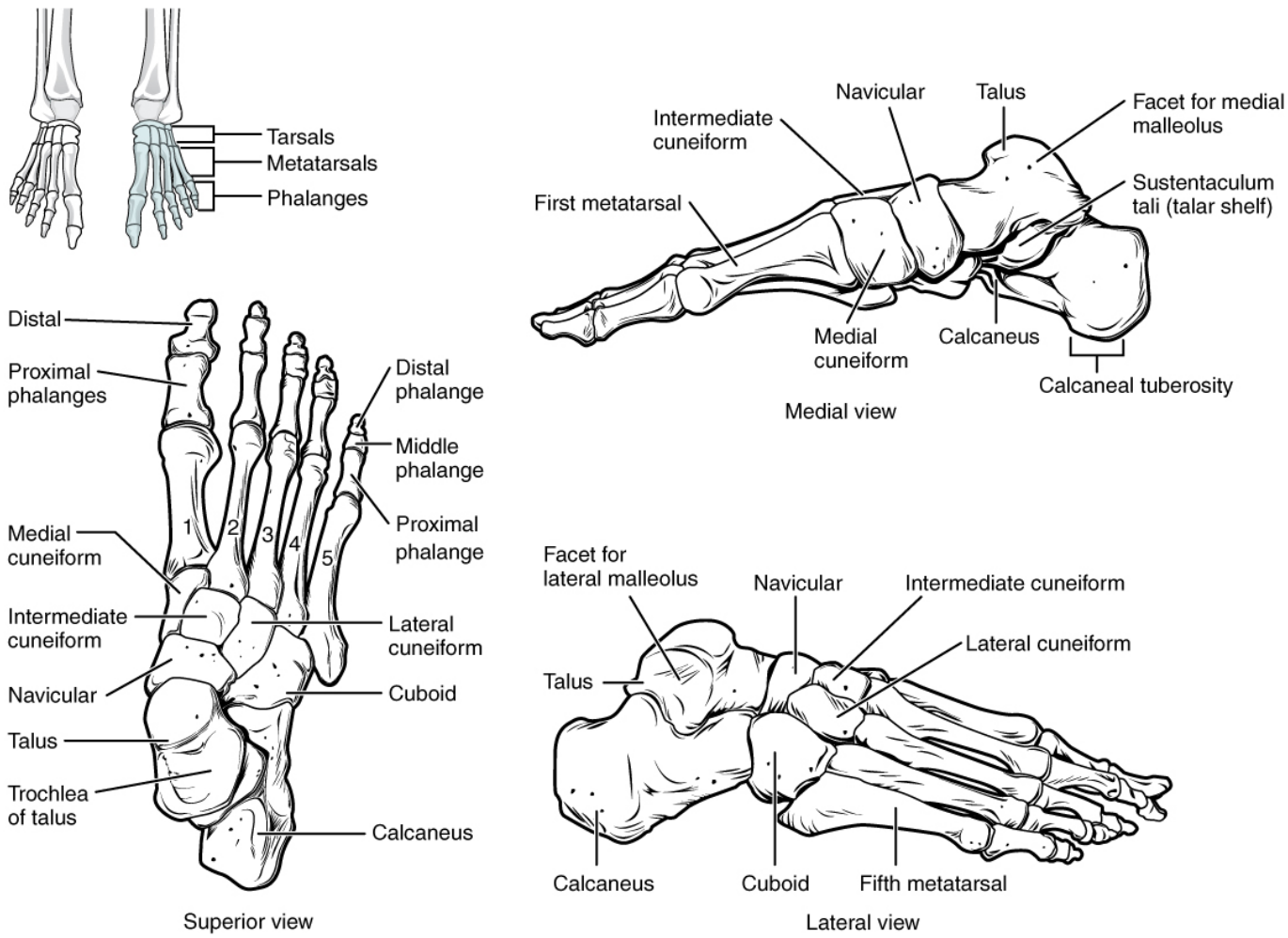

The bones of the foot are divided into three groups. The posterior foot is formed by the seven tarsal bones. The mid-foot has the five metatarsal bones. The toes contain the phalanges.

Metatarsal Bones

The anterior half of the foot is formed by the five metatarsal bones, which are located between the tarsal bones of the posterior foot and the phalanges of the toes (see Figure). These elongated bones are numbered 1–5, starting with the medial side of the foot. The first metatarsal bone is shorter and thicker than the others. The second metatarsal is the longest. The base of the metatarsal boneis the proximal end of each metatarsal bone. These articulate with the cuboid or cuneiform bones. The base of the fifth metatarsal has a large, lateral expansion that provides for muscle attachments. This expanded base of the fifth metatarsal can be felt as a bony bump at the midpoint along the lateral border of the foot. The expanded distal end of each metatarsal is the head of the metatarsal bone. Each metatarsal bone articulates with the proximal phalanx of a toe to form a metatarsophalangeal joint. The heads of the metatarsal bones also rest on the ground and form the ball (anterior end) of the foot.

Phalanges

The toes contain a total of 14 phalanx bones (phalanges), arranged in a similar manner as the phalanges of the fingers (see Figure). The toes are numbered 1–5, starting with the big toe (hallux). The big toe has two phalanx bones, the proximal and distal phalanges. The remaining toes all have proximal, middle, and distal phalanges. A joint between adjacent phalanx bones is called an interphalangeal joint.

View this link to learn about a bunion, a localized swelling on the medial side of the foot, next to the first metatarsophalangeal joint, at the base of the big toe. What is a bunion and what type of shoe is most likely to cause this to develop?

Arches of the Foot

When the foot comes into contact with the ground during walking, running, or jumping activities, the impact of the body weight puts a tremendous amount of pressure and force on the foot. During running, the force applied to each foot as it contacts the ground can be up to 2.5 times your body weight. The bones, joints, ligaments, and muscles of the foot absorb this force, thus greatly reducing the amount of shock that is passed superiorly into the lower limb and body. The arches of the foot play an important role in this shock-absorbing ability. When weight is applied to the foot, these arches will flatten somewhat, thus absorbing energy. When the weight is removed, the arch rebounds, giving “spring” to the step. The arches also serve to distribute body weight side to side and to either end of the foot.

Stretching of the ligaments that support the longitudinal arches can lead to pain. This can occur in overweight individuals, with people who have jobs that involve standing for long periods of time (such as a waitress), or walking or running long distances. If stretching of the ligaments is prolonged, excessive, or repeated, it can result in a gradual lengthening of the supporting ligaments, with

subsequent depression or collapse of the longitudinal arches, particularly on the medial side of the foot. This condition is called pes planus ("flat foot" or "fallen arches").

Glossary

Mnemonic Device for Latin Roots

Example	Latin or Greek Translation	Mnemonic Device
ad	to; toward	ADvance toward your goal
ab	away from	n/a
sub	under	SUBmarines move under water.
ductor	something that moves	A conDUCTOR makes a train move.
anti	against	If you are antisocial, you are against engaging in social activities.
epi	on top of	n/a
apo	to the side of	n/a
longissimus	longest	"Longissimus" is longer than the word "long."
longus	long	long
brevis	short	brief
maximus	large	max
medius	medium	"Medius" and "medium" both begin with "med."
minimus	tiny; little	mini
rectus	straight	To RECTify a situation is to straighten it out.
multi	many	If something is MULTIcolored, it has many colors.
uni	one	A UNIcorn has one horn.
bi/di	two	If a ring is DIcast, it is made of two metals.
tri	three	TRIple the amount of money is three times as much.
quad	four	QUADruplets are four children born at one birth.
externus	outside	EXternal
internus	inside	INternal

Divisions of the Skeletal System

appendicular skeleton: all bones of the upper and lower limbs, plus the girdle bones that attach each limb to the axial skeleton

axial skeleton: central, vertical axis of the body, including the skull, vertebral column, and thoracic cage

coccyx: small bone located at inferior end of the adult vertebral column that is formed by the fusion of four coccygeal vertebrae; also referred to as the "tailbone"

ear ossicles: three small bones located in the middle ear cavity that serve to transmit sound vibrations to the inner ear

hyoid bone: small, U-shaped bone located in upper neck that does not contact any other bone

ribs: thin, curved bones of the chest wall

sacrum: single bone located near the inferior end of the adult vertebral column that is formed by the fusion of five sacral vertebrae; forms the posterior portion of the pelvis

skeleton: bones of the body

skull: bony structure that forms the head, face, and jaws, and protects the brain; consists of 22 bones

sternum: flattened bone located at the center of the anterior chest

thoracic cage: consists of 12 pairs of ribs and sternum

vertebra: individual bone in the neck and back regions of the vertebral column

vertebral column: entire sequence of bones that extend from the skull to the tailbone

The Skull

alveolar process of the mandible: upper border of mandibular body that contains the lower teeth

alveolar process of the maxilla: curved, inferior margin of the maxilla that supports and anchors the upper teeth

angle of the mandible: rounded corner located at outside margin of the body and ramus junction

anterior cranial fossa: shallowest and most anterior cranial fossa of the cranial base that extends from the frontal bone to the lesser wing of the sphenoid bone

articular tubercle: smooth ridge located on the inferior skull, immediately anterior to the mandibular fossa

brain case: portion of the skull that contains and protects the brain, consisting of the eight bones that form the cranial base and rounded upper skull

calvaria: (also, skullcap) rounded top of the skull

carotid canal: zig-zag tunnel providing passage through the base of the skull for the internal carotid artery to the brain; begins anteromedial to the styloid process and terminates in the middle cranial cavity, near the posterior-lateral base of the sella turcica

condylar process of the mandible: thickened upward projection from posterior margin of mandibular ramus

condyle: oval-shaped process located at the top of the condylar process of the mandible

coronal suture: joint that unites the frontal bone to the right and left parietal bones across the top of the skull

coronoid process of the mandible: flattened upward projection from the anterior margin of the mandibular ramus

cranial cavity: interior space of the skull that houses the brain

cranium: skull

cribriform plate: small, flattened areas with numerous small openings, located to either side of the midline in the floor of the anterior cranial fossa; formed by the ethmoid bone

crista galli: small upward projection located at the midline in the floor of the anterior cranial fossa; formed by the ethmoid bone

ethmoid air cell: one of several small, air-filled spaces located within the lateral sides of the ethmoid bone, between the orbit and upper nasal cavity

ethmoid bone: unpaired bone that forms the roof and upper, lateral walls of the nasal cavity, portions of the floor of the anterior cranial fossa and medial wall of orbit, and the upper portion of the nasal septum

external acoustic meatus: ear canal opening located on the lateral side of the skull

external occipital protuberance: small bump located at the midline on the posterior skull

facial bones: fourteen bones that support the facial structures and form the upper and lower jaws and the hard palate

foramen lacerum: irregular opening in the base of the skull, located inferior to the exit of carotid canal

foramen magnum: large opening in the occipital bone of the skull through which the spinal cord emerges and the vertebral arteries enter the cranium

foramen ovale of the middle cranial fossa: oval-shaped opening in the floor of the middle cranial fossa

foramen rotundum: round opening in the floor of the middle cranial fossa, located between the superior orbital fissure and foramen ovale

foramen spinosum: small opening in the floor of the middle cranial fossa, located lateral to the foramen ovale

frontal bone: unpaired bone that forms forehead, roof of orbit, and floor of anterior cranial fossa

frontal sinus: air-filled space within the frontal bone; most anterior of the paranasal sinuses

glabella: slight depression of frontal bone, located at the midline between the eyebrows

greater wings of sphenoid bone: lateral projections of the sphenoid bone that form the anterior wall of the middle cranial fossa and an area of the lateral skull

hard palate: bony structure that forms the roof of the mouth and floor of the nasal cavity, formed by the palatine process of the maxillary bones and the horizontal plate of the palatine bones

horizontal plate: medial extension from the palatine bone that forms the posterior quarter of the hard palate

hypoglossal canal: paired openings that pass anteriorly from the anterior-lateral margins of the foramen magnum deep to the occipital condyles

hypophyseal (pituitary) fossa: shallow depression on top of the sella turcica that houses the pituitary (hypophyseal) gland

inferior nasal concha: one of the paired bones that project from the lateral walls of the nasal cavity to form the largest and most inferior of the nasal conchae

infraorbital foramen: opening located on anterior skull, below the orbit

infratemporal fossa: space on lateral side of skull, below the level of the zygomatic arch and deep (medial) to the ramus of the mandible

internal acoustic meatus: opening into petrous ridge, located on the lateral wall of the posterior cranial fossa

jugular foramen: irregularly shaped opening located in the lateral floor of the posterior cranial cavity

lacrimal bone: paired bones that contribute to the anterior-medial wall of each orbit

lacrimal fossa: shallow depression in the anterior-medial wall of the orbit, formed by the lacrimal bone that gives rise to the nasolacrimal canal

lambdoid suture: inverted V-shaped joint that unites the occipital bone to the right and left parietal bones on the posterior skull

lateral pterygoid plate: paired, flattened bony projections of the sphenoid bone located on the inferior skull, lateral to the medial pterygoid plate

lesser wings of the sphenoid bone: lateral extensions of the sphenoid bone that form the bony lip separating the anterior and middle cranial fossae

lingula: small flap of bone located on the inner (medial) surface of mandibular ramus, next to the mandibular: foramen

mandible: unpaired bone that forms the lower jaw bone; the only moveable bone of the skull

mandibular foramen: opening located on the inner (medial) surface of the mandibular ramus

mandibular fossa: oval depression located on the inferior surface of the skull

mandibular notch: large U-shaped notch located between the condylar process and coronoid process of the mandible

mastoid process: large bony prominence on the inferior, lateral skull, just behind the earlobe

maxillary bone: (also, maxilla) paired bones that form the upper jaw and anterior portion of the hard palate

maxillary sinus: air-filled space located with each maxillary bone; largest of the paranasal sinuses

medial pterygoid plate: paired, flattened bony projections of the sphenoid bone located on the inferior skull medial to the lateral pterygoid plate; form the posterior portion of the nasal cavity lateral wall

mental foramen: opening located on the anterior-lateral side of the mandibular body

mental protuberance: inferior margin of anterior mandible that forms the chin

middle cranial fossa: centrally located cranial fossa that extends from the lesser wings of the sphenoid bone to the petrous ridge

middle nasal concha: nasal concha formed by the ethmoid bone that is located between the superior and inferior conchae

mylohyoid line: bony ridge located along the inner (medial) surface of the mandibular body

nasal bone: paired bones that form the base of the nose

nasal cavity: opening through skull for passage of air

nasal conchae: curved bony plates that project from the lateral walls of the nasal cavity; include the superior and middle nasal conchae, which are parts of the ethmoid bone, and the independent inferior nasal conchae bone

nasal septum: flat, midline structure that divides the nasal cavity into halves, formed by the perpendicular plate of the ethmoid bone, vomer bone, and septal cartilage

nasolacrimal canal: passage for drainage of tears that extends downward from the medial-anterior orbit to the nasal cavity, terminating behind the inferior nasal conchae

occipital bone: unpaired bone that forms the posterior portions of the brain case and base of the skull

occipital condyle: paired, oval-shaped bony knobs located on the inferior skull, to either side of the foramen magnum

optic canal: opening spanning between middle cranial fossa and posterior orbit

orbit: bony socket that contains the eyeball and associated muscles

palatine bone: paired bones that form the posterior quarter of the hard palate and a small area in floor of the orbit

palatine process: medial projection from the maxilla bone that forms the anterior three quarters of the hard palate

paranasal sinuses: cavities within the skull that are connected to the conchae that serve to warm and humidify incoming air, produce mucus, and lighten the weight of the skull; consist of frontal, maxillary, sphenoidal, and ethmoidal sinuses

parietal bone: paired bones that form the upper, lateral sides of the skull

perpendicular plate of the ethmoid bone: downward, midline extension of the ethmoid bone that forms the superior portion of the nasal septum

petrous ridge: petrous portion of the temporal bone that forms a large, triangular ridge in the floor of the cranial cavity, separating the middle and posterior cranial fossae; houses the middle and inner ear structures

posterior cranial fossa: deepest and most posterior cranial fossa; extends from the petrous ridge to the occipital bone

pterion: H-shaped suture junction region that unites the frontal, parietal, temporal, and sphenoid bones on the lateral side of the skull

ramus of the mandible: vertical portion of the mandible

sagittal suture: joint that unites the right and left parietal bones at the midline along the top of the skull

sella turcica: elevated area of sphenoid bone located at midline of the middle cranial fossa

septal cartilage: flat cartilage structure that forms the anterior portion of the nasal septum

sphenoid bone: unpaired bone that forms the central base of skull

sphenoid sinus: air-filled space located within the sphenoid bone; most posterior of the paranasal sinuses

squamous suture: joint that unites the parietal bone to the squamous portion of the temporal bone on the lateral side of the skull

styloid process: downward projecting, elongated bony process located on the inferior aspect of the skull

stylomastoid foramen: opening located on inferior skull, between the styloid process and mastoid process

superior nasal concha: smallest and most superiorly located of the nasal conchae; formed by the ethmoid bone

superior nuchal line: paired bony lines on the posterior skull that extend laterally from the external occipital protuberance

superior orbital fissure: irregularly shaped opening between the middle cranial fossa and the posterior orbit

supraorbital foramen: opening located on anterior skull, at the superior margin of the orbit

supraorbital margin: superior margin of the orbit

suture: junction line at which adjacent bones of the skull are united by fibrous connective tissue

temporal bone: paired bones that form the lateral, inferior portions of the skull, with squamous, mastoid, and petrous portions

temporal fossa: shallow space on the lateral side of the skull, above the level of the zygomatic arch

temporal process of the zygomatic bone: short extension from the zygomatic bone that forms the anterior portion of the zygomatic arch

vomer bone: unpaired bone that forms the inferior and posterior portions of the nasal septum

zygomatic arch: elongated, free-standing arch on the lateral skull, formed anteriorly by the temporal process of the zygomatic bone and posteriorly by the zygomatic process of the temporal bone

zygomatic bone: cheekbone; paired bones that contribute to the lateral orbit and anterior zygomatic arch

zygomatic process of the temporal bone: extension from the temporal bone that forms the posterior portion of the zygomatic arch

The Vertebral Column

anterior arch: anterior portion of the ring-like C1 (atlas) vertebra

anterior longitudinal ligament: ligament that runs the length of the vertebral column, uniting the anterior aspects of the vertebral bodies

anterior (ventral) sacral foramen: one of the series of paired openings located on the anterior (ventral) side of the sacrum

anulus fibrosus: tough, fibrous outer portion of an intervertebral disc, which is strongly anchored to the bodies of the adjacent vertebrae

atlas: first cervical (C1) vertebra

axis: second cervical (C2) vertebra

cervical curve: posteriorly concave curvature of the cervical vertebral column region; a secondary curve of the vertebral column

cervical vertebrae: seven vertebrae numbered as C1–C7 that are located in the neck region of the vertebral column

costal facet: site on the lateral sides of a thoracic vertebra for articulation with the head of a rib

dens: bony projection (odontoid process) that extends upward from the body of the C2 (axis) vertebra

facet: small, flattened area on a bone for an articulation (joint) with another bone, or for muscle attachment

inferior articular process: bony process that extends downward from the vertebral arch of a vertebra that articulates with the superior articular process of the next lower vertebra

intervertebral disc: structure located between the bodies of adjacent vertebrae that strongly joins the vertebrae; provides padding, weight bearing ability, and enables vertebral column movements

intervertebral foramen: opening located between adjacent vertebrae for exit of a spinal nerve

kyphosis: (also, humpback or hunchback) excessive posterior curvature of the thoracic vertebral column region

lamina: portion of the vertebral arch on each vertebra that extends between the transverse and spinous process

lateral sacral crest: paired irregular ridges running down the lateral sides of the posterior sacrum that was formed by the fusion of the transverse processes from the five sacral vertebrae

ligamentum flavum: series of short ligaments that unite the lamina of adjacent vertebrae

lordosis: (also, swayback) excessive anterior curvature of the lumbar vertebral column region

lumbar curve: posteriorly concave curvature of the lumbar vertebral column region; a secondary curve of the vertebral column

lumbar vertebrae: five vertebrae numbered as L1–L5 that are located in lumbar region (lower back) of the vertebral column

median sacral crest: irregular ridge running down the midline of the posterior sacrum that was formed from the fusion of the spinous processes of the five sacral vertebrae

nuchal ligament: expanded portion of the supraspinous ligament within the posterior neck; interconnects the spinous processes of the cervical vertebrae and attaches to the base of the skull

nucleus pulposus: gel-like central region of an intervertebral disc; provides for padding, weight-bearing, and movement between adjacent vertebrae

pedicle: portion of the vertebral arch that extends from the vertebral body to the transverse process

posterior arch: posterior portion of the ring-like C1 (atlas) vertebra

posterior longitudinal ligament: ligament that runs the length of the vertebral column, uniting the posterior sides of the vertebral bodies

posterior (dorsal) sacral foramen: one of the series of paired openings located on the posterior (dorsal) side of the sacrum

primary curve: anteriorly concave curvatures of the thoracic and sacrococcygeal regions that are retained from the original fetal curvature of the vertebral column

sacral canal: bony tunnel that runs through the sacrum

sacral foramina: series of paired openings for nerve exit located on both the anterior (ventral) and posterior (dorsal) aspects of the sacrum

sacral hiatus: inferior opening and termination of the sacral canal

sacral promontory: anterior lip of the base (superior end) of the sacrum

sacrococcygeal curve: anteriorly concave curvature formed by the sacrum and coccyx; a primary curve of the vertebral column

scoliosis: abnormal lateral curvature of the vertebral column

secondary curve: posteriorly concave curvatures of the cervical and lumbar regions of the vertebral column that develop after the time of birth

spinous process: unpaired bony process that extends posteriorly from the vertebral arch of a vertebra

superior articular process: bony process that extends upward from the vertebral arch of a vertebra that articulates with the inferior articular process of the next higher vertebra

superior articular process of the sacrum: paired processes that extend upward from the sacrum to articulate (join) with the inferior articular processes from the L5 vertebra

supraspinous ligament: ligament that interconnects the spinous processes of the thoracic and lumbar vertebrae

thoracic curve: anteriorly concave curvature of the thoracic vertebral column region; a primary curve of the vertebral column

thoracic vertebrae: twelve vertebrae numbered as T1–T12 that are located in the thoracic region (upper back) of the vertebral column

transverse foramen: opening found only in the transverse processes of cervical vertebrae

transverse process: paired bony processes that extends laterally from the vertebral arch of a vertebra

vertebral arch: bony arch formed by the posterior portion of each vertebra that surrounds and protects the spinal cord

vertebral (spinal) canal: bony passageway within the vertebral column for the spinal cord that is formed by the series of individual vertebral foramina

vertebral foramen: opening associated with each vertebra defined by the vertebral arch that provides passage for the spinal cord

The Thoracic Cage (Ribs and Sternum)

angle of the rib: portion of rib with greatest curvature; together, the rib angles form the most posterior extent of the thoracic cage

body of the rib: shaft portion of a rib

clavicular notch: paired notches located on the superior-lateral sides of the sternal manubrium, for articulation with the clavicle

costal cartilage: hyaline cartilage structure attached to the anterior end of each rib that provides for either direct or indirect attachment of most ribs to the sternum

costal groove: shallow groove along the inferior margin of a rib that provides passage for blood vessels and a nerve

false ribs: vertebrochondral ribs 8–12 whose costal cartilage either attaches indirectly to the sternum via the costal cartilage of the next higher rib or does not attach to the sternum at all

floating ribs: vertebral ribs 11–12 that do not attach to the sternum or to the costal cartilage of another rib

head of the rib: posterior end of a rib that articulates with the bodies of thoracic vertebrae

jugular (suprasternal) notch: shallow notch located on superior surface of sternal manubrium

manubrium: expanded, superior portion of the sternum

neck of the rib: narrowed region of a rib, next to the rib head

sternal angle: junction line between manubrium and body of the sternum and the site for attachment of the second rib to the sternum

true ribs: vertebrosternal ribs 1–7 that attach via their costal cartilage directly to the sternum

tubercle of the rib: small bump on the posterior side of a rib for articulation with the transverse process of a thoracic vertebra

xiphoid process: small process that forms the inferior tip of the sternum

The Pectoral Girdle

acromial end of the clavicle: lateral end of the clavicle that articulates with the acromion of the scapula

acromial process: acromion of the scapula

acromioclavicular joint: articulation between the acromion of the scapula and the acromial end of the clavicle

acromion: flattened bony process that extends laterally from the scapular spine to form the bony tip of the shoulder

clavicle: collarbone; elongated bone that articulates with the manubrium of the sternum medially and the acromion of the scapula laterally

coracoclavicular ligament: strong band of connective tissue that anchors the coracoid process of the scapula to the lateral clavicle; provides important indirect support for the acromioclavicular joint

coracoid process: short, hook-like process that projects anteriorly and laterally from the superior margin of the scapula

costoclavicular ligament: band of connective tissue that unites the medial clavicle with the first rib

fossa: (plural = **fossae**) shallow depression on the surface of a bone

glenohumeral joint: shoulder joint; formed by the articulation between the glenoid cavity of the scapula and the head of the humerus

glenoid cavity: (also, glenoid fossa) shallow depression located on the lateral scapula, between the superior and lateral borders

inferior angle of the scapula: inferior corner of the scapula located where the medial and lateral borders meet

infraglenoid tubercle: small bump or roughened area located on the lateral border of the scapula, near the inferior margin of the glenoid cavity

infraspinous fossa: broad depression located on the posterior scapula, inferior to the spine

lateral border of the scapula: diagonally oriented lateral margin of the scapula

medial border of the scapula: elongated, medial margin of the scapula

pectoral girdle: shoulder girdle; the set of bones, consisting of the scapula and clavicle, which attaches each upper limb to the axial skeleton

scapula: shoulder blade bone located on the posterior side of the shoulder

spine of the scapula: prominent ridge passing mediolaterally across the upper portion of the posterior scapular surface

sternal end of the clavicle: medial end of the clavicle that articulates with the manubrium of the sternum

sternoclavicular joint: articulation between the manubrium of the sternum and the sternal end of the clavicle; forms the only bony attachment between the pectoral girdle of the upper limb and the axial skeleton

subscapular fossa: broad depression located on the anterior (deep) surface of the scapula

superior angle of the scapula: corner of the scapula between the superior and medial borders of the scapula

superior border of the scapula: superior margin of the scapula

supraglenoid tubercle: small bump located at the superior margin of the glenoid cavity

suprascapular notch: small notch located along the superior border of the scapula, medial to the coracoid process

supraspinous fossa: narrow depression located on the posterior scapula, superior to the spine

Bones of the Upper Limb

anatomical neck: line on the humerus located around the outside margin of the humeral head

arm: region of the upper limb located between the shoulder and elbow joints; contains the humerus bone

bicipital groove: intertubercular groove; narrow groove located between the greater and lesser tubercles of the humerus

capitate: from the lateral side, the third of the four distal carpal bones; articulates with the scaphoid and lunate proximally, the trapezoid laterally, the hamate medially, and primarily with the third metacarpal distally

capitulum: knob-like bony structure located anteriorly on the lateral, distal end of the humerus

carpal bone: one of the eight small bones that form the wrist and base of the hand; these are grouped as a proximal row consisting of (from lateral to medial) the scaphoid, lunate, triquetrum, and pisiform bones, and a distal row containing (from lateral to medial) the trapezium, trapezoid, capitate, and hamate bones

carpal tunnel: passageway between the anterior forearm and hand formed by the carpal bones and flexor retinaculum

carpometacarpal joint: articulation between one of the carpal bones in the distal row and a metacarpal bone of the hand

coronoid fossa: depression on the anterior surface of the humerus above the trochlea; this space receives the coronoid process of the ulna when the elbow is maximally flexed

coronoid process of the ulna: projecting bony lip located on the anterior, proximal ulna; forms the inferior margin of the trochlear notch

deltoid tuberosity: roughened, V-shaped region located laterally on the mid-shaft of the humerus

distal radioulnar joint: articulation between the head of the ulna and the ulnar notch of the radius

elbow joint: joint located between the upper arm and forearm regions of the upper limb; formed by the articulations between the trochlea of the humerus and the trochlear notch of the ulna, and the capitulum of the humerus and the head of the radius

flexor retinaculum: strong band of connective tissue at the anterior wrist that spans the top of the U-shaped grouping of the carpal bones to form the roof of the carpal tunnel

forearm: region of the upper limb located between the elbow and wrist joints; contains the radius and ulna bones

greater tubercle: enlarged prominence located on the lateral side of the proximal humerus

hamate: from the lateral side, the fourth of the four distal carpal bones; articulates with the lunate and triquetrum proximally, the fourth and fifth metacarpals distally, and the capitate laterally

hand: region of the upper limb distal to the wrist joint

head of the humerus: smooth, rounded region on the medial side of the proximal humerus; articulates with the glenoid fossa of the scapula to form the glenohumeral (shoulder) joint

head of the radius: disc-shaped structure that forms the proximal end of the radius; articulates with the capitulum of the humerus as part of the elbow joint, and with the radial notch of the ulna as part of the proximal radioulnar joint

head of the ulna: small, rounded distal end of the ulna; articulates with the ulnar notch of the distal radius, forming the distal radioulnar joint

hook of the hamate bone: bony extension located on the anterior side of the hamate carpal bone

humerus: single bone of the upper arm

interosseous border of the radius: narrow ridge located on the medial side of the radial shaft; for attachment of the interosseous membrane between the ulna and radius bones

interosseous border of the ulna: narrow ridge located on the lateral side of the ulnar shaft; for attachment of the interosseous membrane between the ulna and radius

interosseous membrane of the forearm: sheet of dense connective tissue that unites the radius and ulna bones

interphalangeal joint: articulation between adjacent phalanx bones of the hand or foot digits

intertubercular groove (sulcus): bicipital groove; narrow groove located between the greater and lesser tubercles of the humerus

lateral epicondyle of the humerus: small projection located on the lateral side of the distal humerus

lateral supracondylar ridge: narrow, bony ridge located along the lateral side of the distal humerus, superior to the lateral epicondyle

lesser tubercle: small, bony prominence located on anterior side of the proximal humerus

lunate: from the lateral side, the second of the four proximal carpal bones; articulates with the radius proximally, the capitate and hamate distally, the scaphoid laterally, and the triquetrum medially

medial epicondyle of the humerus: enlarged projection located on the medial side of the distal humerus

metacarpal bone: one of the five long bones that form the palm of the hand; numbered 1–5, starting on the lateral (thumb) side of the hand

metacarpophalangeal joint: articulation between the distal end of a metacarpal bone of the hand and a proximal phalanx bone of the thumb or a finger

midcarpal joint: articulation between the proximal and distal rows of the carpal bones; contributes to movements of the hand at the wrist

neck of the radius: narrowed region immediately distal to the head of the radius

olecranon fossa: large depression located on the posterior side of the distal humerus; this space receives the olecranon process of the ulna when the elbow is fully extended

olecranon process: expanded posterior and superior portions of the proximal ulna; forms the bony tip of the elbow

phalanx bone of the hand: (plural = **phalanges**) one of the 14 bones that form the thumb and fingers; these include the proximal and distal phalanges of the thumb, and the proximal, middle, and distal phalanx bones of the fingers two through five

pisiform: from the lateral side, the fourth of the four proximal carpal bones; articulates with the anterior surface of the triquetrum

pollex: (also, thumb) digit 1 of the hand

proximal radioulnar joint: articulation formed by the radial notch of the ulna and the head of the radius

radial fossa: small depression located on the anterior humerus above the capitulum; this space receives the head of the radius when the elbow is maximally flexed

radial notch of the ulna: small, smooth area on the lateral side of the proximal ulna; articulates with the head of the radius as part of the proximal radioulnar joint

radial tuberosity: oval-shaped, roughened protuberance located on the medial side of the proximal radius

radiocarpal joint: wrist joint, located between the forearm and hand regions of the upper limb; articulation formed proximally by the distal end of the radius and the fibrocartilaginous pad that unites the distal radius and ulna bone, and distally by the scaphoid, lunate, and triquetrum carpal bones

radius: bone located on the lateral side of the forearm

scaphoid: from the lateral side, the first of the four proximal carpal bones; articulates with the radius proximally, the trapezoid, trapezium, and capitate distally, and the lunate medially

shaft of the humerus: narrow, elongated, central region of the humerus

shaft of the radius: narrow, elongated, central region of the radius

shaft of the ulna: narrow, elongated, central region of the ulna

styloid process of the radius: pointed projection located on the lateral end of the distal radius

styloid process of the ulna: short, bony projection located on the medial end of the distal ulna

surgical neck: region of the humerus where the expanded, proximal end joins with the narrower shaft

trapezium: from the lateral side, the first of the four distal carpal bones; articulates with the scaphoid proximally, the first and second metacarpals distally, and the trapezoid medially

trapezoid: from the lateral side, the second of the four distal carpal bones; articulates with the scaphoid proximally, the second metacarpal distally, the trapezium laterally, and the capitate medially

triquetrum: from the lateral side, the third of the four proximal carpal bones; articulates with the lunate laterally, the hamate distally, and has a facet for the pisiform

trochlea: pulley-shaped region located medially at the distal end of the humerus; articulates at the elbow with the trochlear notch of the ulna

trochlear notch: large, C-shaped depression located on the anterior side of the proximal ulna; articulates at the elbow with the trochlea of the humerus

ulna: bone located on the medial side of the forearm

ulnar notch of the radius: shallow, smooth area located on the medial side of the distal radius; articulates with the head of the ulna at the distal radioulnar joint

ulnar tuberosit: roughened area located on the anterior, proximal ulna inferior to the coronoid process

The Pelvic Girdle and Pelvis

acetabulum: large, cup-shaped cavity located on the lateral side of the hip bone; formed by the junction of the ilium, pubis, and ischium portions of the hip bone

anterior inferior iliac spine: small, bony projection located on the anterior margin of the ilium, below the anterior superior iliac spine

anterior sacroiliac ligament: strong ligament between the sacrum and the ilium portions of the hip bone that supports the anterior side of the sacroiliac joint

anterior superior iliac spine: rounded, anterior end of the iliac crest

arcuate line of the ilium: smooth ridge located at the inferior margin of the iliac fossa; forms the lateral portion of the pelvic brim

auricular surface of the ilium: roughened area located on the posterior, medial side of the ilium of the hip bone; articulates with the auricular surface of the sacrum to form the sacroiliac joint

coxal bone: hip bone

greater pelvis: (also, greater pelvic cavity or false pelvis) broad space above the pelvic brim defined laterally by the fan-like portion of the upper ilium

greater sciatic foramen: pelvic opening formed by the greater sciatic notch of the hip bone, the sacrum, and the sacrospinous ligament

greater sciatic notch: large, U-shaped indentation located on the posterior margin of the ilium, superior to the ischial spine

hip bone: coxal bone; single bone that forms the pelvic girdle; consists of three areas, the ilium, ischium, and pubis

iliac crest: curved, superior margin of the ilium

iliac fossa: shallow depression found on the anterior and medial surfaces of the upper ilium

Ilium: superior portion of the hip bone

inferior pubic ramus: narrow segment of bone that passes inferiorly and laterally from the pubic body; joins with the ischial ramus to form the ischiopubic ramus

ischial ramus: bony extension projecting anteriorly and superiorly from the ischial tuberosity; joins with the inferior pubic ramus to form the ischiopubic ramus

ischial spine: pointed, bony projection from the posterior margin of the ischium that separates the greater sciatic notch and lesser sciatic notch

ischial tuberosity: large, roughened protuberance that forms the posteroinferior portion of the hip bone; weight-bearing region of the pelvis when sitting

ischiopubic ramus: narrow extension of bone that connects the ischial tuberosity to the pubic body; formed by the junction of the ischial ramus and inferior pubic ramus

Ischium: posteroinferior portion of the hip bone

lesser pelvis: (also, lesser pelvic cavity or true pelvis) narrow space located within the pelvis, defined superiorly by the pelvic brim (pelvic inlet) and inferiorly by the pelvic outlet

lesser sciatic foramen: pelvic opening formed by the lesser sciatic notch of the hip bone, the sacrospinous ligament, and the sacrotuberous ligament

lesser sciatic notch: shallow indentation along the posterior margin of the ischium, inferior to the ischial spine

obturator foramen: large opening located in the anterior hip bone, between the pubis and ischium regions

pectineal line: narrow ridge located on the superior surface of the superior pubic ramus

pelvic brim: pelvic inlet; the dividing line between the greater and lesser pelvic regions; formed by the superior margin of the pubic symphysis, the pectineal lines of each pubis, the arcuate lines of each ilium, and the sacral promontory

pelvic girdle: hip girdle; consists of a single hip bone, which attaches a lower limb to the sacrum of the axial skeleton

pelvic inlet: pelvic brim

pelvic outlet: inferior opening of the lesser pelvis; formed by the inferior margin of the pubic symphysis, right and left ischiopubic rami and sacrotuberous ligaments, and the tip of the coccyx

pelvis: ring of bone consisting of the right and left hip bones, the sacrum, and the coccyx

posterior inferior iliac spine: small, bony projection located at the inferior margin of the auricular surface on the posterior ilium

posterior sacroiliac ligament: strong ligament spanning the sacrum and ilium of the hip bone that supports the posterior side of the sacroiliac joint

posterior superior iliac spine: rounded, posterior end of the iliac crest

pubic arch: bony structure formed by the pubic symphysis, and the bodies and inferior pubic rami of the right and left pubic bones

pubic body: enlarged, medial portion of the pubis region of the hip bone

pubic symphysis: joint formed by the articulation between the pubic bodies of the right and left hip bones

pubic tubercle: small bump located on the superior aspect of the pubic body

pubis: anterior portion of the hip bone

sacroiliac joint: joint formed by the articulation between the auricular surfaces of the sacrum and ilium

sacrospinous ligament: ligament that spans the sacrum to the ischial spine of the hip bone

sacrotuberous ligament: ligament that spans the sacrum to the ischial tuberosity of the hip bone

subpubic angle: inverted V-shape formed by the convergence of the right and left ischiopubic rami; this angle is greater than 80 degrees in females and less than 70 degrees in males

superior pubic ramus: narrow segment of bone that passes laterally from the pubic body to join the ilium

Bones of the Lower Limb

adductor tubercle: small, bony bump located on the superior aspect of the medial epicondyle of the femur

ankle joint: joint that separates the leg and foot portions of the lower limb; formed by the articulations between the talus bone of the foot inferiorly, and the distal end of the tibia, medial malleolus of the tibia, and lateral malleolus of the fibula superiorly

anterior border of the tibia: narrow, anterior margin of the tibia that extends inferiorly from the tibial tuberosity

base of the metatarsal bone: expanded, proximal end of each metatarsal bone

calcaneus: heel bone; posterior, inferior tarsal bone that forms the heel of the foot

cuboid: tarsal bone that articulates posteriorly with the calcaneus bone, medially with the lateral cuneiform bone, and anteriorly with the fourth and fifth metatarsal bones

distal tibiofibular joint: articulation between the distal fibula and the fibular notch of the tibia

femur: thigh bone; the single bone of the thigh

fibula: thin, non-weight-bearing bone found on the lateral side of the leg

fibular notch: wide groove on the lateral side of the distal tibia for articulation with the fibula at the distal tibiofibular joint

foot: portion of the lower limb located distal to the ankle joint

fovea capitis: minor indentation on the head of the femur that serves as the site of attachment for the ligament to the head of the femur

gluteal tuberosity: roughened area on the posterior side of the proximal femur, extending inferiorly from the base of the greater trochanter

greater trochanter: large, bony expansion of the femur that projects superiorly from the base of the femoral neck

hallux: big toe; digit 1 of the foot

head of the femur: rounded, proximal end of the femur that articulates with the acetabulum of the hip bone to form the hip joint

head of the fibula: small, knob-like, proximal end of the fibula; articulates with the inferior aspect of the lateral condyle of the tibia

head of the metatarsal bone: expanded, distal end of each metatarsal bone

hip joint: joint located at the proximal end of the lower limb; formed by the articulation between the acetabulum of the hip bone and the head of the femur

intercondylar eminence: irregular elevation on the superior end of the tibia, between the articulating surfaces of the medial and lateral condyles

intercondylar fossa: deep depression on the posterior side of the distal femur that separates the medial and lateral condyles

intermediate cuneiform: middle of the three cuneiform tarsal bones; articulates posteriorly with the navicular bone, medially with the medial cuneiform bone, laterally with the lateral cuneiform bone, and anteriorly with the second metatarsal bone

interosseous border of the fibula: small ridge running down the medial side of the fibular shaft; for attachment of the interosseous membrane between the fibula and tibia

interosseous border of the tibia: small ridge running down the lateral side of the tibial shaft; for attachment of the interosseous membrane between the tibia and fibula

interosseous membrane of the leg: sheet of dense connective tissue that unites the shafts of the tibia and fibula bones

intertrochanteric crest: short, prominent ridge running between the greater and lesser trochanters on the posterior side of the proximal femur

intertrochanteric line: small ridge running between the greater and lesser trochanters on the anterior side of the proximal femur

knee joint: joint that separates the thigh and leg portions of the lower limb; formed by the articulations between the medial and lateral condyles of the femur, and the medial and lateral condyles of the tibia

lateral condyle of the femur: smooth, articulating surface that forms the distal and posterior sides of the lateral expansion of the distal femur

lateral condyle of the tibia: lateral, expanded region of the proximal tibia that includes the smooth surface that articulates with the lateral condyle of the femur as part of the knee joint

lateral cuneiform: most lateral of the three cuneiform tarsal bones; articulates posteriorly with the navicular bone, medially with the intermediate cuneiform bone, laterally with the cuboid bone, and anteriorly with the third metatarsal bone

lateral epicondyle of the femur: roughened area of the femur located on the lateral side of the lateral condyle

lateral malleolus: expanded distal end of the fibula

leg: portion of the lower limb located between the knee and ankle joints

lesser trochanter: small, bony projection on the medial side of the proximal femur, at the base of the femoral neck

ligament of the head of the femur: ligament that spans the acetabulum of the hip bone and the fovea capitis of the femoral head

linea aspera: longitudinally running bony ridge located in the middle third of the posterior femur

medial condyle of the femur: smooth, articulating surface that forms the distal and posterior sides of the medial expansion of the distal femur

medial condyle of the tibia: medial, expanded region of the proximal tibia that includes the smooth surface that articulates with the medial condyle of the femur as part of the knee joint

medial cuneiform: most medial of the three cuneiform tarsal bones; articulates posteriorly with the navicular bone, laterally with the intermediate cuneiform bone, and anteriorly with the first and second metatarsal bones

medial epicondyle of the femur: roughened area of the distal femur located on the medial side of the medial condyle

medial malleolus: bony expansion located on the medial side of the distal tibia

metatarsal bone: one of the five elongated bones that forms the anterior half of the foot; numbered 1–5, starting on the medial side of the foot

metatarsophalangeal joint: articulation between a metatarsal bone of the foot and the proximal phalanx bone of a toe

navicular: tarsal bone that articulates posteriorly with the talus bone, laterally with the cuboid bone, and anteriorly with the medial, intermediate, and lateral cuneiform bones

neck of the femur: narrowed region located inferior to the head of the femur

patella: kneecap: the largest sesamoid bone of the body; articulates with the distal femur

patellar surface: smooth groove located on the anterior side of the distal femur, between the medial and lateral condyles; site of articulation for the patella

phalanx bone of the foot: (plural = **phalanges**) one of the 14 bones that form the toes; these include the proximal and distal phalanges of the big toe, and the proximal, middle, and distal phalanx bones of toes two through five

proximal tibiofibular joint: articulation between the head of the fibula and the inferior aspect of the lateral condyle of the tibia

shaft of the femur: cylindrically shaped region that forms the central portion of the femur

shaft of the fibula: elongated, slender portion located between the expanded ends of the fibula

shaft of the tibia: triangular-shaped, central portion of the tibia

soleal line: small, diagonally running ridge located on the posterior side of the proximal tibia

sustentaculum tali: bony ledge extending from the medial side of the calcaneus bone

talus: tarsal bone that articulates superiorly with the tibia and fibula at the ankle joint; also articulates inferiorly with the calcaneus bone and anteriorly with the navicular bone

tarsal bone: one of the seven bones that make up the posterior foot; includes the calcaneus, talus, navicular, cuboid, medial cuneiform, intermediate cuneiform, and lateral cuneiform bones

thigh: portion of the lower limb located between the hip and knee joints

tibia: shin bone; the large, weight-bearing bone located on the medial side of the leg

tibial tuberosity: elevated area on the anterior surface of the proximal tibia

Ha`awina 13: HLTH 140

The Muscular System

Hō`ulu`ulu Pōkole (Overview)

The focus of this chapter is on skeletal muscle organization. The system to name skeletal muscles will be explained; in some cases, the muscle is named by its shape, and in other cases it is named by its location or attachments to the skeleton. If you understand the meaning of the name of the muscle, often it will help you remember its location and/or what it does. This chapter also will describe how skeletal muscles are arranged to accomplish movement, and how other muscles may assist, or be arranged on the skeleton to resist or carry out the opposite movement. The actions of the skeletal muscles will be covered in a regional manner, working from the head down to the toes.

Ke Haumana ka `apo (Student Learning Outcomes)

1. Describe the primary functions of the muscular system.
2. Apply word building skills to the terminology of the muscular system..
3. Describe common abbreviations associated with the muscular system
4. Recognize, define, and pronounce medical terminology associated with the muscular system correctly.

Interactions of Skeletal Muscles, Their Fascicle Arrangement, and Their Lever Systems

To move the skeleton, the tension created by the contraction of the fibers in most skeletal muscles is transferred to the tendons. The tendons are strong bands of dense, regular connective tissue that connect muscles to bones. The bone connection is why this muscle tissue is called skeletal muscle.

Interactions of Skeletal Muscles in the Body

To pull on a bone, that is, to change the angle at its synovial joint, which essentially moves the skeleton, a skeletal muscle must also be attached to a fixed part of the skeleton. The moveable end of the muscle that attaches to the bone being pulled is called the muscle's insertion, and the end of the muscle attached to a fixed (stabilized) bone is called the origin. During forearm flexion—bending the elbow—the brachioradialis assists the brachialis.

Although a number of muscles may be involved in an action, the principal muscle involved is called the prime mover, or agonist. To lift a cup, a muscle called the biceps brachii is actually the prime mover; however, because it can be assisted by the brachialis, the brachialis is called a synergist in this action (Figure). A synergist can also be a fixator that stabilizes the bone that is the attachment for the prime mover's origin.

Prime Movers and Synergists

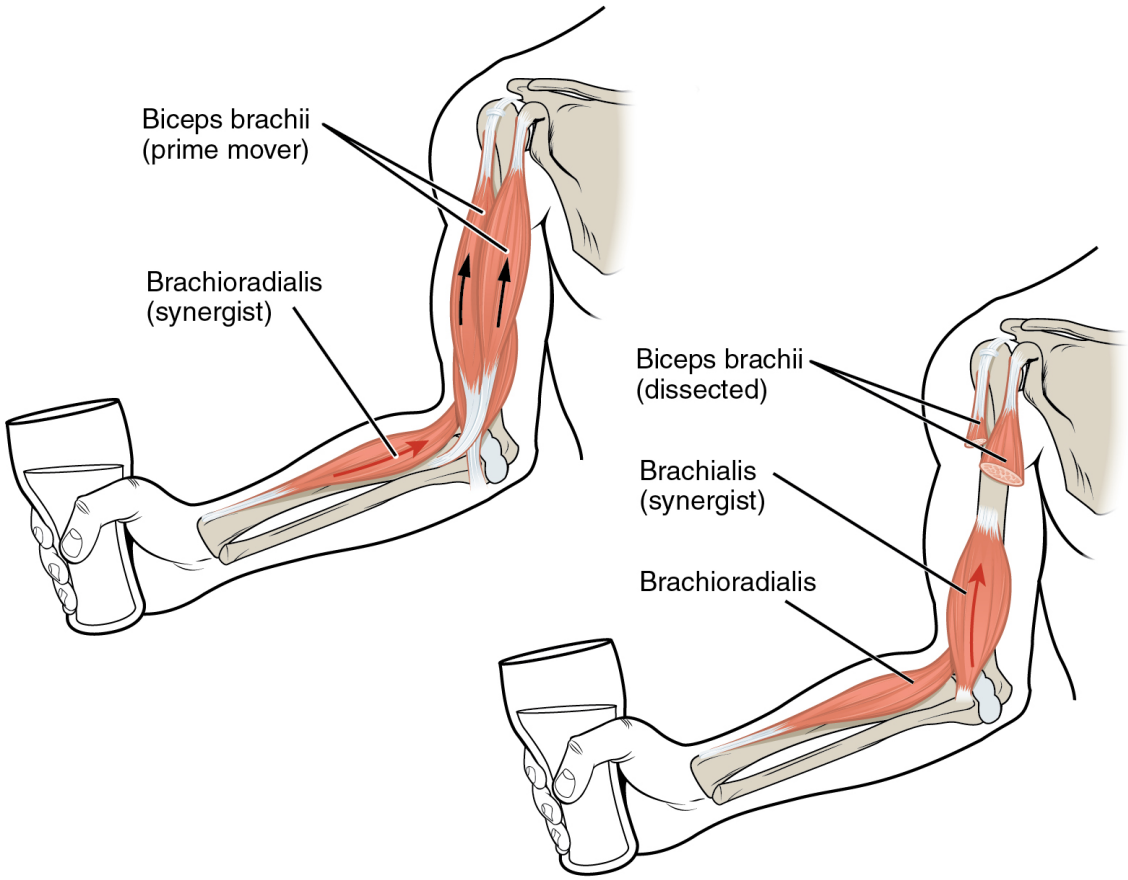

The **biceps brachii** flex the lower arm. The **brachoradialis**, in the forearm, and **brachialis**, located deep to the biceps in the upper arm, are both synergists that aid in this motion.

A muscle with the opposite action of the prime mover is called an antagonist. Antagonists play two important roles in muscle function: (1) they maintain body or limb position, such as holding the arm out or standing erect; and (2) they control rapid movement, as in shadow boxing without landing a punch or the ability to check the motion of a limb.

Muscle Shapes and Patterns of Fascicle Organization

Skeletal muscle is enclosed in connective tissue scaffolding at three levels. Each muscle fiber (cell) is covered by **endomysium** and the entire muscle is covered by **epimysium**. When a group of muscle fibers is "bundled" as a unit within the whole muscle by an additional covering of a connective

tissue called perimysium, that bundled group of muscle fibers is called a fascicle. Fascicle arrangement by **perimysia** is correlated to the force generated by a muscle; it also affects the range of motion of the muscle. Based on the patterns of fascicle arrangement, skeletal muscles can be classified in several ways. What follows are the most common **fascicle** arrangements.

Parallel muscles have fascicles that are arranged in the same direction as the long axis of the muscle (Figure). The majority of skeletal muscles in the body have this type of organization. Some parallel muscles are flat sheets that expand at the ends to make broad attachments. Other parallel muscles are rotund with tendons at one or both ends. Muscles that seem to be plump have a large mass of tissue located in the middle of the muscle, between the insertion and the origin, which is known as the central body. A more common name for this muscle is **belly**. When a muscle contracts, the contractile fibers shorten it to an even larger bulge. For example, extend and then flex your biceps brachii muscle; the large, middle section is the belly (Figure). When a parallel muscle has a central, large belly that is spindle-shaped, meaning it tapers as it extends to its origin and insertion, it sometimes is called **fusiform**.

Muscle Shapes and Fiber Alignment

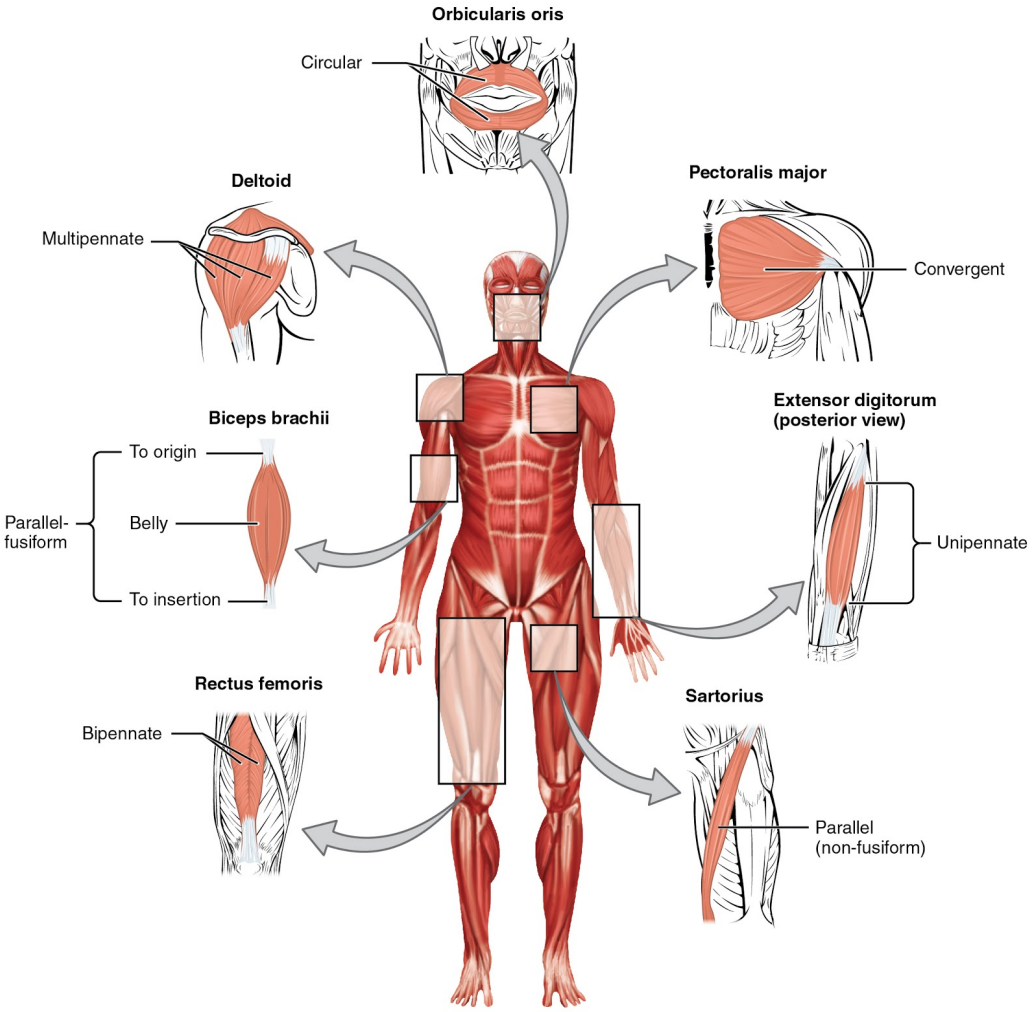

The skeletal muscles of the body typically come in seven different general shapes.

The large mass at the center of a muscle is called the belly. Tendons emerge from both ends of the belly and connect the muscle to the bones, allowing the skeleton to move. The tendons of the bicep connect to the upper arm and the forearm. (credit: Victoria Garcia)

Axial Muscles of the Head, Neck, and Back

The skeletal muscles are divided into **axial** (muscles of the trunk and head) and **appendicular** (muscles of the arms and legs) categories. This system reflects the bones of the skeleton system, which are also arranged in this manner. The axial muscles are grouped based on location, function, or both. Some of the axial muscles may seem to blur the boundaries because they cross over to the appendicular skeleton. The first grouping of the axial muscles you will review includes the muscles of the head and neck, then you will review the muscles of the vertebral column, and finally you will review the **oblique** and **rectus** muscles.

There are several small facial muscles, one of which is the **corrugator supercilii**, which is the prime mover of the eyebrows. Place your finger on your eyebrows at the point of the bridge of the nose. Raise your eyebrows as if you were surprised and lower your eyebrows as if you were frowning. With these movements, you can feel the action of the corrugator supercilli.

Muscles That Create Facial Expression

The origins of the muscles of facial expression are on the surface of the skull (remember, the origin of a muscle does not move). The insertions of these muscles have fibers intertwined with connective tissue and the dermis of the skin. Because the muscles insert in the skin rather than on bone, when they contract, the skin moves to create facial expression (Figure).

A large portion of the face is composed of the buccinator muscle, which compresses the cheek. This muscle allows you to whistle, blow, and suck; and it contributes to the action of chewing.

The insertions and origins of facial muscles are in the skin, so that certain individual muscles contract to form a smile or frown, form sounds or words, and raise the eyebrows.

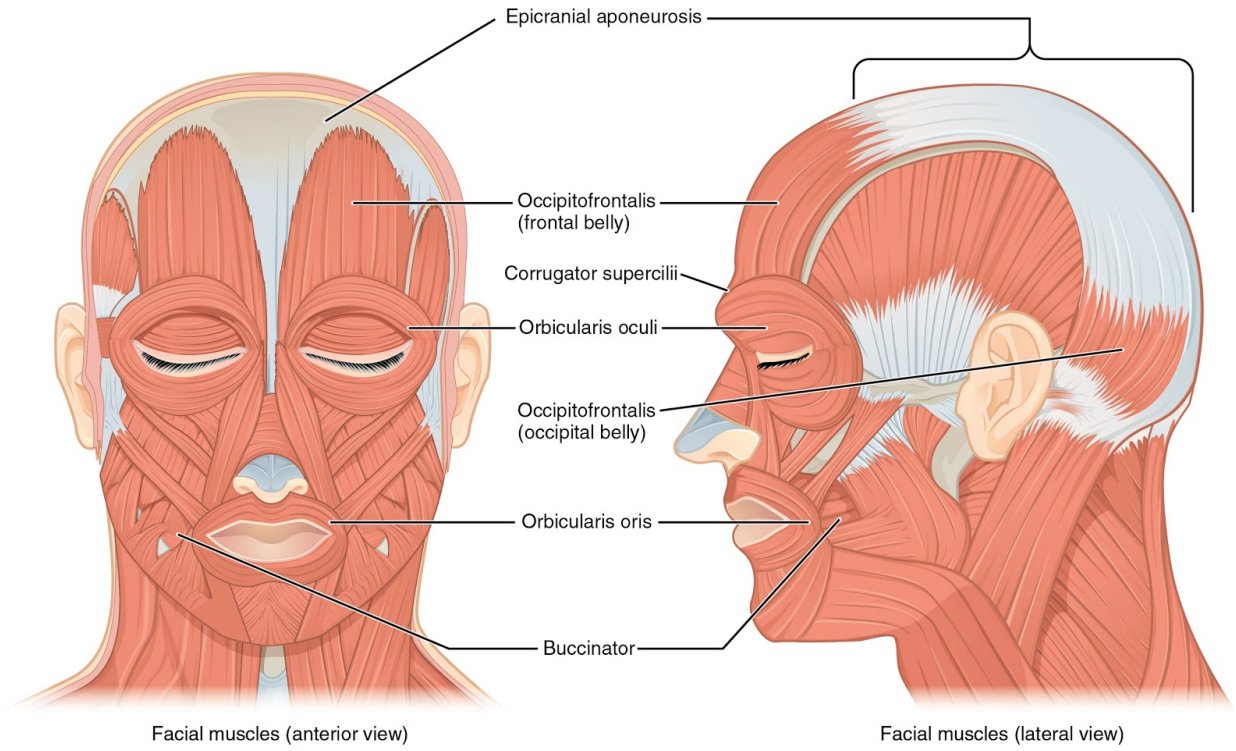

Many of the muscles of facial expression insert into the skin surrounding the eyelids, nose and mouth, producing facial expressions by moving the skin rather than bones.

The **orbicularis oris** is a circular muscle that moves the lips, and the **orbicularis oculi** is a circular muscle that closes the eye. The **occipitofrontalis** muscle moves up the scalp and eyebrows. The muscle has a frontal belly and an occipital (near the occipital bone on the posterior part of the skull) belly. In other words, there is a muscle on the forehead (frontalis) and one on the back of the head (occipitalis), but there is no muscle across the top of the head. Instead, the two bellies are connected by a broad tendon called the **epicranial aponeurosis**, or **galea aponeurosis** (galea = “apple”). The physicians originally studying human anatomy thought the skull looked like an apple.

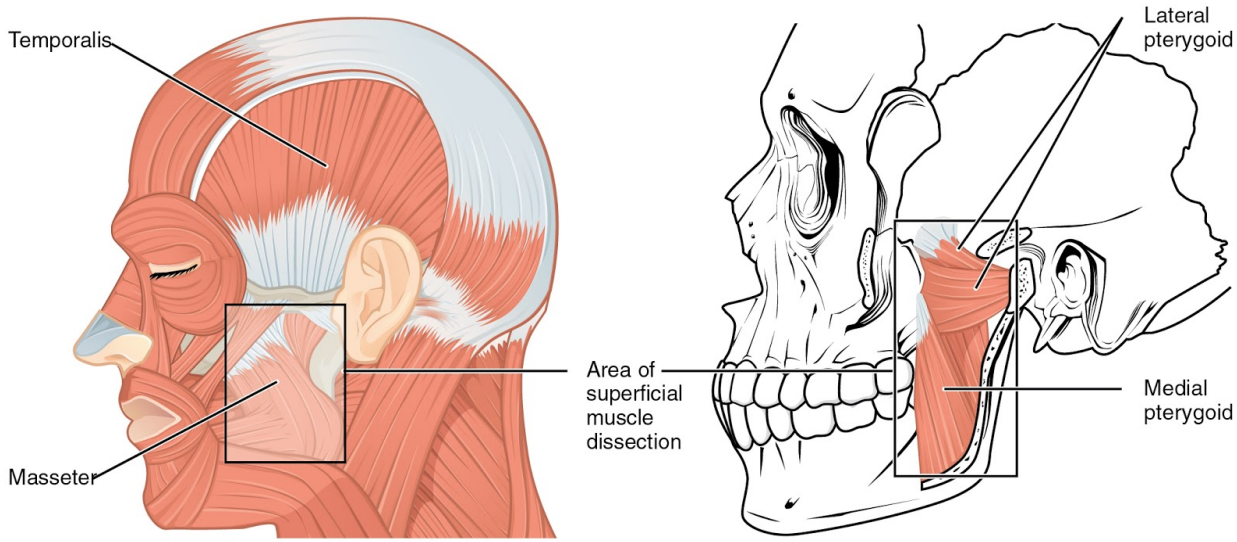

Chewing muscles (superficial) Chewing muscles (deep)

Muscles That Move the Eyes

The movement of the eyeball is under the control of the extrinsic eye muscles, which originate outside the eye and insert onto the outer surface of the white of the eye. These muscles are located inside the eye socket and cannot be seen on any part of the visible eyeball

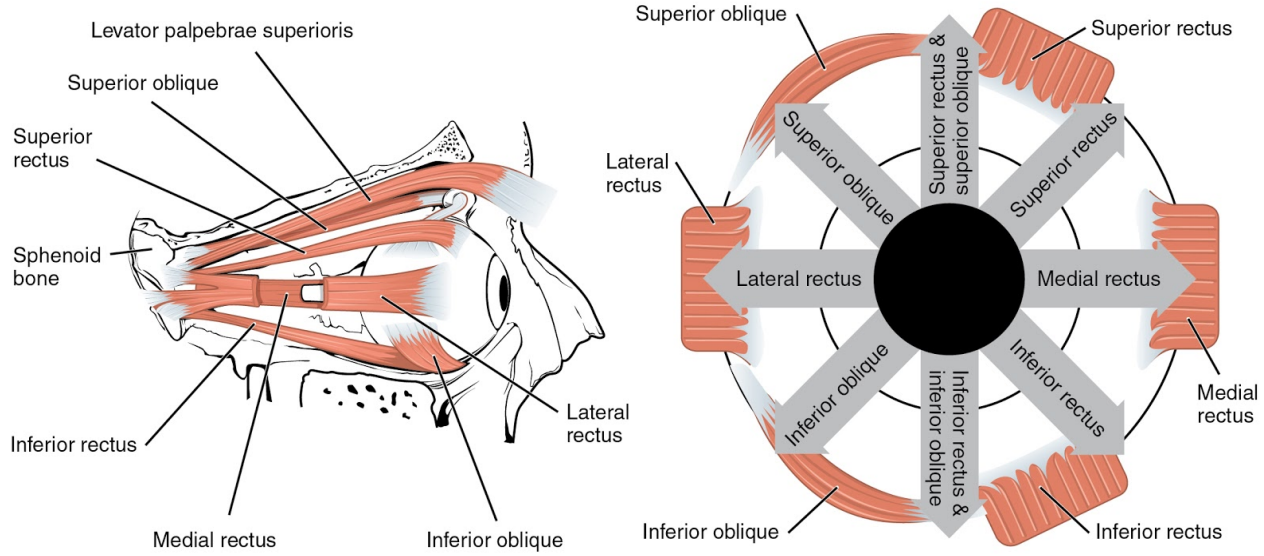

(a) Right eye (lateral view) (b) Right eye (anterior view)

Muscles That Move the Tongue

Although the tongue is obviously important for tasting food, it is also necessary for mastication, deglutition (swallowing), and speech (Figure and Figure). Because it is so moveable, the tongue facilitates complex speech patterns and sounds.

Muscles that Move the Tongue

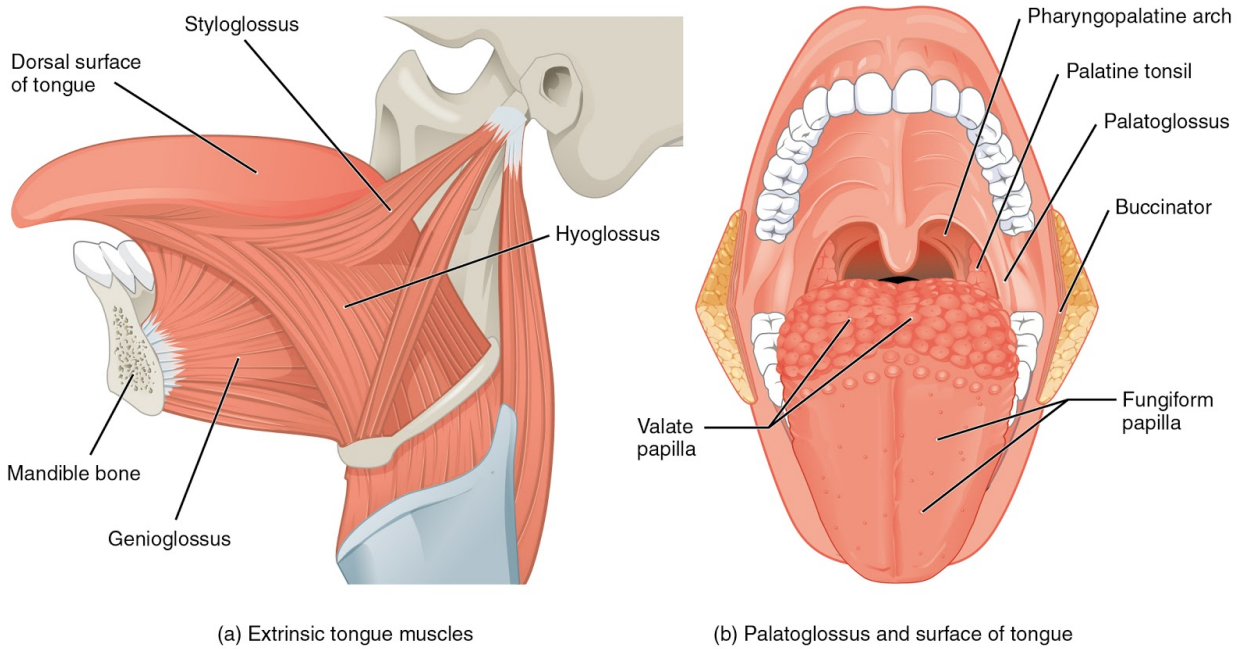

Muscles for Tongue Movement, Swallowing, and Speech

Muscles of the Anterior Neck

The muscles of the anterior neck assist in deglutition (swallowing) and speech by controlling the positions of the larynx (voice box), and the hyoid bone, a horseshoe-shaped bone that functions as a solid foundation on which the tongue can move. The muscles of the neck are categorized according to their position relative to the hyoid bone (Figure). Suprahyoid muscles are superior to it, and the infrahyoid muscles are located inferiorly.

Muscles of the Anterior Neck

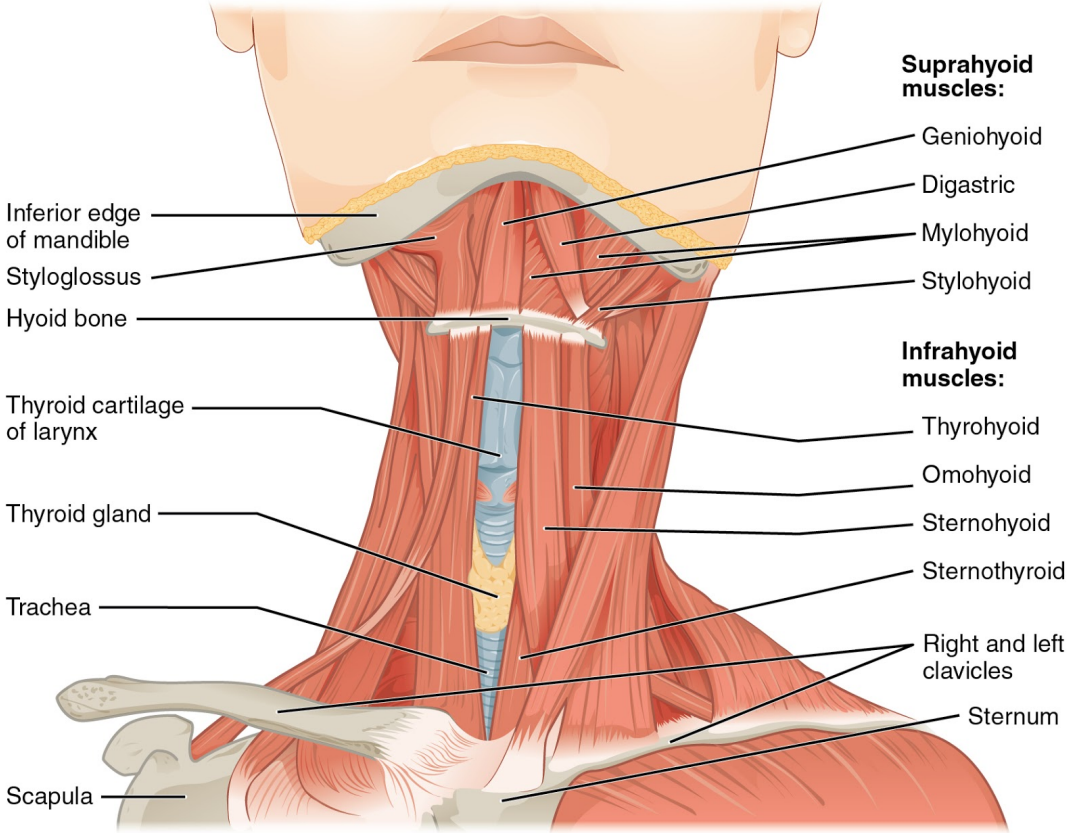

The anterior muscles of the neck facilitate swallowing and speech. The **suprahyoid** muscles originate from above the hyoid bone in the chin region. The **infrahyoid** muscles originate below the hyoid bone in the lower neck.

Posterior and Lateral Views of the Neck

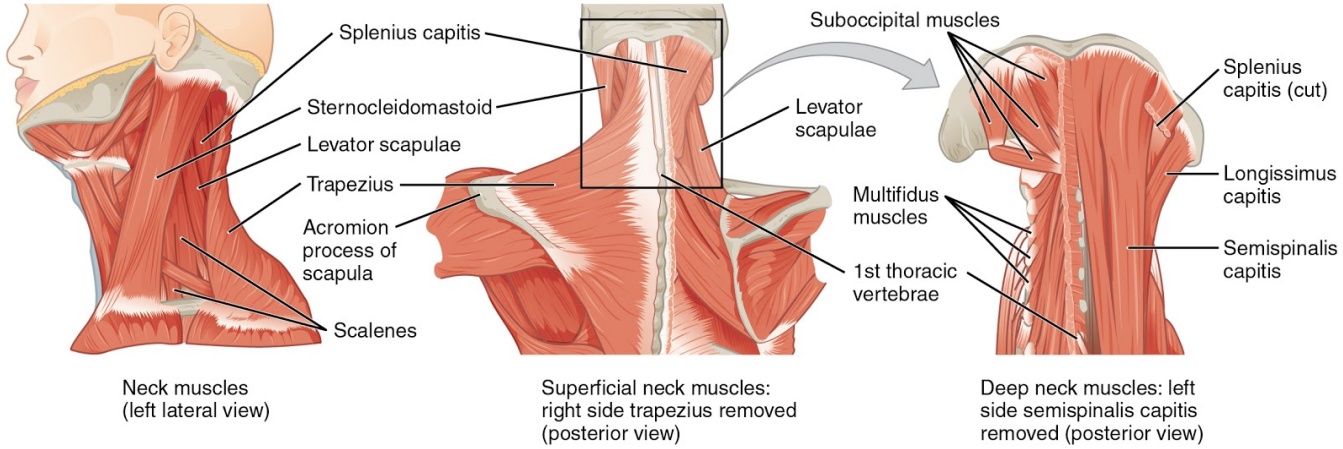

The superficial and deep muscles of the neck are responsible for moving the head, cervical vertebrae, and scapulas.

Muscles of the Posterior Neck and the Back

The posterior muscles of the neck are primarily concerned with head movements, like extension. The back muscles stabilize and move the vertebral column, and are grouped according to the lengths and direction of the fascicles.

The splenius muscles originate at the midline and run laterally and superiorly to their insertions. From the sides and the back of the neck, the splenius capitis inserts onto the head region, and the splenius cervicis extends onto the cervical region. These muscles can extend the head, laterally flex it, and rotate it (Figure).

The erector spinae group forms the majority of the muscle mass of the back and it is the primary extensor of the vertebral column. It controls flexion, lateral flexion, and rotation of the vertebral column, and maintains the lumbar curve. The erector spinae comprises the iliocostalis (laterally placed) group, the longissimus (intermediately placed) group, and the spinalis (medially placed) group.

Muscles of the Neck and Back

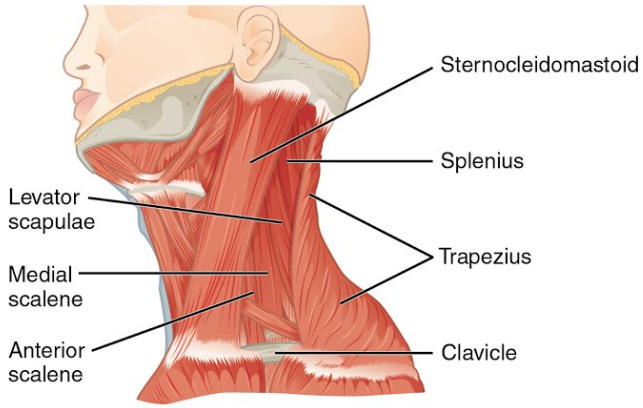

Muscles of the neck (left lateral view)

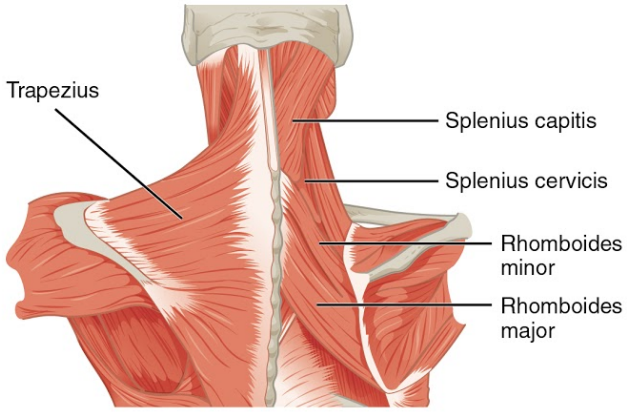

Superficial (left side) and deep (right side) muscles of the neck and upper back (posterior view)

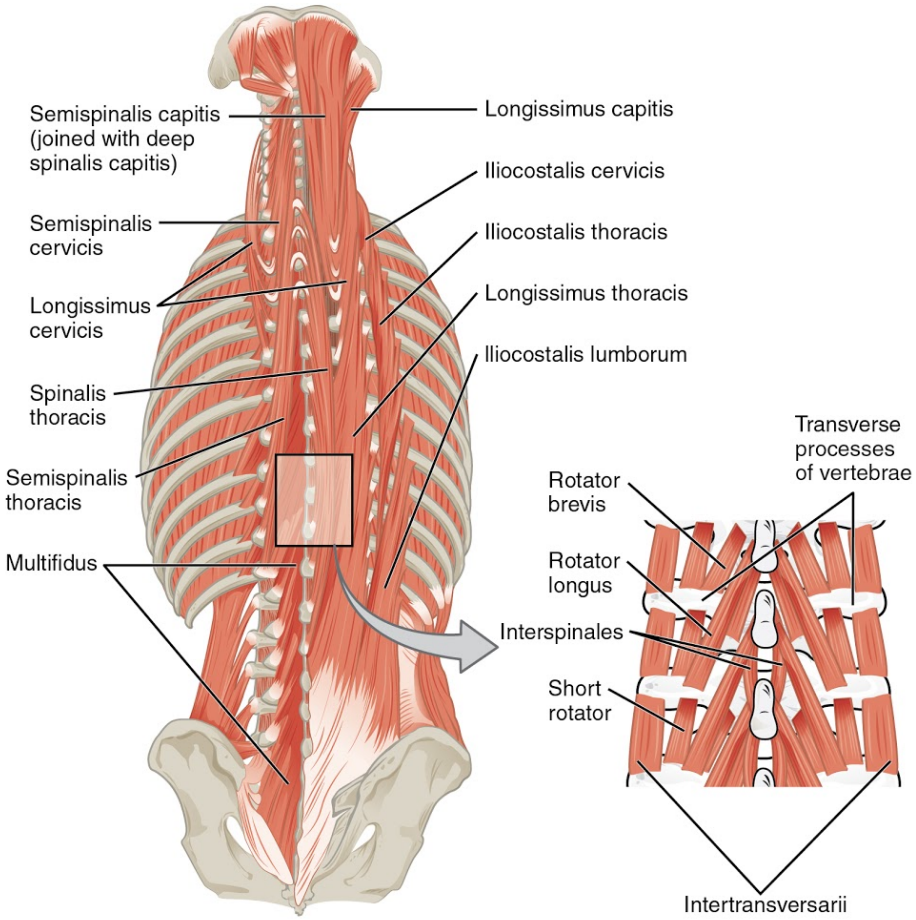

Deep muscles of the back (posterior view)

Deep spinal muscles (multifidus removed)

The large, complex muscles of the neck and back move the head, shoulders, and vertebral column.

Axial Muscles of the Abdominal Wall and Thorax

It is a complex job to balance the body on two feet and walk upright. The muscles of the vertebral column, thorax, and abdominal wall extend, flex, and stabilize different parts of the body's trunk. The

deep muscles of the core of the body help maintain posture as well as carry out other functions. The brain sends out electrical impulses to these various muscle groups to control posture by alternate contraction and relaxation. This is necessary so that no single muscle group becomes fatigued too quickly. If any one group fails to function, body posture will be compromised.

Muscles of the Abdomen

There are four pairs of abdominal muscles that cover the anterior and lateral abdominal region and meet at the anterior midline. These muscles of the anterolateral abdominal wall can be divided into four groups: the external obliques, the internal obliques, the transversus abdominis, and the rectus abdominis (Figure and Table).

The anterior abdominal muscles include the medially located rectus abdominis, which is covered by a sheet of connective tissue called the rectus sheath. On the flanks of the body, medial to the rectus abdominis, the abdominal wall is composed of three layers.

- ❑ The external oblique muscles form the superficial layer,
- ❑ The internal oblique muscles form the middle layer,
- ❑ The transverses abdominus forms the deepest layer.

The muscles of the lower back move the lumbar spine but also assist in femur movements. There are three flat skeletal muscles in the antero-lateral wall of the abdomen. The external oblique, closest to the surface, extend inferiorly and medially, in the direction of sliding one's four fingers into pants pockets. Perpendicular to it is the intermediate internal oblique, extending superiorly and medially, the direction the thumbs usually go when the other fingers are in the pants pocket. The deep muscle, the transversus abdominis, is arranged transversely around the abdomen, similar to the front of a belt on a pair of pants. This arrangement of three bands of muscles in different orientations allows various movements and rotations of the trunk. The three layers of muscle also help to protect the internal abdominal organs in an area where there is no bone.

Muscles of the Abdomen

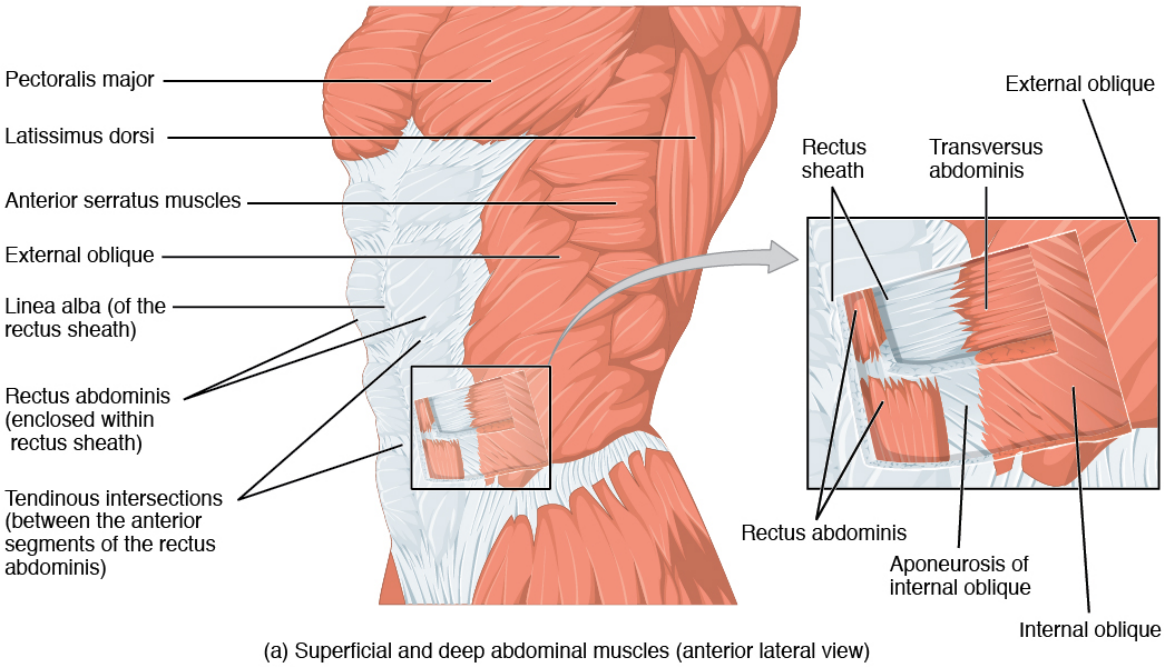

(a) Superficial and deep abdominal muscles (anterior lateral view)

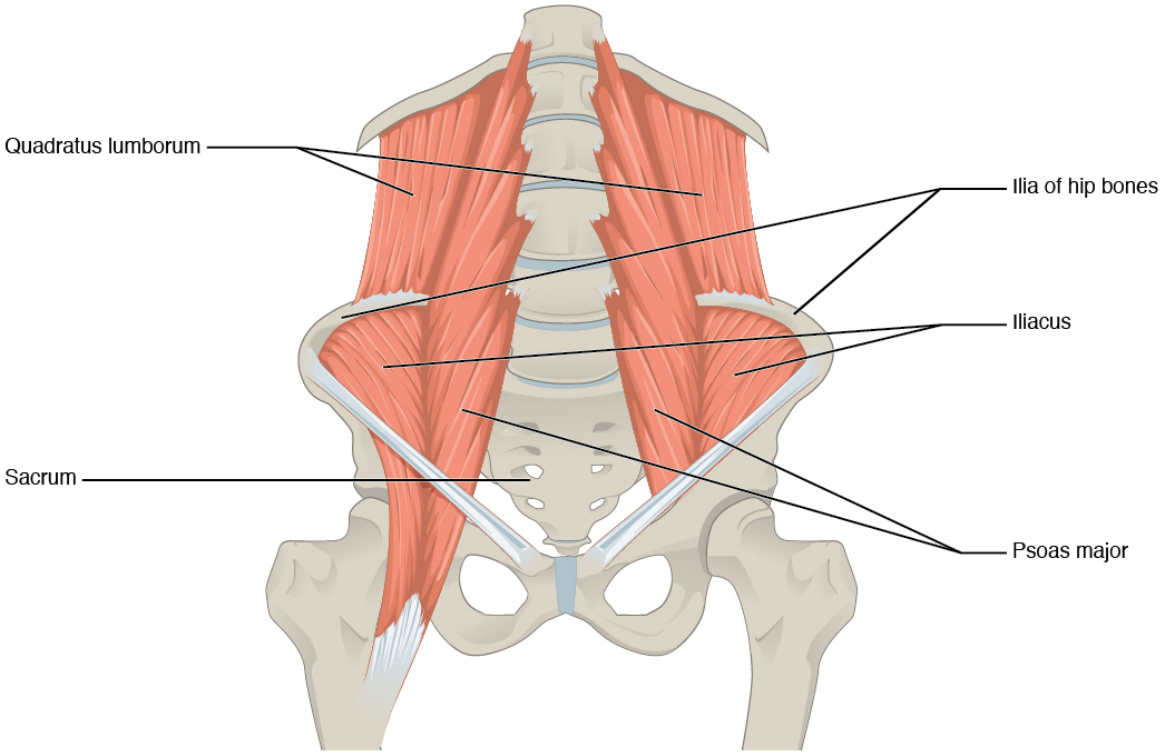

(b) Posterior abdominal muscles (anterior view)

The linea alba is a white, fibrous band that is made of the bilateral rectus sheaths that join at the anterior midline of the body. These enclose the rectus abdominis muscles (a pair of long, linear muscles, commonly called the "sit-up" muscles) that originate at the pubic crest and symphysis, and extend the length of the body's trunk. Each muscle is segmented by three transverse bands of collagen fibers called the tendinous intersections.

- This results in the look of "six-pack abs," as each segment hypertrophies on individuals at the gym who do many sit-ups.

The posterior abdominal wall is formed by the lumbar vertebrae, parts of the ilia of the hip bones, psoas major and iliacus muscles, and quadratus lumborum muscle. This part of the core plays a key role in stabilizing the rest of the body and maintaining posture.

Muscles of the Thorax

The muscles of the chest serve to facilitate breathing by changing the size of the thoracic cavity (Table). When you inhale, your chest rises because the cavity expands. Alternately, when you exhale, your chest falls because the thoracic cavity decreases in size.

The Diaphragm

The change in volume of the thoracic cavity during breathing is due to the alternate contraction and relaxation of the diaphragm(Figure). It separates the thoracic and abdominal cavities, and is dome-shaped at rest. The superior surface of the diaphragm is convex, creating the elevated floor of the thoracic cavity. The inferior surface is concave, creating the curved roof of the abdominal cavity.

- Defecating, urination, and even childbirth involve cooperation between the diaphragm and abdominal muscles (this cooperation is referred to as the "**Valsalva maneuver**"). You hold your breath by a steady contraction of the diaphragm; this stabilizes the volume and pressure of the peritoneal cavity.
- When the abdominal muscles contract, the pressure cannot push the diaphragm up, so it increases pressure on the intestinal tract (defecation), urinary tract (urination), or reproductive tract (childbirth).

Muscles of the Diaphragm

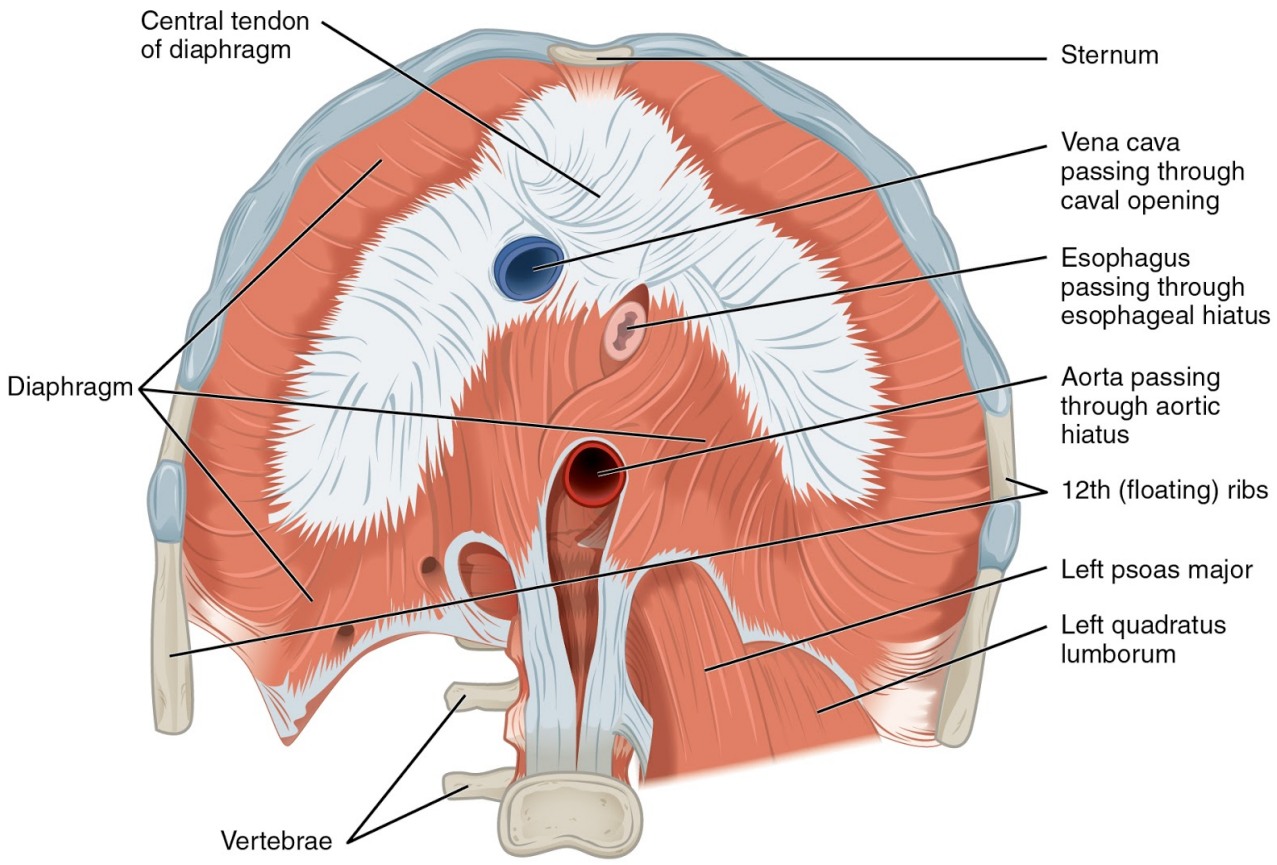

Diaphragm (inferior view)

The diaphragm has three openings for the passage of the inferior vena cava, the esophagus and the aorta.

The Intercostal Muscles

There are three sets of muscles, called intercostal muscles, which span each of the intercostal

spaces. The principal role of the intercostal muscles is to assist in breathing by changing the dimensions of the rib cage (Figure).

Intercostal Muscles

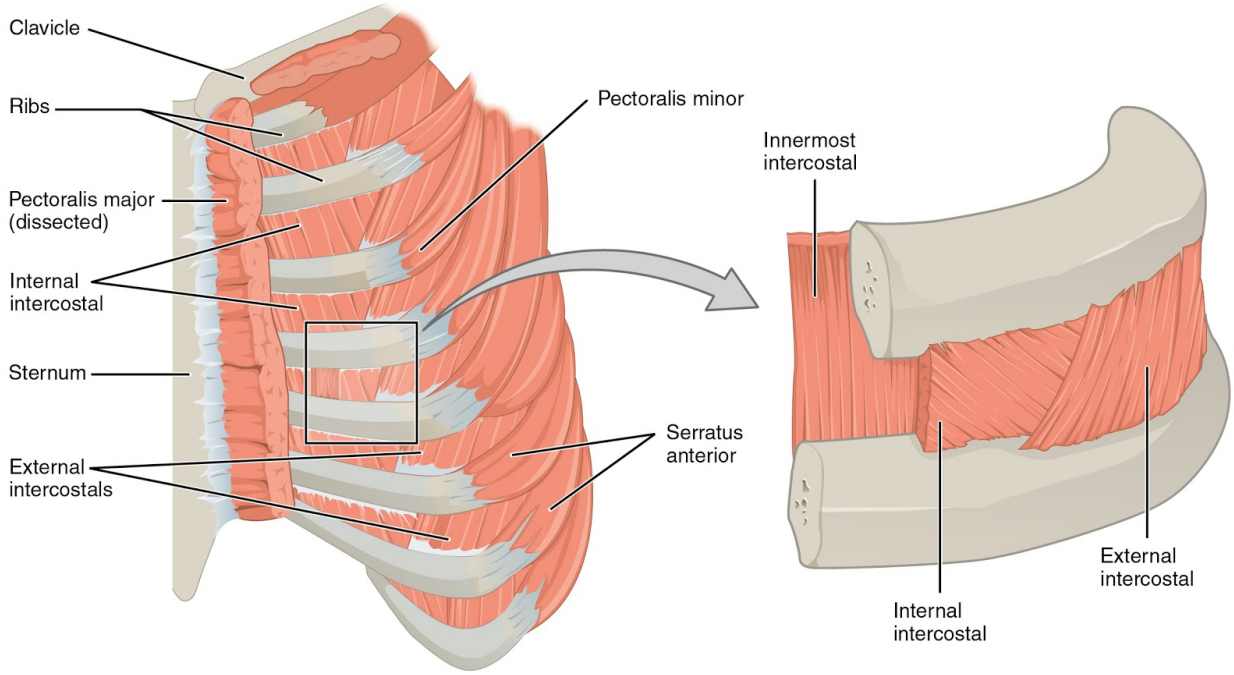

The 11 pairs of superficial external intercostal muscles aid in inspiration of air during breathing because when they contract, they raise the rib cage, which expands it. The 11 pairs of internal intercostal muscles, just under the externals, are used for expiration because they draw the ribs together to constrict the rib cage.

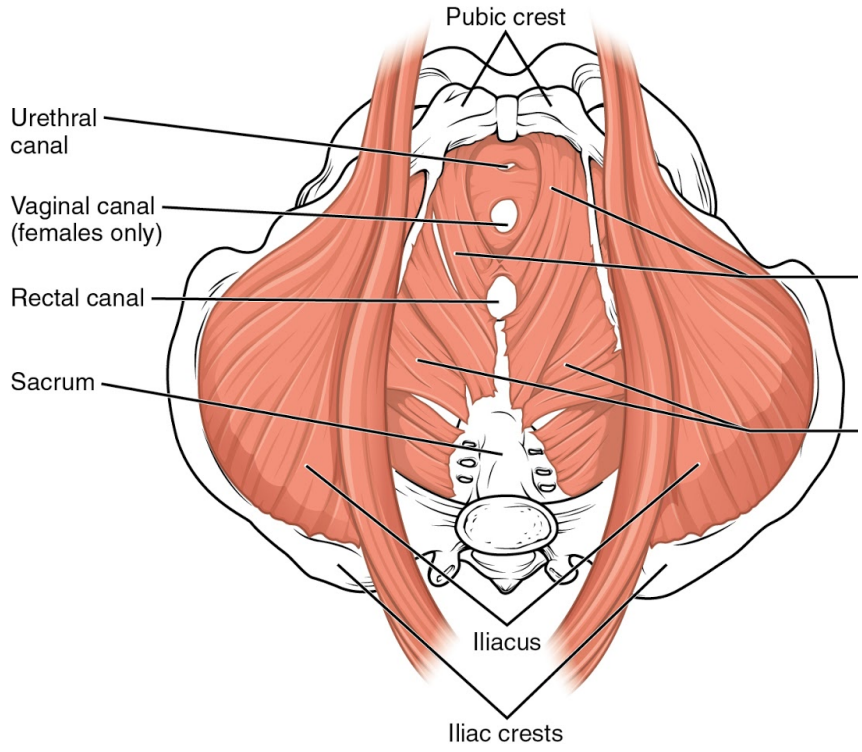

Muscles of the Pelvic Floor and Perineum

The pelvic floor is a muscular sheet that defines the inferior portion of the pelvic cavity. Its openings include the anal canal and urethra, and the vagina in women.

The large levator ani consists of two skeletal muscles, the pubococcygeus and the iliococcygeus (Figure). The levator ani is considered the most important muscle of the pelvic floor because it supports the pelvic

viscera. It resists the pressure produced by contraction of the abdominal muscles so that the pressure is applied to the colon to aid in defecation and to the uterus to aid in childbirth (assisted by the ischiococcygeus, which pulls the coccyx anteriorly). This muscle also creates skeletal muscle sphincters at the urethra and anus.

Muscles of the Pelvic Floor

The pelvic floor muscles support the pelvic organs, resist intra-abdominal pressure, and work as sphincters for the urethra, rectum, and vagina.

The perineum is the diamond-shaped space between the pubic symphysis (anteriorly), the coccyx (posteriorly), and the ischial tuberosities (laterally), lying just inferior to the pelvic diaphragm (levator ani and coccygeus). Divided transversely into triangles, the anterior is the urogenital triangle, which includes the external genitals. The posterior is the anal triangle, which contains the anus.

Muscles of the Perineum

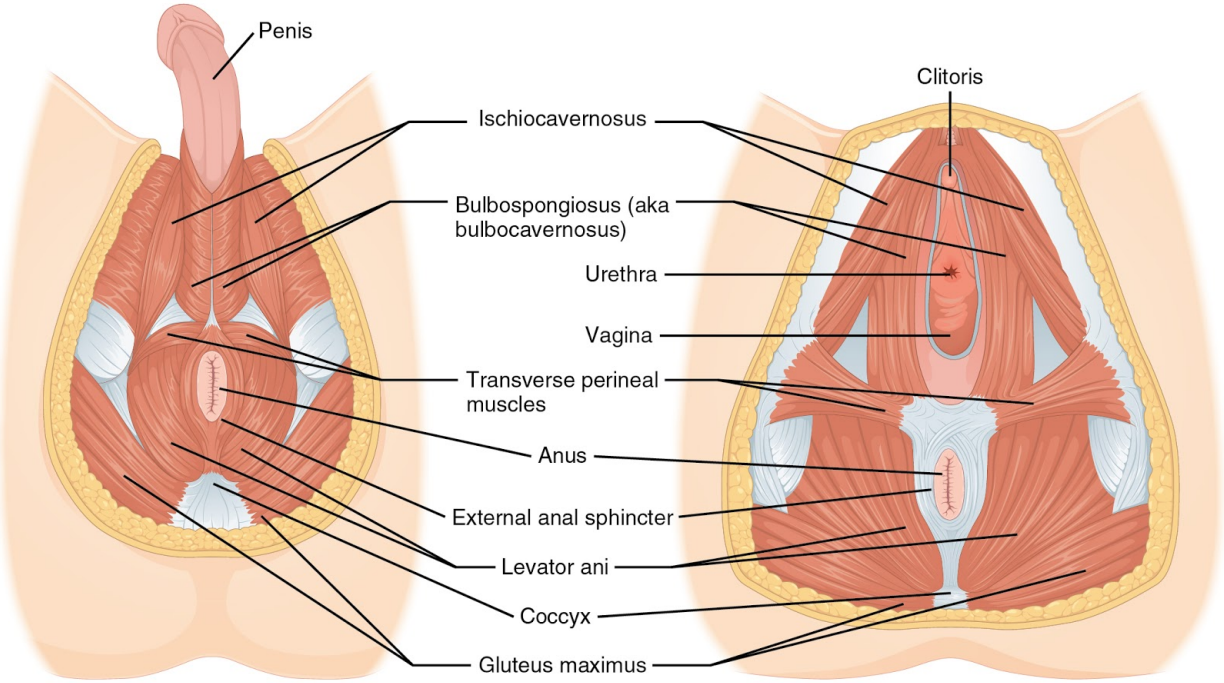

CAREER CONNECTIONS

Physical Therapists

Those who have a muscle or joint injury will most likely be sent to a physical therapist (PT) after seeing their regular doctor. PTs have a master's degree or doctorate, and are highly trained experts in the mechanics of body movements. Many PTs also specialize in sports injuries.

If you injured your shoulder while you were kayaking, the first thing a physical therapist would do during your first visit is to assess the functionality of the joint. The range of motion of a particular joint refers to the normal movements the joint performs. The PT will ask you to abduct and adduct, circumduct, and flex and extend the arm. The PT will note the shoulder's degree of function, and based

on the assessment of the injury, will create an appropriate physical therapy plan.
The first step in physical therapy will probably be applying a heat pack to the injured site, which acts much like a warm-up to draw blood to the area, to enhance healing. You will be instructed to do a series of exercises to continue the therapy at home, followed by icing, to decrease inflammation and swelling, which will continue for several weeks. When physical therapy is complete, the PT will do an exit exam and send a detailed report on the improved range of motion and return of normal limb function to your doctor. Gradually, as the injury heals, the shoulder will begin to function correctly. A PT works closely with patients to help them get back to their normal level of physical activity.

Muscles of the Pectoral Girdle and Upper Limbs

Muscles of the shoulder and upper limb can be divided into four groups: muscles that stabilize and position the **pectoral girdle**, muscles that move the arm, muscles that move the forearm, and muscles that move the wrists, hands, and fingers. The pectoral girdle, or shoulder girdle, consists of the lateral ends of the **clavicle** and **scapula**, along with the proximal end of the humerus, and the muscles covering these three bones to stabilize the shoulder joint. The girdle creates a base from which the head of the humerus, in its ball-and-socket joint with the glenoid fossa of the scapula, can move the arm in multiple directions.

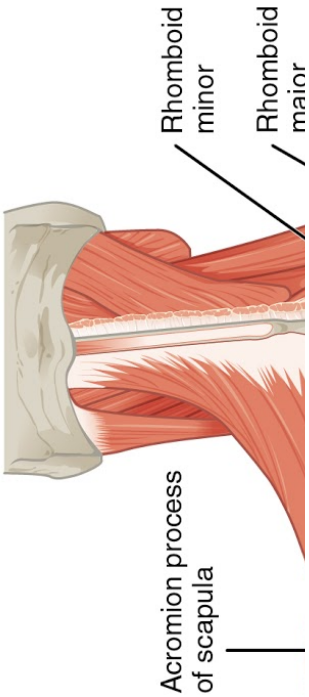

Muscles That Position the Pectoral Girdle

Muscles that position the pectoral girdle are located either on the anterior thorax or on the posterior thorax. The anterior muscles include the subclavius, pectoralis minor, and serratus anterior. The posterior muscles include the trapezius, rhomboid major, and rhomboid minor. When the rhomboids are contracted, your scapula moves medially, which can pull the shoulder and upper limb posteriorly.

The muscles that stabilize the pectoral girdle make it a steady base on which other muscles can move the arm. Note that the pectoralis major and deltoid, which move the humerus, are cut here to show the deeper positioning muscles.

Muscles That Move the Humerus

Similar to the muscles that position the pectoral girdle, muscles that cross the shoulder joint and move the humerus bone of the arm include both **axial** and **scapular muscles**. The two axial muscles are the **pectoralis major** and the **latissimus dorsi**. The pectoralis major is thick and fan-shaped, covering much of the superior portion of the **anterior thorax**.

Muscles That Move the Humerus

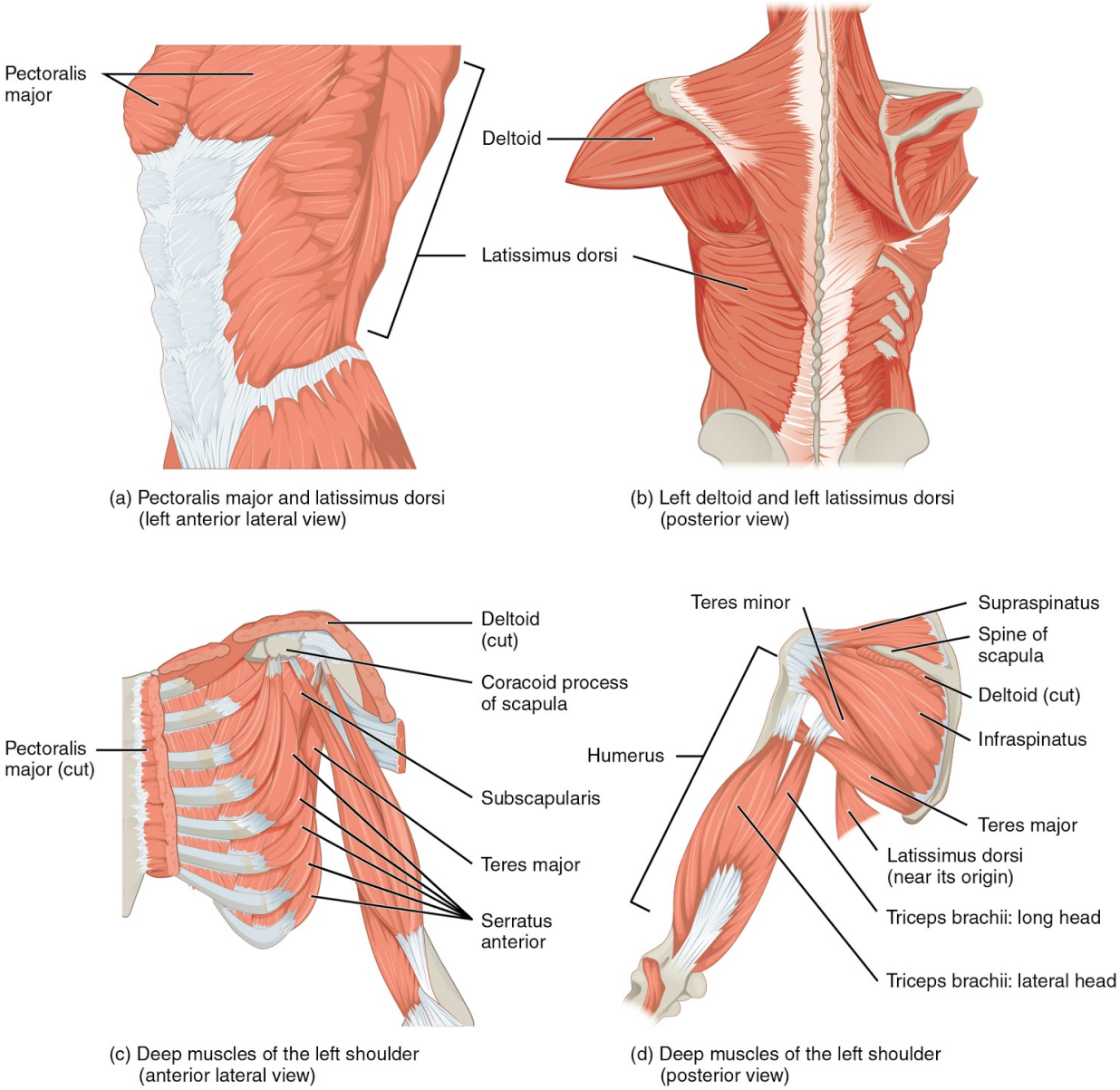

(a) Pectoralis major and latissimus dorsi (left anterior lateral view)

(b) Left deltoid and left latissimus dorsi (posterior view)

(c) Deep muscles of the left shoulder (anterior lateral view)

(d) Deep muscles of the left shoulder (posterior view)

Muscles That Move the Forearm

The forearm, made of the **radius** and **ulna bones**, has four main types of action at the hinge of the elbow joint: **flexion**, **extension**, **pronation**, and **supination**. The forearm **flexors** include

the **biceps brachii**, **brachialis**, and **brachioradialis**. The **extensors** are the **triceps brachii** and **anconeus**. The **pronators** are the **pronator teres** and the **pronator quadratus**, and the **supinator** is the only one that turns the forearm anteriorly.

Muscles That Move the Forearm

T

The muscles originating in the upper arm flex, extend, pronate, and supinate the forearm. The muscles originating in the forearm move the wrists, hands, and fingers.

Clinical Connection: Rotator Cuff Injury

The tendons of the deep subscapularis, supraspinatus, infraspinatus, and teres minor connect the scapula to the humerus, forming the rotator cuff (musculotendinous cuff), the circle of tendons around the shoulder joint. When baseball pitchers undergo shoulder surgery it is usually on the rotator cuff, which becomes pinched and inflamed, and may tear away from the bone due to the repetitive motion of bring the arm overhead to throw a fast pitch. However, rotator cuff injury can occur with any activity requiring repetitive motion that stresses the rotator cuff such as digging, climbing, paddling, or lifting and reaching..

Muscles That Move the Wrist, Hand, and Fingers

Wrist, hand, and finger movements are facilitated by two groups of muscles. The forearm is the origin of the extrinsic muscles of the hand. The palm is the origin of the intrinsic muscles of the hand.

Muscles of the Arm That Move the Wrists, Hands, and Fingers

The muscles in the anterior compartment of the forearm (anterior flexor compartment of the forearm) originate on the humerus and insert onto different parts of the hand. These make up the bulk of the forearm. From lateral to medial, the superficial anterior compartment of the forearm includes the flexor carpi radialis, palmaris longus, flexor carpi ulnaris, and flexor digitorum superficialis. The flexor digitorum superficialis flexes the hand as well as the digits at the knuckles, which allows for rapid finger movements, as in typing or playing a musical instrument. The deep anterior compartment The flexor pollicis longus and the flexor digitorum profundus produce flexion and bend fingers to make a fist.

Intrinsic Muscles of the Hand

The intrinsic muscles of the hand both originate and insert within it (Figure). These muscles allow your fingers to also make precise movements for actions, such as typing or writing. These muscles are divided into three groups. The thenar muscles are on the radial aspect of the palm. The hypothenar muscles are on

the medial aspect of the palm, and the intermediate muscles are midpalmar.

The thenar muscles include the abductor pollicis brevis, opponens pollicis, flexor pollicis brevis, and the adductor pollicis. These muscles form the thenar eminence, the rounded contour of the base of the thumb, and all act on the thumb. The movements of the thumb play an integral role in most precise movements of the hand.

The hypothenar muscles include the abductor digiti minimi, flexor digiti minimi brevis, and the opponens digiti minimi. These muscles form the hypothenar eminence, the rounded contour of the little finger, and as such, they all act on the little finger. Finally, the intermediate muscles act on all the fingers and include the lumbrical, the palmar interossei, and the dorsal interossei.

Intrinsic Muscles of the Hand

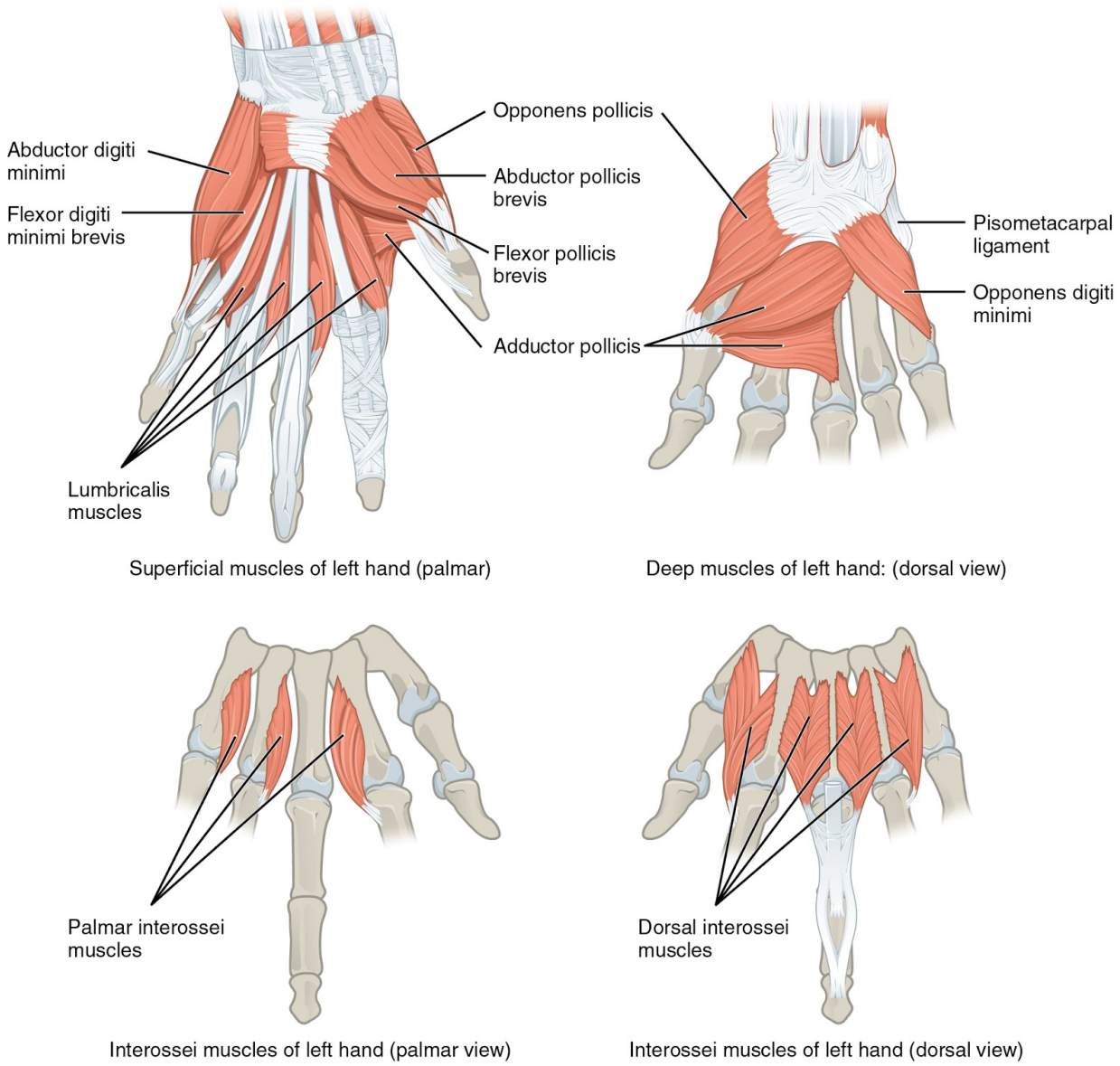

Superficial muscles of left hand (palmar)

Deep muscles of left hand: (dorsal view)

Interossei muscles of left hand (palmar view)

Interossei muscles of left hand (dorsal view)

Appendicular Muscles of the Pelvic Girdle and Lower Limbs

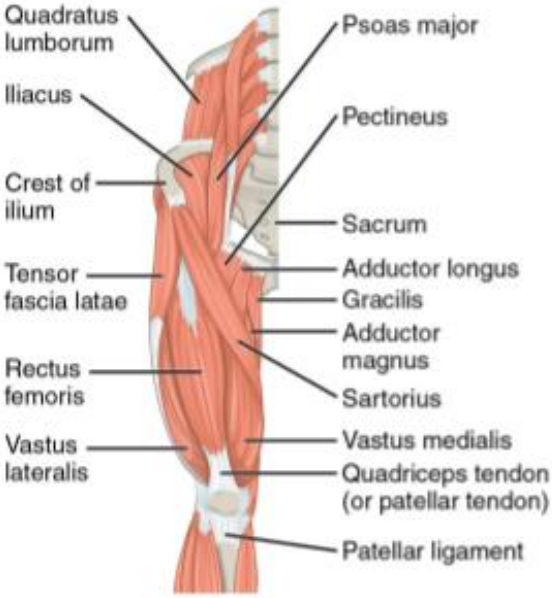

Superficial pelvic and thigh muscles of right leg (anterior view)

Gluteal Region Muscles That Move the Femur

Most muscles that insert on the femur (the thigh bone) and move it, originate on the pelvic girdle. The psoas major and iliacus make up the iliopsoas group. Some of the largest and most powerful muscles in the body are the gluteal muscles or gluteal group. The gluteus maximus is the largest; deep to the gluteus maximus is the gluteus medius, and deep to the gluteus medius is the gluteus minimus, the smallest of the trio

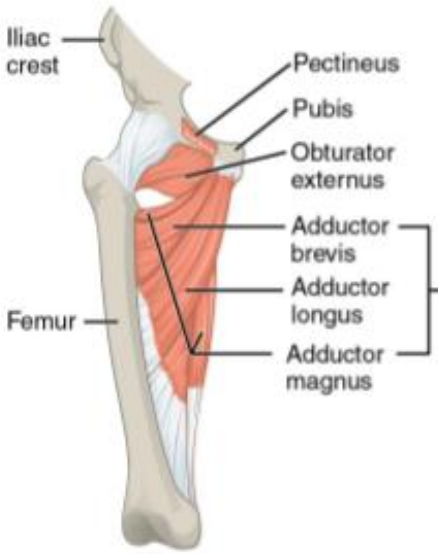

Deep pelvic and thigh muscles of right leg (anterior view)

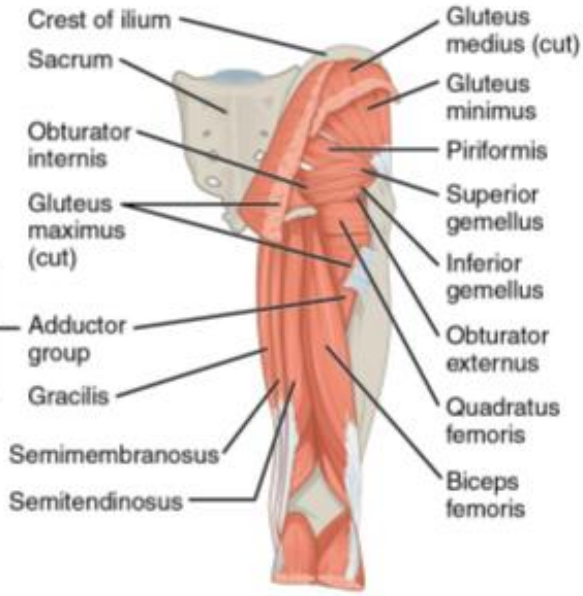

Pelvic and thigh muscles of right leg (posterior view)

Muscles of the Thigh

The adductor longus, adductor brevis, and adductor magnus can both medially and laterally rotate the thigh depending on the placement of the foot. The adductor longus flexes the thigh, whereas the adductor magnus extends it. The pectineus adducts and flexes the femur at the hip as well. The pectineus is located in the femoral triangle, which is formed at the junction between the hip and the leg and also includes the femoral nerve, the femoral artery, the femoral vein, and the deep inguinal lymph nodes.

Thigh Muscles That Move the Femur, Tibia, and Fibula

Deep fascia in the thigh separates it into medial, anterior, and posterior compartments (see Figure and Figure). The muscles in the medial compartment of the thigh are responsible for adducting the femur at the hip. Along with the adductor longus, adductor brevis, adductor magnus, and pectineus, the strap-like gracilis adducts the thigh in addition to flexing the leg at the knee. extend and stabilize the knee.

The rectus femoris is on the anterior aspect of the thigh, the vastus lateralis is on the lateral aspect of the thigh, the vastus medialis is on the medial aspect of the thigh, and the vastus intermedius is between the vastus lateralis and vastus medialis and deep to the rectus femoris. The tendon common to all four is the quadriceps tendon (patellar tendon), which inserts into the patella and continues below it as the patellar ligament. The patellar ligament attaches to the tibial tuberosity. In addition to the quadriceps femoris, the sartorius is a band-like muscle that extends from the anterior superior iliac spine to the medial side of the proximal tibia. This versatile muscle flexes the leg at the knee and flexes, abducts, and laterally rotates the leg at the hip. This muscle allows us to sit cross-legged.

The posterior compartment of the thigh includes muscles that flex the leg and extend the thigh. The three long muscles on the back of the knee are the hamstring group, which flexes the knee. These are the biceps femoris, semitendinosus, and semimembranosus. The tendons of these muscles form the popliteal fossa, the diamond-shaped space at the back of the knee.

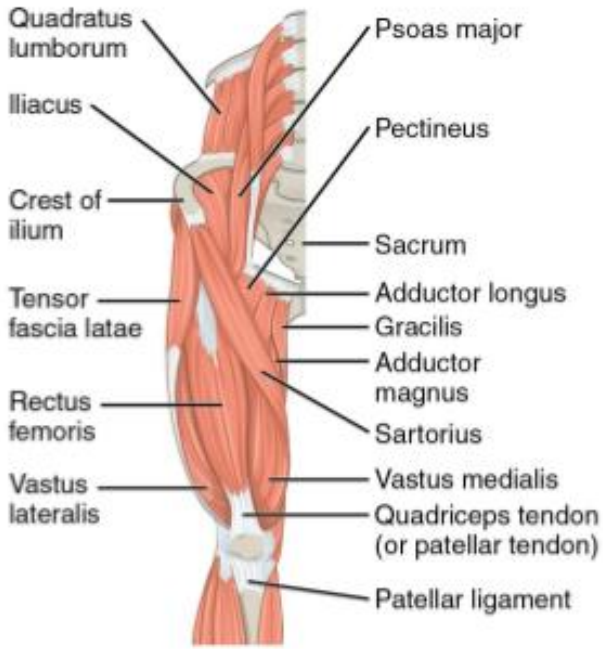

Superficial pelvic and thigh muscles of right leg (anterior view)

What would happen if the pelvic girdle, which attaches the lower limbs to the torso, were capable of the same range of motion as the pectoral girdle? For one thing, walking would expend more energy if the heads of the femurs were not secured in the acetabula of the pelvis. The body's center of gravity is in the area of the pelvis. If the center of gravity were not to remain fixed, standing up would be difficult as well. Therefore, what the leg muscles lack in range of motion and versatility, they make up for in size and power, facilitating the body's stabilization, posture, and movement.

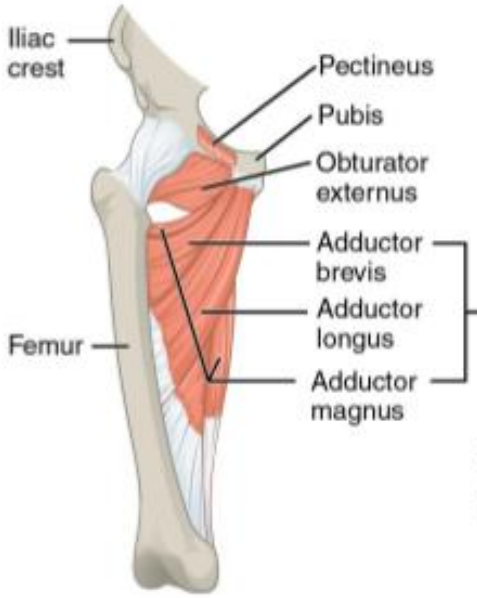

Deep pelvic and thigh muscles of right leg (anterior view)

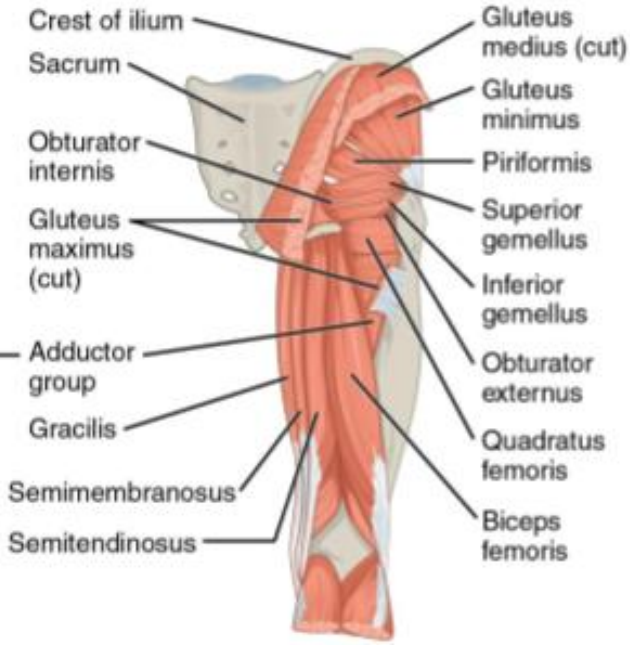

Pelvic and thigh muscles of right leg (posterior view)

The muscles of the anterior compartment of the thigh flex the thigh and extend the leg. This compartment contains the quadriceps femoris group, which actually comprises four muscles that

Muscles That Move the Feet and Toes

Similar to the thigh muscles, the muscles of the leg are divided by deep fascia into compartments, although the leg has three: anterior, lateral, and posterior.

Muscles of the Lower Leg

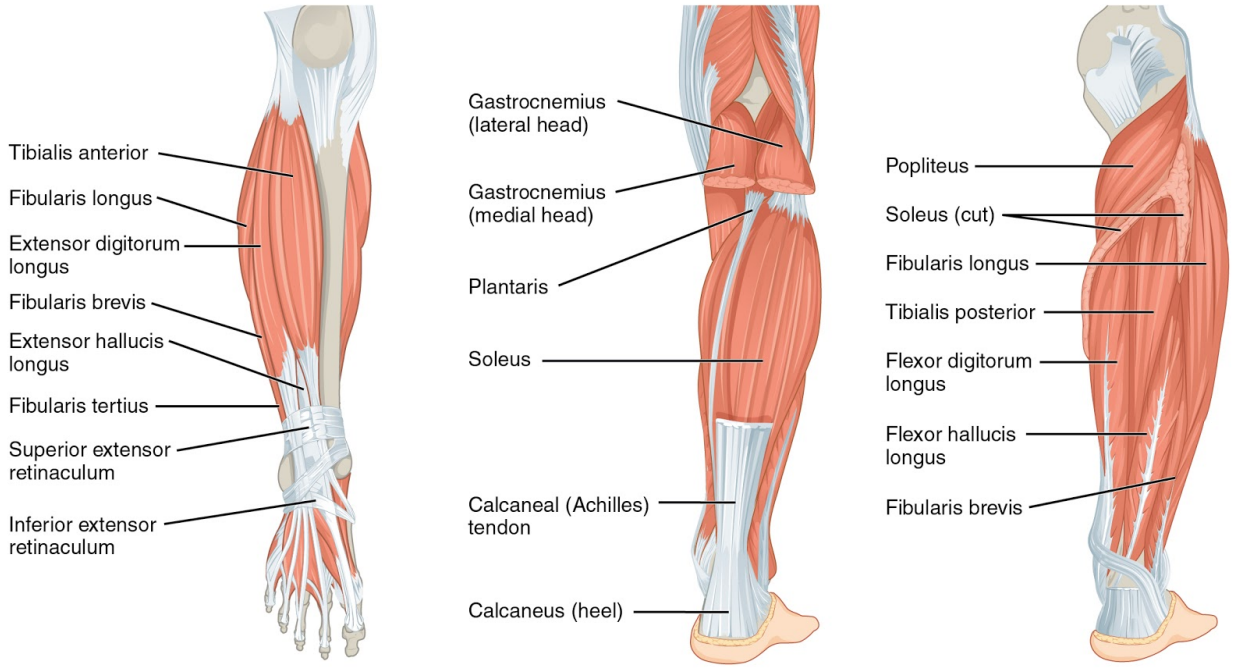

Superficial muscles of the right lower leg (anterior view) | Superficial muscles of the right lower leg (posterior view) | Deep muscles of the right lower leg (posterior view)

The muscles of the anterior compartment of the lower leg are generally responsible for dorsiflexion, and the muscles of the posterior compartment of the lower leg are generally responsible for plantar flexion. The lateral and medial muscles in both compartments invert, evert, and rotate the foot.

The muscles in the anterior compartment of the leg: the tibialis anterior, a long and thick muscle on the lateral surface of the tibia, the extensor hallucis longus, deep under it, and the extensor digitorum longus, lateral to it, all contribute to raising the front of the foot when they contract. The fibularis tertius, a small muscle that originates on the anterior surface of the fibula, is associated with the extensor digitorum longus and sometimes fused to it, but is not present in all people. Thick bands of connective tissue called the superior extensor retinaculum (transverse ligament of the ankle) and the inferior extensor retinaculum, hold the tendons of these muscles in place during dorsiflexion.

The lateral compartment of the leg includes two muscles: the fibularis longus (peroneus longus) and the fibularis brevis(peroneus brevis). The superficial muscles in the posterior compartment of the leg all insert onto the calcaneal tendon (Achilles tendon), a strong tendon that inserts into the calcaneal bone of the ankle. The muscles in this compartment are large and strong and keep humans upright. The most superficial and visible muscle of the calf is the gastrocnemius. Deep to the gastrocnemius is the wide, flat

soleus. The plantaris runs obliquely between the two; some people may have two of these muscles, whereas no plantaris is observed in about seven percent of other cadaver dissections. The plantaris tendon is a desirable substitute for the fascia lata in hernia repair, tendon transplants, and repair of ligaments. There are four deep muscles in the posterior compartment of the leg as well: the popliteus, flexor digitorum longus, flexor hallucis longus, and tibialis posterior.

Intrinsic Muscles of the Foot

The principal support for the longitudinal arch of the foot is a deep fascia called plantar aponeurosis, which runs from the calcaneus bone to the toes (inflammation of this tissue is the cause of "plantar fasciitis," which can affect runners.

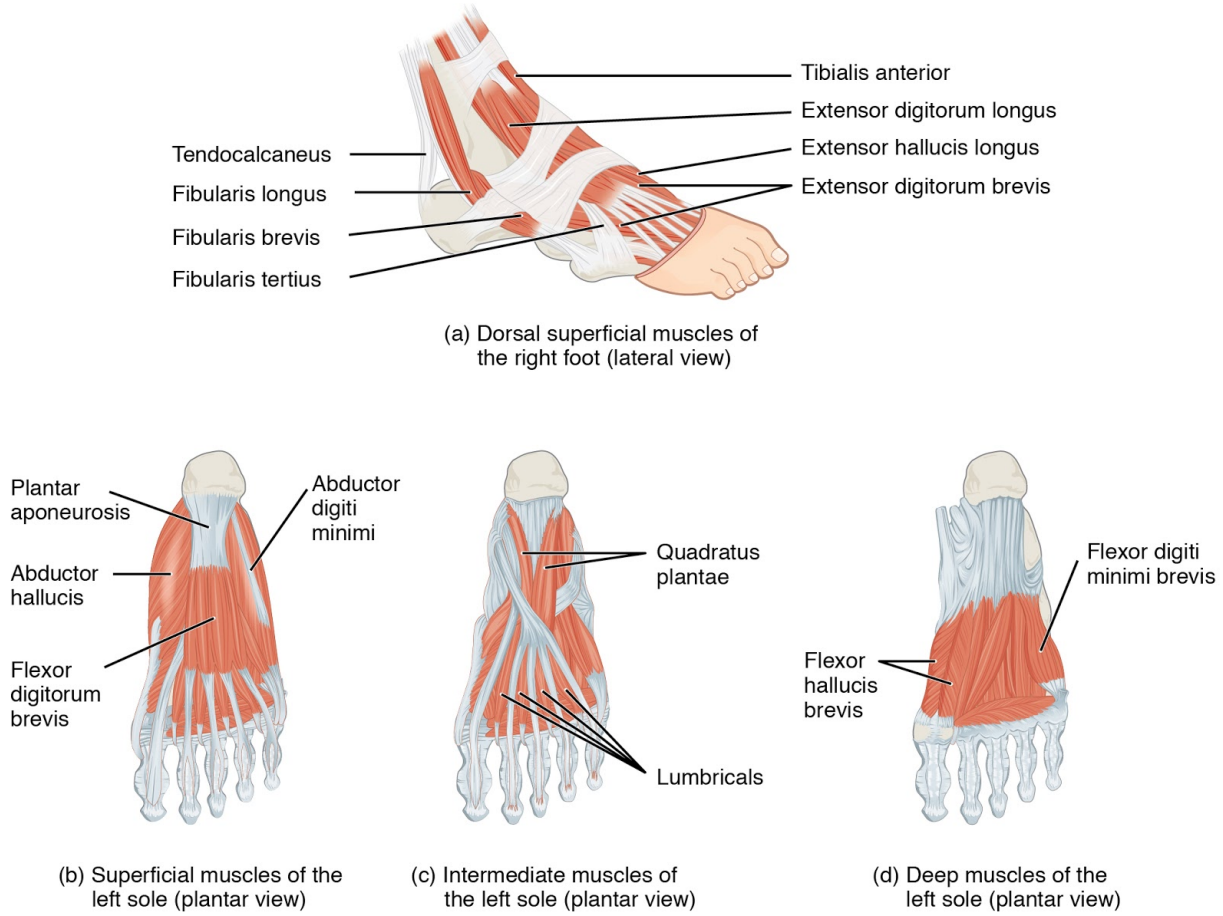

The muscles along the dorsal side of the foot (a) generally extend the toes while the muscles of the plantar side of the foot (b, c, d) generally flex the toes. The plantar muscles exist in three layers, providing the foot the strength to counterbalance the weight of the body. In this diagram, these three layers are shown from a plantar view beginning with the bottom-most layer just under the plantar skin of the foot (b) and ending with the top-most layer (d) located just inferior to the foot and toe bones.

Glossary

General Muscular System Terms

abduct: move away from midline in the sagittal plane

agonist: (also, prime mover) muscle whose contraction is responsible for producing a particular motion

antagonist: muscle that opposes the action of an agonist

belly: bulky central body of a muscle

bipennate: pennate muscle that has fascicles that are located on both sides of the tendon

circular: (also, sphincter) fascicles that are concentrically arranged around an opening

convergent: fascicles that extend over a broad area and converge on a common attachment site

fascicle; muscle fibers bundled by perimysium into a unit

fixator: synergist that assists an agonist by preventing or reducing movement at another joint, thereby stabilizing the origin of the agonist

flexion: movement that decreases the angle of a joint

fusiform: muscle that has fascicles that are spindle-shaped to create large bellies

insertion: end of a skeletal muscle that is attached to the structure (usually a bone) that is moved when the muscle contracts

multipennate: pennate muscle that has a tendon branching within it

origin: end of a skeletal muscle that is attached to another structure (usually a bone) in a fixed position

parallel: fascicles that extend in the same direction as the long axis of the muscle

pennate: fascicles that are arranged differently based on their angles to the tendon

prime mover: (also, agonist) principle muscle involved in an action

synergist: muscle whose contraction helps a prime mover in an action

unipennate: pennate muscle that has fascicles located on one side of the tendon

Axial Head, Face, Neck, and Back Muscles

anterior scalene: a muscle anterior to the middle scalene

appendicular: of the arms and legs

axial: of the trunk and head

buccinator: muscle that compresses the cheek

corrugator supercilii: prime mover of the eyebrows

deglutition: swallowing

digastric: muscle that has anterior and posterior bellies and elevates the hyoid bone and larynx when one swallows; it also depresses the mandible

epicranial aponeurosis: (also, **galea aponeurosis**) flat broad tendon that connects the frontalis and occipitalis

erector spinae group: large muscle mass of the back; primary extensor of the vertebral column

extrinsic eye muscles: originate outside the eye and insert onto the outer surface of the white of the eye, and create eyeball movement

frontalis: front part of the occipitofrontalis muscle

genioglossus: muscle that originates on the mandible and allows the tongue to move downward and forward

geniohyoid: muscle that depresses the mandible, and raises and pulls the hyoid bone anteriorly

hyoglossus: muscle that originates on the hyoid bone to move the tongue downward and flatten it

iliocostalis cervicis: muscle of the iliocostalis group associated with the cervical region

iliocostalis group: laterally placed muscles of the erector spinae

iliocostalis lumborum: muscle of the iliocostalis group associated with the lumbar region

iliocostalis thoracis: muscle of the iliocostalis group associated with the thoracic region

infrahyoid muscles: anterior neck muscles that are attached to, and inferior to the hyoid bone

lateral pterygoid: muscle that moves the mandible from side to side

longissimus capitis: muscle of the longissimus group associated with the head region

longissimus cervicis: muscle of the longissimus group associated with the cervical region

longissimus group: intermediately placed muscles of the erector spinae

longissimus thoracis: muscle of the longissimus group associated with the thoracic region

masseter: main muscle for chewing that elevates the mandible to close the mouth

mastication: chewing

medial pterygoid: muscle that moves the mandible from side to side

middle scalene: longest scalene muscle, located between the anterior and posterior scalenes

multifidus: muscle of the lumbar region that helps extend and laterally flex the vertebral column

mylohyoid: muscle that lifts the hyoid bone and helps press the tongue to the top of the mouth

occipitalis: posterior part of the occipitofrontalis muscle

occipitofrontalis: muscle that makes up the scalp with a frontal belly and an occipital belly

omohyoid: muscle that has superior and inferior bellies and depresses the hyoid bone

orbicularis oculi: circular muscle that closes the eye

orbicularis oris: circular muscle that moves the lips

palatoglossus: muscle that originates on the soft palate to elevate the back of the tongue

posterior scalene: smallest scalene muscle, located posterior to the middle scalene

scalene muscles: flex, laterally flex, and rotate the head; contribute to deep inhalation

segmental muscle group: interspinales and intertransversarii muscles that bring together the spinous and transverse processes of each consecutive vertebra

semispinalis capitis: transversospinales muscle associated with the head region

semispinalis cervicis: transversospinales muscle associated with the cervical region

semispinalis thoracis: transversospinales muscle associated with the thoracic region

spinalis capitis: muscle of the spinalis group associated with the head region

spinalis cervicis: muscle of the spinalis group associated with the cervical region

spinalis group: medially placed muscles of the erector spinae

spinalis thoracis: muscle of the spinalis group associated with the thoracic region

splenius: posterior neck muscles; includes the splenius capitis and splenius cervicis

splenius capitis: neck muscle that inserts into the head region

splenius cervicis: neck muscle that inserts into the cervical region

sternocleidomastoid: major muscle that laterally flexes and rotates the head

sternohyoid: muscle that depresses the hyoid bone

sternothyroid: muscle that depresses the larynx's thyroid cartilage

styloglossus: muscle that originates on the styloid bone, and allows upward and backward motion of the tongue

stylohyoid: muscle that elevates the hyoid bone posteriorly

suprahyoid muscles: neck muscles that are superior to the hyoid bone

temporalis: muscle that retracts the mandible

thyrohyoid: muscle that depresses the hyoid bone and elevates the larynx's thyroid cartilage

transversospinales: muscles that originate at the transverse processes and insert at the spinous processes of the vertebrae

Upper Appendicular Muscles: Shoulders, arms, and Hands

abductor digiti minimi: muscle that abducts the little finger

adductor pollicis: muscle that adducts the thumb

abductor pollicis brevis: muscle that abducts the thumb

abductor pollicis longus: muscle that inserts into the first metacarpal

anconeus: small muscle on the lateral posterior elbow that extends the forearm

anterior compartment of the arm: (anterior flexor compartment of the arm) the biceps brachii, brachialis, brachioradialis, and their associated blood vessels and nerves

anterior compartment of the forearm: (anterior flexor compartment of the forearm) deep and superficial muscles that originate on the humerus and insert into the hand

biceps brachii: two-headed muscle that crosses the shoulder and elbow joints to flex the forearm while assisting in supinating it and flexing the arm at the shoulder

brachialis: muscle deep to the biceps brachii that provides power in flexing the forearm.

brachioradialis: muscle that can flex the forearm quickly or help lift a load slowly

coracobrachialis: muscle that flexes and adducts the arm

deep anterior compartment: flexor pollicis longus, flexor digitorum profundus, and their associated blood vessels and nerves

deep posterior compartment of the forearm: (deep posterior extensor compartment of the forearm) the abductor pollicis longus, extensor pollicis brevis, extensor pollicis longus, extensor indicis, and their associated blood vessels and nerves

deltoid: shoulder muscle that abducts the arm as well as flexes and medially rotates it, and extends and laterally rotates it

dorsal interossei: muscles that abduct and flex the three middle fingers at the metacarpophalangeal joints

and extend them at the interphalangeal joints

extensor carpi radialis brevis: muscle that extends and abducts the hand at the wrist

extensor carpi ulnaris: muscle that extends and adducts the hand

extensor digiti minimi: muscle that extends the little finger

extensor digitorum: muscle that extends the hand at the wrist and the phalanges

extensor indicis: muscle that inserts onto the tendon of the extensor digitorum of the index finger

extensor pollicis brevis: muscle that inserts onto the base of the proximal phalanx of the thumb

extensor pollicis longus: muscle that inserts onto the base of the distal phalanx of the thumb

extensor radialis longus: muscle that extends and abducts the hand at the wrist

extensor retinaculum: band of connective tissue that extends over the dorsal surface of the hand

extrinsic muscles of the hand: muscles that move the wrists, hands, and fingers and originate on the arm

flexor carpi radialis: muscle that flexes and abducts the hand at the wrist

flexor carpi ulnaris: muscle that flexes and adducts the hand at the wrist

flexor digiti minimi brevis: muscle that flexes the little finger

flexor digitorum profundus: muscle that flexes the phalanges of the fingers and the hand at the wrist

flexor digitorum superficialis: muscle that flexes the hand and the digits

flexor pollicis brevis: muscle that flexes the thumb

flexor pollicis longus: muscle that flexes the distal phalanx of the thumb

flexor retinaculum: band of connective tissue that extends over the palmar surface of the hand

hypothenar: group of muscles on the medial aspect of the palm

hypothenar eminence: rounded contour of muscle at the base of the little finger

Infraspinatus: muscle that laterally rotates the arm

Intermediate: group of midpalmar muscles

intrinsic muscles of the hand: muscles that move the wrists, hands, and fingers and originate in the palm

latissimus dorsi: broad, triangular axial muscle located on the inferior part of the back

lumbrical: muscle that flexes each finger at the metacarpophalangeal joints and extend each finger at the interphalangeal joints

opponens digiti minimi: muscle that brings the little finger across the palm to meet the thumb

opponens pollicis: muscle that moves the thumb across the palm to meet another finger

palmar interossei: muscles that abduct and flex each finger at the metacarpophalangeal joints and extend each finger at the interphalangeal joints

palmaris longus: muscle that provides weak flexion of the hand at the wrist

pectoral girdle: shoulder girdle, made up of the clavicle and scapula

pectoralis major: thick, fan-shaped axial muscle that covers much of the superior thorax

pectoralis minor: muscle that moves the scapula and assists in inhalation

pronator quadratus: pronator that originates on the ulna and inserts on the radius

pronator teres: pronator that originates on the humerus and inserts on the radius

retinacula: fibrous bands that sheath the tendons at the wrist

rhomboid major: muscle that attaches the vertebral border of the scapula to the spinous process of the thoracic vertebrae

rhomboid minor: muscle that attaches the vertebral border of the scapula to the spinous process of the thoracic vertebrae

rotator cuff: (also, musculotendinous cuff) the circle of tendons around the shoulder joint

serratus anterior: large and flat muscle that originates on the ribs and inserts onto the scapula

subclavius: muscle that stabilizes the clavicle during movement

subscapularis: muscle that originates on the anterior scapula and medially rotates the arm

superficial anterior compartment of the forearm: flexor carpi radialis, palmaris longus, flexor carpi ulnaris, flexor digitorum superficialis, and their associated blood vessels and nerves

superficial posterior compartment of the forearm: extensor radialis longus, extensor carpi radialis brevis, extensor digitorum, extensor digiti minimi, extensor carpi ulnaris, and their associated blood vessels and nerves

supinator: muscle that moves the palm and forearm anteriorly

supraspinatus: muscle that abducts the arm

teres major: muscle that extends the arm and assists in adduction and medial rotation of it

teres minor:muscle that laterally rotates and extends the arm

thenar: group of muscles on the lateral aspect of the palm

thenar eminence: rounded contour of muscle at the base of the thumb

trapezius: muscle that stabilizes the upper part of the back

triceps brachii: three-headed muscle that extends the forearm

Axial Abdominal and Pelvic Muscles

anal triangle: posterior triangle of the perineum that includes the anus

caval opening: opening in the diaphragm that allows the inferior vena cava to pass through; foramen for the vena cava

compressor urethrae: deep perineal muscle in women

deep transverse perineal: deep perineal muscle in men

diaphragm: skeletal muscle that separates the thoracic and abdominal cavities and is dome-shaped at rest

external intercostal: superficial intercostal muscles that raise the rib cage

external oblique: superficial abdominal muscle with fascicles that extend inferiorly and medially

iliococcygeus: muscle that makes up the levator ani along with the pubococcygeus

innermost intercostal: the deepest intercostal muscles that draw the ribs together

intercostal muscles: muscles that span the spaces between the ribs

internal intercostal: muscles the intermediate intercostal muscles that draw the ribs together

internal oblique: flat, intermediate abdominal muscle with fascicles that run perpendicular to those of the external oblique

ischiococcygeus: muscle that assists the levator ani and pulls the coccyx anteriorly

levator ani: pelvic muscle that resists intra-abdominal pressure and supports the pelvic viscera

linea alba: white, fibrous band that runs along the midline of the trunk

pelvic diaphragm: muscular sheet that comprises the levator ani and the ischiococcygeus

perineum: diamond-shaped region between the pubic symphysis, coccyx, and ischial tuberosities

pubococcygeus: muscle that makes up the levator ani along with the iliococcygeus

quadratus lumborum: posterior part of the abdominal wall that helps with posture and stabilization of the body

rectus abdominis: long, linear muscle that extends along the middle of the trunk

rectus sheaths: tissue that makes up the linea alba

sphincter urethrovaginalis: deep perineal muscle in women

tendinous intersections: three transverse bands of collagen fibers that divide the rectus abdominis into segments

transversus abdominis: deep layer of the abdomen that has fascicles arranged transversely around the abdomen

urogenital triangle: anterior triangle of the perineum that includes the external genitals

Lower Appendicular Muscles: Thighs, Legs, and Feet

adductor brevis: muscle that adducts and medially rotates the thigh

adductor longus: muscle that adducts, medially rotates, and flexes the thigh

adductor magnus: muscle with an anterior fascicle that adducts, medially rotates and flexes the thigh, and a posterior fascicle that assists in thigh extension

anterior compartment of the leg: region that includes muscles that dorsiflex the foot

anterior compartment of the thigh: region that includes muscles that flex the thigh and extend the leg

biceps femoris: hamstring muscle

calcaneal tendon: (also, **Achilles tendon**) strong tendon that inserts into the calcaneal bone of the ankle

dorsal group: region that includes the extensor digitorum brevis

extensor digitorum brevis: muscle that extends the toes

extensor digitorum longus: muscle that is lateral to the tibialis anterior

extensor hallucis longus: muscle that is partly deep to the tibialis anterior and extensor digitorum longus

femoral triangle: region formed at the junction between the hip and the leg and includes the pectineus, femoral nerve, femoral artery, femoral vein, and deep inguinal lymph nodes

fibularis brevis: (also, peroneus brevis) muscle that plantar flexes the foot at the ankle and everts it at the intertarsal joints

fibularis longus: (also, peroneus longus) muscle that plantar flexes the foot at the ankle and everts it at the intertarsal joints

fibularis tertius: small muscle that is associated with the extensor digitorum longus

flexor digitorum longus: muscle that flexes the four small toes

flexor hallucis longus: muscle that flexes the big toe

gastrocnemius: most superficial muscle of the calf

gluteal group: muscle group that extends, flexes, rotates, adducts, and abducts the femur

gluteus maximus: largest of the gluteus muscles that extends the femur

gluteus medius: muscle deep to the gluteus maximus that abducts the femur at the hip

gluteus minimus: smallest of the gluteal muscles and deep to the gluteus medius

gracilis: muscle that adducts the thigh and flexes the leg at the knee

hamstring group: three long muscles on the back of the leg

iliacus: muscle that, along with the psoas major, makes up the iliopsoas

iliopsoas group: muscle group consisting of iliacus and psoas major muscles, that flexes the thigh at the hip, rotates it laterally, and flexes the trunk of the body onto the hip

iliotibial tract: muscle that inserts onto the tibia; made up of the gluteus maximus and connective tissues of the tensor fasciae latae

inferior extensor retinaculum: cruciate ligament of the ankle

inferior gemellus: muscle deep to the gluteus maximus on the lateral surface of the thigh that laterally rotates the femur at the hip

lateral compartment of the leg: region that includes the fibularis (peroneus) longus and the fibularis (peroneus) brevis and their associated blood vessels and nerves

medial compartment of the thigh: a region that includes the adductor longus, adductor brevis, adductor magnus, pectineus, gracilis, and their associated blood vessels and nerves

obturator externus: muscle deep to the gluteus maximus on the lateral surface of the thigh that laterally rotates the femur at the hip

obturator internus: muscle deep to the gluteus maximus on the lateral surface of the thigh that laterally rotates the femur at the hip

patellar ligament: extension of the quadriceps tendon below the patella

pectineus: muscle that abducts and flexes the femur at the hip

pelvic girdle: hips, a foundation for the lower limb

piriformis: muscle deep to the gluteus maximus on the lateral surface of the thigh that laterally rotates the femur at the hip

plantar aponeurosis: muscle that supports the longitudinal arch of the foot

plantar group: four-layered group of intrinsic foot muscles

plantaris: muscle that runs obliquely between the gastrocnemius and the soleus

popliteal fossa: diamond-shaped space at the back of the knee

popliteus: muscle that flexes the leg at the knee and creates the floor of the popliteal fossa

posterior compartment of the leg: region that includes the superficial gastrocnemius, soleus, and plantaris, and the deep popliteus, flexor digitorum longus, flexor hallucis longus, and tibialis posterior

posterior compartment of the thigh: region that includes muscles that flex the leg and extend the thigh

psoas major: muscle that, along with the iliacus, makes up the iliopsoas

quadratus femoris: muscle deep to the gluteus maximus on the lateral surface of the thigh that laterally rotates the femur at the hip

quadriceps femoris group: four muscles, that extend and stabilize the knee

quadriceps tendon: (also, **patellar tendo**n) tendon common to all four quadriceps muscles, inserts into the patella

rectus femoris: quadricep muscle on the anterior aspect of the thigh

sartorius: band-like muscle that flexes, abducts, and laterally rotates the leg at the hip

semimembranosus: hamstring muscle

semitendinosus: hamstring muscle

soleus: wide, flat muscle deep to the gastrocnemius

superior extensor retinaculum: transverse ligament of the ankle

superior gemellus: muscle deep to the gluteus maximus on the lateral surface of the thigh that laterally rotates the femur at the hip

tensor fascia lata: muscle that flexes and abducts the thigh

tibialis anterior: muscle located on the lateral surface of the tibia

tibialis posterior: muscle that plantar flexes and inverts the foot

vastus intermedius: quadricep muscle that is between the vastus lateralis and vastus medialis and is deep to the rectus femoris

vastus lateralis: quadricep muscle on the lateral aspect of the thigh

vastus medialis: quadricep muscle on the medial aspect of the thigh

Ha`awina 03: HLTH 140

The Neurologic system

Hō`ulu`ulu Pōkole (Overview)

The neurologic system, also called the nervous system, is divided into the **central nervous system (CNS)** and the **peripheral nervous system (PNS)**. This ha`awina will explore the CNS, the PNS, and also look closely at organs of sensory perception. We will also look briefly at the autonomic nervous system which involves both the CNS and PNS.

Ke Haumana ka `apo (Student Learning Outcomes)

1. Identify the structures of the endocrine system
2. Describe the primary functions of the endocrine system
3. Apply word building skills by constructing medical terms related to the endocrine system
4. Recall common abbreviations used in reference to the endocrine system
5. recognize, define, and pronounce terms related to the endocrine system correctly

The Central Nervous System

The brain and the spinal cord are the central nervous system, and they represent the main organs of the nervous system. The spinal cord is a single structure, whereas the adult brain is described in terms of four major regions: the cerebrum, the diencephalon, the brain stem, and the cerebellum. A person's conscious experiences are based on neural activity in the brain. The regulation of homeostasis is governed by a specialized region in the brain. The coordination of reflexes depends on the integration of sensory and motor pathways in the spinal cord.

The Cerebrum

The iconic gray mantle of the human brain, which appears to make up most of the mass of the brain, is the cerebrum (Figure). The wrinkled portion is the cerebral cortex, and the rest of the structure is beneath that outer covering. There is a large separation between the two sides of the cerebrum called the longitudinal fissure. It separates the cerebrum into two distinct halves, a right and left cerebral hemisphere. Deep within the cerebrum, the white matter of the corpus callosum provides the major pathway for communication between the two hemispheres of the cerebral cortex.

The Cerebrum

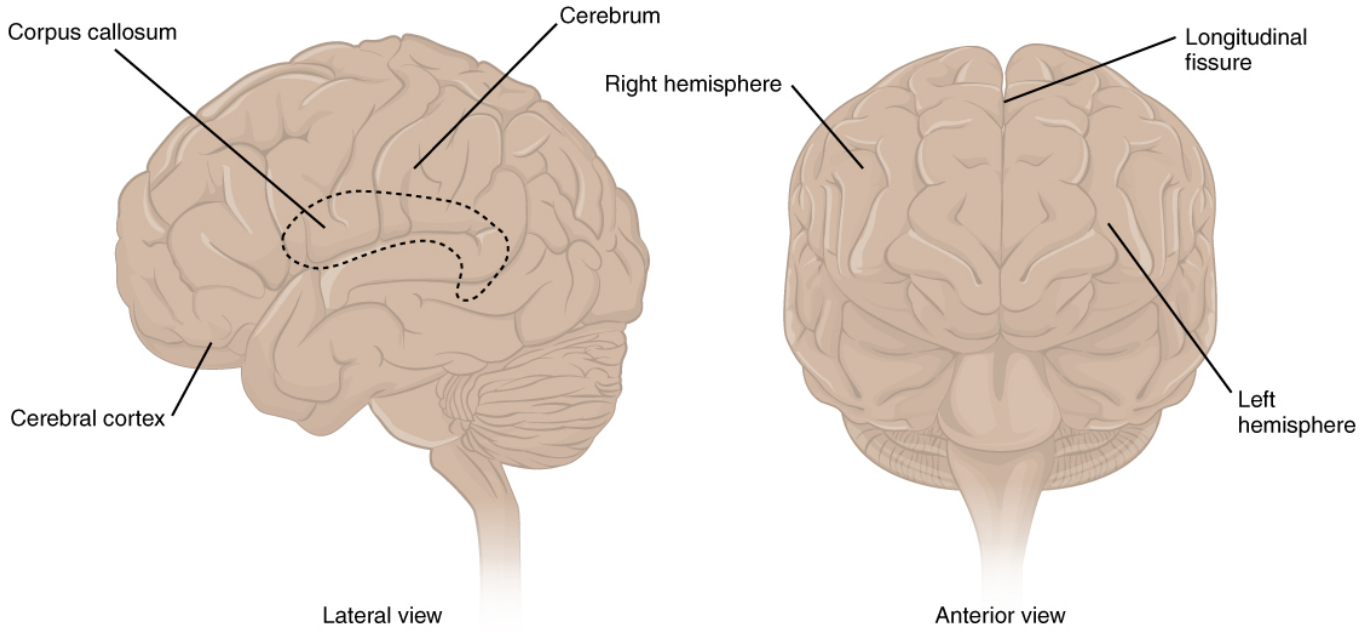

Many of the higher neurological functions, such as memory, emotion, and consciousness, are the result of cerebral function. The complexity of the cerebrum is different across vertebrate species. The cerebrum of the most primitive vertebrates is not much more than the connection for the sense of smell. In mammals, the cerebrum comprises the outer gray matter that is the cortex (from the Latin word meaning "bark of a tree") and several deep nuclei that belong to three important functional groups. The basal nuclei are responsible for cognitive processing, the most important function being that associated with planning movements. The basal forebrain contains nuclei that are important in learning and memory. The limbic cortex is the region of the cerebral cortex that is part of the limbic system, a collection of structures involved in emotion, memory, and behavior.

Cerebral Cortex

The cerebrum is covered by a continuous layer of gray matter that wraps around either side of the forebrain—the cerebral cortex. This thin, extensive region of wrinkled gray matter is responsible for the higher functions of the nervous system. A gyrus (plural = gyri) is the ridge of one of those wrinkles, and a sulcus (plural = sulci) is the groove between two gyri. The pattern of these folds of tissue indicates specific regions of the cerebral cortex.

The head is limited by the size of the birth canal, and the brain must fit inside the cranial cavity of the skull. Extensive folding in the cerebral cortex enables more gray matter to fit into this limited space. If the gray matter of the cortex were peeled off of the cerebrum and laid out flat, its surface area would be roughly equal to one square meter.

The folding of the cortex maximizes the amount of gray matter in the cranial cavity. During embryonic development, as the telencephalon expands within the skull, the brain goes through a regular course of growth that results in everyone's brain having a similar pattern of folds. The surface of the brain can be mapped on the basis of the locations of large gyri and sulci. Using these landmarks, the cortex can be separated into four major regions, or lobes (Figure). The lateral sulcus that separates the temporal lobe from the other regions is one such landmark. Superior to the lateral sulcus are the parietal lobe and frontal

lobe, which are separated from each other by the central sulcus. The posterior region of the cortex is the occipital lobe, which has no obvious anatomical border between it and the parietal or temporal lobes on the lateral surface of the brain. From the medial surface, an obvious landmark separating the parietal and occipital lobes is called the parieto-occipital sulcus. The fact that there is no obvious anatomical border between these lobes is consistent with the functions of these regions being interrelated.

Lobes of the Cerebral Cortex

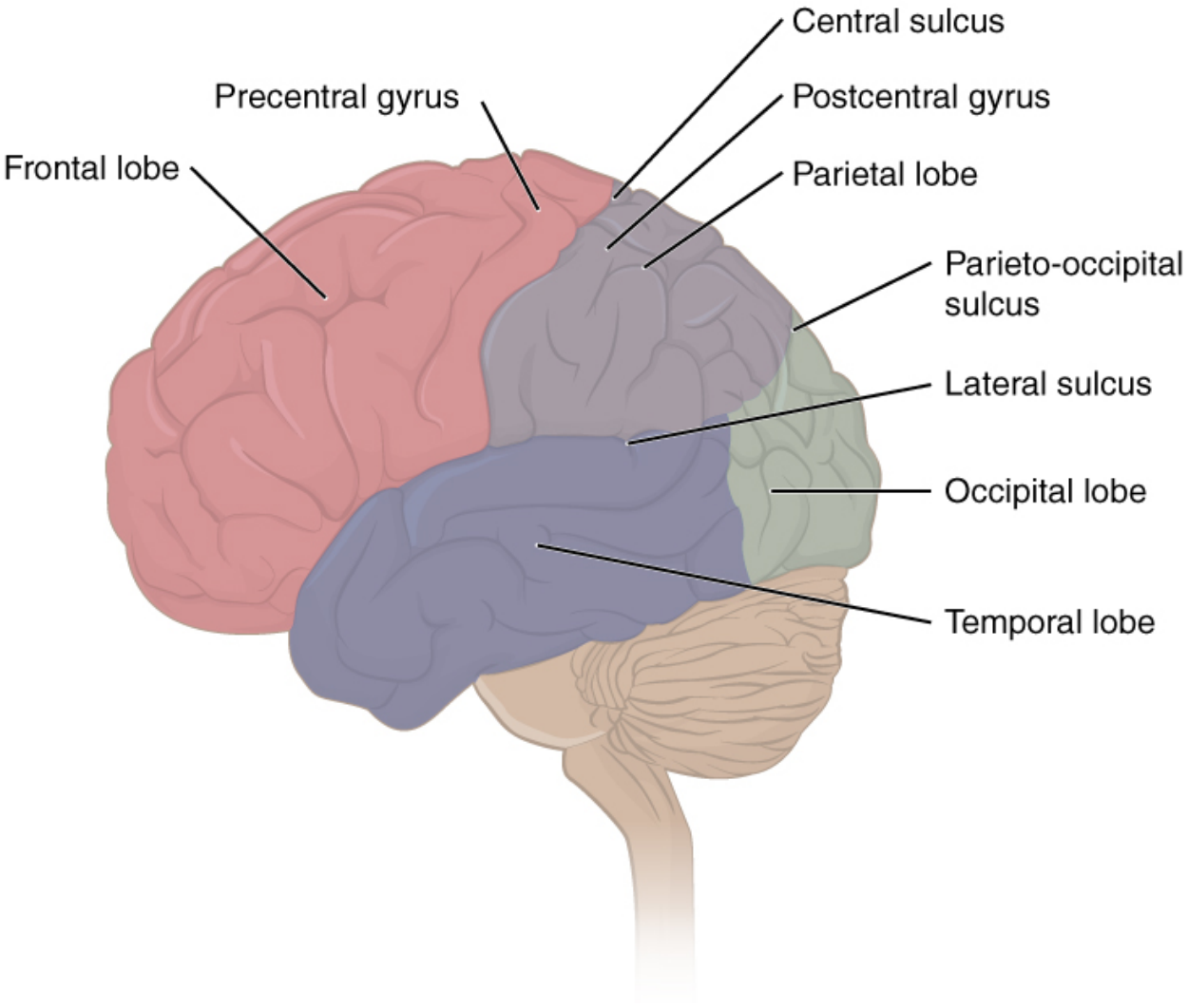

The cerebral cortex is divided into four lobes. Extensive folding increases the surface area available for cerebral functions.

Different regions of the cerebral cortex can be associated with particular functions, a concept known as localization of function. In the early 1900s, a German neuroscientist named Korbinian Brodmann performed an extensive study of the microscopic anatomy—the cytoarchitecture—of the cerebral cortex and divided the cortex into 52 separate regions on the basis of the histology of the cortex. His work resulted in a system of classification known as Brodmann's areas, which is still used today to describe the anatomical distinctions within the cortex (Figure). The results from Brodmann's work on the anatomy align very well with the functional differences within the cortex. Areas 17 and 18 in the occipital lobe are responsible for primary visual perception. That visual information is complex, so it is processed

in the temporal and parietal lobes as well.

The temporal lobe is associated with primary auditory sensation, known as Brodmann's areas 41 and 42 in the superior temporal lobe. Because regions of the temporal lobe are part of the limbic system, memory is an important function associated with that lobe. Memory is essentially a sensory function; memories are recalled sensations such as the smell of Mom's baking or the sound of a barking dog. Even memories of movement are really the memory of sensory feedback from those movements, such as stretching muscles or the movement of the skin around a joint. Structures in the temporal lobe are responsible for establishing long-term memory, but the ultimate location of those memories is usually in the region in which the sensory perception was processed.

The main sensation associated with the parietal lobe is somatosensation, meaning the general sensations associated with the body. Posterior to the central sulcus is the postcentral gyrus, the primary somatosensory cortex, which is identified as Brodmann's areas 1, 2, and 3. All of the tactile senses are processed in this area, including touch, pressure, tickle, pain, itch, and vibration, as well as more general senses of the body such as proprioception and kinesthesia, which are the senses of body position and movement, respectively.

Anterior to the central sulcus is the frontal lobe, which is primarily associated with motor functions. The precentral gyrus is the primary motor cortex. Cells from this region of the cerebral cortex are the upper motor neurons that instruct cells in the spinal cord to move skeletal muscles. Anterior to this region are a few areas that are associated with planned movements. The premotor area is responsible for thinking of a movement to be made. The frontal eye fields are important in eliciting eye movements and in attending to visual stimuli. Broca's area is responsible for the production of language, or controlling movements responsible for speech; in the vast majority of people, it is located only on the left side. Anterior to these regions is the prefrontal lobe, which serves cognitive functions that can be the basis of personality, short-term memory, and consciousness. The prefrontal lobotomy is an outdated mode of treatment for personality disorders (psychiatric conditions) that profoundly affected the personality of the patient.

Brodmann's Areas of the Cerebral Cortex

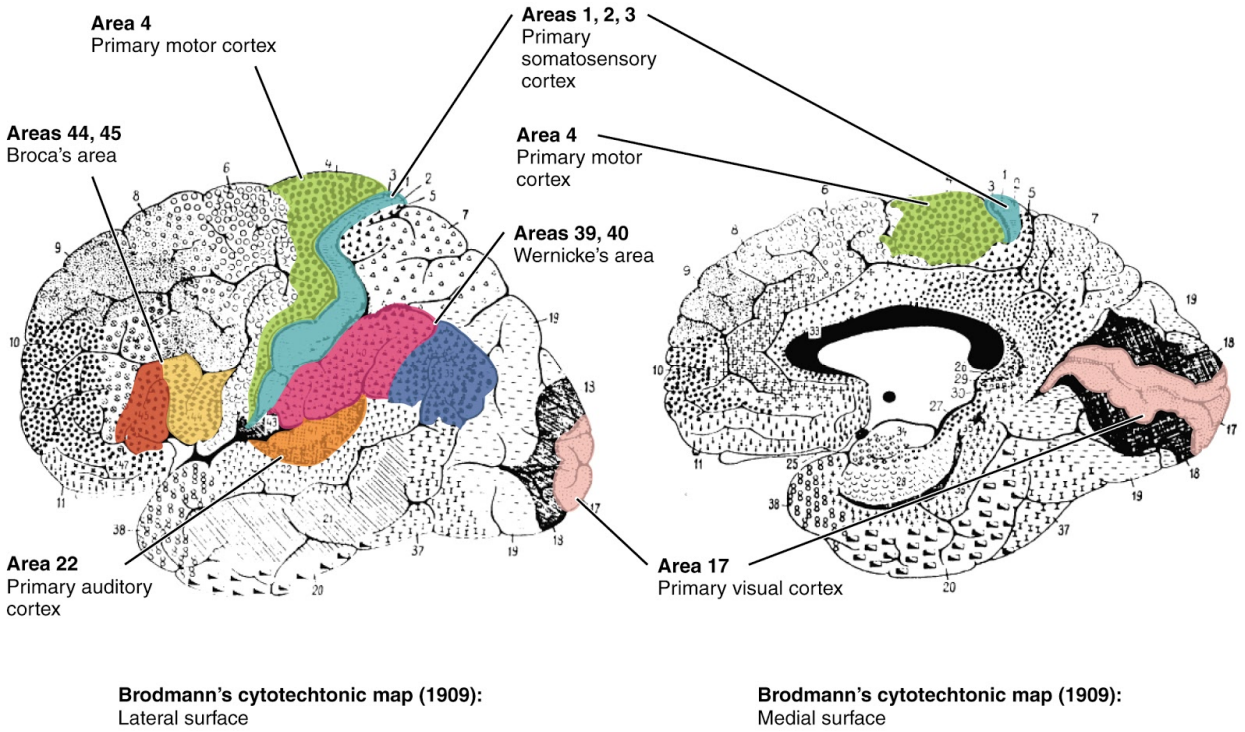

Brodmann mapping of functionally distinct regions of the cortex was based on its cytoarchitecture at a microscopic level.

Subcortical structures

Beneath the cerebral cortex are sets of nuclei known as subcortical nuclei that augment cortical processes. The nuclei of the basal forebrain serve as the primary location for acetylcholine production, which modulates the overall activity of the cortex, possibly leading to greater attention to sensory stimuli. Alzheimer's disease is associated with a loss of neurons in the basal forebrain. The hippocampus and amygdala are medial-lobe structures that, along with the adjacent cortex, are involved in long-term memory formation and emotional responses. The basal nuclei are a set of nuclei in the cerebrum responsible for comparing cortical processing with the general state of activity in the nervous system to influence the likelihood of movement taking place. For example, while a student is sitting in a classroom listening to a lecture, the basal nuclei will keep the urge to jump up and scream from actually happening. (The basal nuclei are also referred to as the basal ganglia, although that is potentially confusing because the term ganglia is typically used for peripheral structures.)

The major structures of the basal nuclei that control movement are the caudate, putamen, and globus pallidus, which are located deep in the cerebrum. The caudate is a long nucleus that follows the basic C-shape of the cerebrum from the frontal lobe, through the parietal and occipital lobes, into the temporal lobe. The putamen is mostly deep in the anterior regions of the frontal and parietal lobes. Together, the caudate and putamen are called the striatum. The globus pallidus is a layered nucleus that lies just medial to the putamen; they are called the lenticular nuclei because they look like curved pieces fitting together like lenses. The globus pallidus has two subdivisions, the external and internal segments,

which are lateral and medial, respectively. These nuclei are depicted in a frontal section of the brain in Figure.

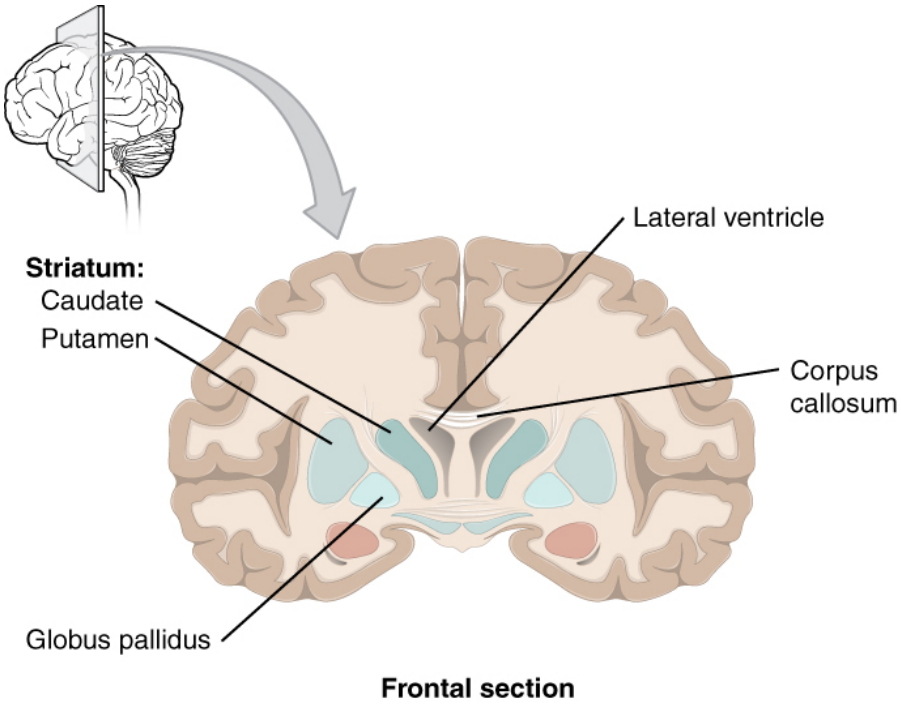

Frontal Section of Cerebral Cortex and Basal Nuclei

The major components of the basal nuclei, shown in a frontal section of the brain, are the caudate (just lateral to the lateral ventricle), the putamen (inferior to the caudate and separated by the large white-matter structure called the internal capsule), and the globus pallidus (medial to the putamen).

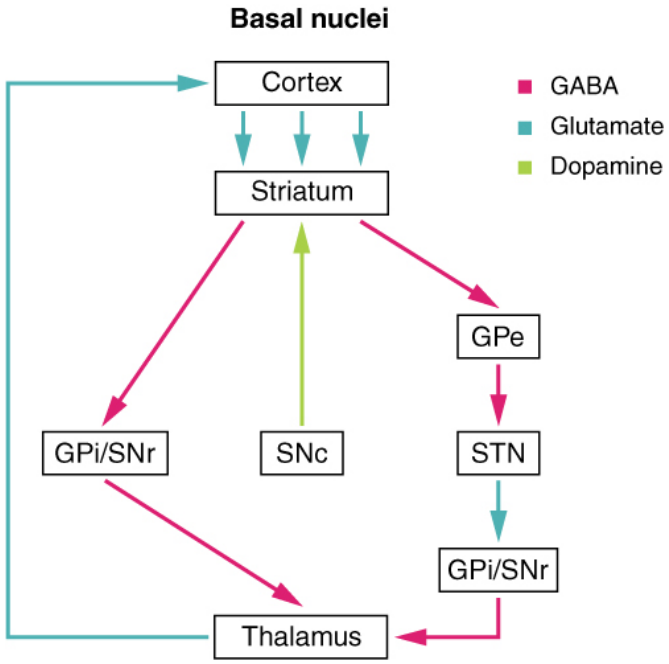

Connections of Basal Nuclei

Input to the basal nuclei is from the cerebral cortex, which is an excitatory connection releasing glutamate as a neurotransmitter. This input is to the striatum, or the caudate and putamen. In the direct pathway, the striatum projects to the internal segment of the globus pallidus and the substantia nigra pars reticulata (GPi/SNr). This is an inhibitory pathway, in which GABA is released at the synapse, and the target cells are hyperpolarized and less likely to fire. The output from the basal nuclei is to the thalamus, which is an inhibitory projection using GABA.

The switch between the two pathways is the substantia nigra pars compacta, which projects to the striatum and releases the neurotransmitter dopamine. Dopamine receptors are either excitatory (D1-type receptors) or inhibitory (D2-type receptors). The direct pathway is activated by dopamine, and the indirect pathway is inhibited by dopamine. When the substantia nigra pars compacta is firing, it signals to the basal nuclei that the body is in an active state, and movement will be more likely. When the substantia nigra pars compacta is silent, the body is in a passive state, and movement is inhibited. To illustrate this situation, while a student is sitting listening to a

lecture, the substantia nigra pars compacta would be silent and the student less likely to get up and walk around. Likewise, while the professor is lecturing, and walking around at the front of the classroom, the professor's substantia nigra pars compacta would be active, in keeping with his or her activity level.

EVERYDAY CONNECTIONS...The Myth of Left Brain/Right Brain

There is a persistent myth that people are "right-brained" or "left-brained," which is an oversimplification of an important concept about the cerebral hemispheres. There is some lateralization of function, in which the left side of the brain is devoted to language function and the right side is devoted to spatial and nonverbal reasoning. Whereas these functions are predominantly associated with those sides of the brain, there is no monopoly by either side on these functions. Many pervasive functions, such as language, are distributed globally around the cerebrum.

Some of the support for this misconception has come from studies of split brains. A drastic way to deal with a rare and devastating neurological condition (intractable epilepsy) is to separate the two hemispheres of the brain. After sectioning the corpus callosum, a split-brained patient will have trouble producing verbal responses on the basis of sensory information processed on the right side of the cerebrum, leading to the idea that the left side is responsible for language function.

However, there are well-documented cases of language functions lost from damage to the right side of the brain. The deficits seen in damage to the left side of the brain are classified as aphasia, a loss of speech function; damage on the right side can affect the use of language. Right-side damage can result in a loss of ability to understand figurative aspects of speech, such as jokes, irony, or metaphors. Nonverbal aspects of speech can be affected by damage to the right side, such as facial expression or body language, and right-side damage can lead to a "flat affect" in speech, or a loss of emotional expression in speech—sounding like a robot when talking.

The Diencephalon

The diencephalon is the one region of the adult brain that retains its name from embryologic development. The etymology of the word diencephalon translates to "through brain." It is the connection between the cerebrum and the rest of the nervous system, with one exception. The rest of the brain, the spinal cord, and the PNS all send information to the cerebrum through the diencephalon. Output from the cerebrum passes through the diencephalon. The single exception is the system associated with olfaction, or the sense of smell, which connects directly with the cerebrum. In the earliest vertebrate species, the cerebrum was not much more than olfactory bulbs that received peripheral information about the chemical environment (to call it smell in these organisms is imprecise because they lived in the ocean).

The diencephalon is deep beneath the cerebrum and constitutes the walls of the third ventricle. The diencephalon can be described as any region of the brain with "thalamus" in its name. The two major regions of the diencephalon are the thalamus itself and the hypothalamus (Figure). There are other structures, such as the epithalamus, which contains the pineal gland, or the subthalamus, which includes the subthalamic nucleus that is part of the basal nuclei.

Thalamus

The thalamus is a collection of nuclei that relay information between the cerebral cortex and the periphery, spinal cord, or brain stem. All sensory information, except for the sense of smell, passes through the thalamus before processing by the cortex. The thalamus does not just pass the information on,

it also processes that information. For example, the portion of the thalamus that receives visual information will influence what visual stimuli are important, or what receives attention.

The cerebrum also sends information down to the thalamus, which usually communicates motor commands.

Hypothalamus

Inferior and slightly anterior to the thalamus is the hypothalamus, the other major region of the diencephalon. The hypothalamus is a collection of nuclei that are largely involved in regulating homeostasis. The hypothalamus is the executive region in charge of the autonomic nervous system and the endocrine system through its regulation of the anterior pituitary gland. Other parts of the hypothalamus are involved in memory and emotion as part of the limbic system.

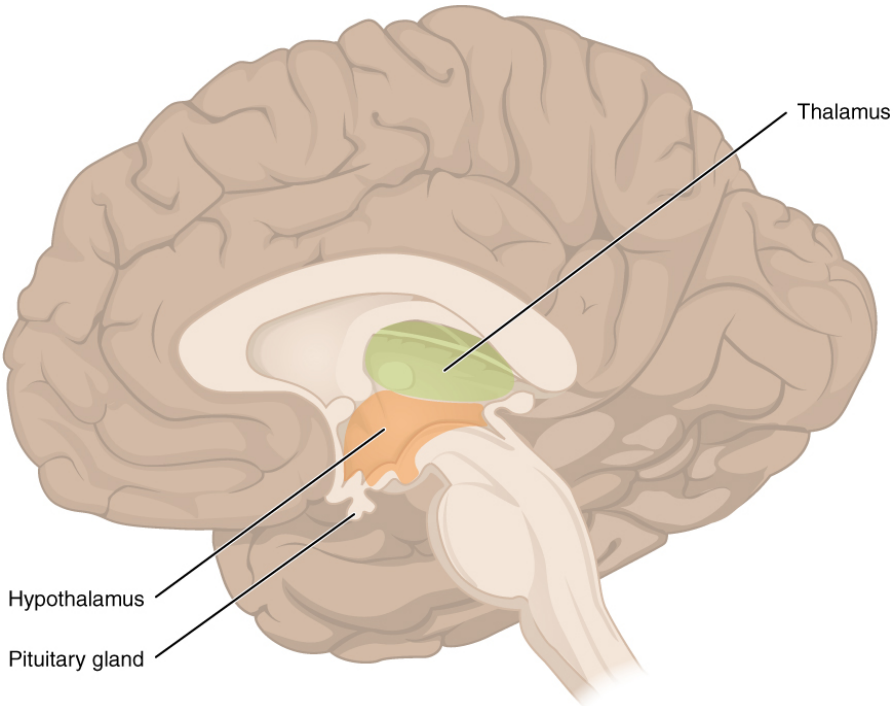

The Diencephalon

The diencephalon is composed primarily of the thalamus and hypothalamus, which together define the walls of the third ventricle. The thalami are two elongated, ovoid structures on either side of the midline that make contact in the middle. The hypothalamus is inferior and anterior to the thalamus, culminating in a sharp angle to which the pituitary gland is attached.

Brain Stem

The midbrain and hindbrain (composed of the pons and the medulla) are collectively referred to as the brain stem (Figure). The structure emerges from the ventral surface of the forebrain as a tapering cone that connects the brain to the spinal cord. Attached to the brain stem, but considered a separate region of the adult brain, is the cerebellum. The midbrain coordinates sensory representations of the visual, auditory, and somatosensory perceptual spaces. The pons is the main connection with the cerebellum. The pons and the medulla regulate several crucial functions, including the cardiovascular and respiratory systems and rates.

The cranial nerves connect through the brain stem and provide the brain with the sensory input and motor output associated with the head and neck, including most of the special senses. The major ascending and descending pathways between the spinal cord and brain, specifically the cerebrum, pass through the brain stem.

The Brain Stem

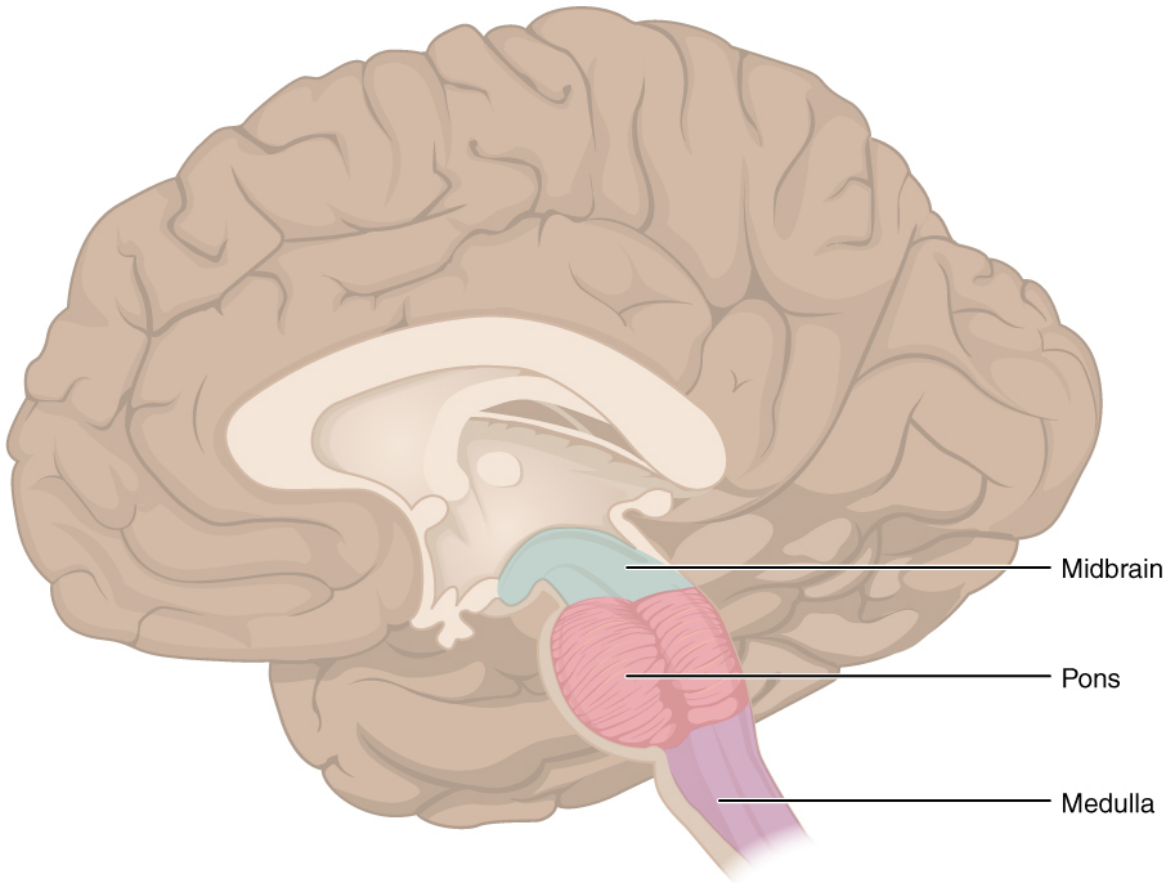

The brain stem comprises three regions: the midbrain, the pons, and the medulla.

Midbrain

One of the original regions of the embryonic brain, the midbrain is a small region between the thalamus and pons. It is separated into the tectum and tegmentum, from the Latin words for roof and floor, respectively. The cerebral aqueduct passes through the center of the midbrain, such that these regions are the roof and floor of that canal.

The tectum is composed of four bumps known as the colliculi (singular = colliculus), which means "little hill" in Latin. The inferior colliculus is the inferior pair of these enlargements and is part of the auditory brain stem pathway. Neurons of the inferior colliculus project to the thalamus, which then sends auditory information to the cerebrum for the conscious perception of sound. The superior colliculus is the superior pair and combines sensory information about visual space, auditory space, and somatosensory space. Activity in the superior colliculus is related to orienting the eyes to a sound or touch stimulus. If you are walking along the sidewalk on campus and you hear chirping, the superior colliculus coordinates that information with your awareness of the visual location of the tree right above you. That is the correlation of auditory and visual maps. If you suddenly feel something wet fall on your head, your superior colliculus integrates that with the auditory and visual maps and you know that the chirping bird just relieved itself on you. You want to look up to see the culprit, but do not.

The tegmentum is continuous with the gray matter of the rest of the brain stem. Throughout the midbrain, pons, and medulla, the tegmentum contains the nuclei that receive and send information through the cranial nerves, as well as regions that regulate important functions such as those of the cardiovascular and respiratory systems.

Pons

The word pons comes from the Latin word for bridge. It is visible on the anterior surface of the brain stem as the thick bundle of white matter attached to the cerebellum. The pons is the main connection between the cerebellum and the brain stem. The bridge-like white matter is only the anterior surface of the pons; the gray matter beneath that is a continuation of the tegmentum from the midbrain. Gray matter in the tegmentum region of the pons contains neurons receiving descending input from the forebrain that is sent to the cerebellum.

Medulla

The medulla is the region known as the myelencephalon in the embryonic brain. The initial portion of the name, "myel," refers to the significant white matter found in this region—especially on its exterior, which is continuous with the white matter of the spinal cord. The tegmentum of the midbrain and pons continues into the medulla because this gray matter is responsible for processing cranial nerve information. A diffuse region of gray matter throughout the brain stem, known as the reticular formation, is related to sleep and wakefulness, such as general brain activity and attention.

The Cerebellum

The cerebellum, as the name suggests, is the "little brain." It is covered in gyri and sulci like the cerebrum, and looks like a miniature version of that part of the brain (Figure). The cerebellum is largely responsible for comparing information from the cerebrum with sensory feedback from the periphery through the spinal cord. It accounts for approximately 10 percent of the mass of the brain.

Ascending input from the periphery and spinal cord enters through the fibers of the inferior olive. Output goes to the midbrain, which sends a descending signal to the spinal cord.

Descending fibers from the cerebrum have branches that connect to neurons in the pons. Those neurons project into the cerebellum, providing a copy of motor commands sent to the spinal cord. Sensory information from the periphery, which enters through spinal or cranial nerves, is copied to a nucleus in the medulla known as the inferior olive. Fibers from this nucleus enter the cerebellum and are compared with the descending commands from the cerebrum. If the primary motor cortex of the frontal lobe sends a command down to the spinal cord to initiate walking, a copy of that instruction is sent to the cerebellum. Sensory feedback from the muscles and joints, proprioceptive information about the movements of walking, and sensations of balance are sent to the cerebellum through the inferior olive and the cerebellum compares them. If walking is not coordinated, perhaps because the ground is uneven or a strong wind is blowing, then the cerebellum sends out a corrective command to compensate for the difference between the original cortical command and the sensory feedback. The output of the cerebellum is into the midbrain, which then sends a descending input to the spinal cord to correct the messages going to skeletal muscles.

The Spinal Cord

The description of the CNS is concentrated on the structures of the brain, but the spinal cord is another major organ of the system. Whereas the brain develops out of expansions of the neural tube into primary and then secondary vesicles, the spinal cord maintains the tube structure and is only specialized into certain regions. As the spinal cord continues to develop in the newborn, anatomical features mark its surface. The anterior midline is marked by the anterior median fissure, and the posterior midline is marked by the posterior median sulcus. Axons enter the posterior side through the dorsal (posterior) nerve root, which marks the posterolateral sulcus on either side. The axons emerging from the anterior side do so through the ventral (anterior) nerve root. Note that it is common to see the terms dorsal (dorsal = “back”) and ventral (ventral = “belly”) used interchangeably with posterior and anterior, particularly in reference to nerves and the structures of the spinal cord. You should learn to be comfortable with both.

On the whole, the posterior regions are responsible for sensory functions and the anterior regions are associated with motor functions. This comes from the initial development of the spinal cord, which is divided into the basal plate and the alar plate. The basal plate is closest to the ventral midline of the neural tube, which will become the anterior face of the spinal cord and gives rise to motor neurons. The alar plate is on the dorsal side of the neural tube and gives rise to neurons that will receive sensory input from the periphery.

The length of the spinal cord is divided into regions that correspond to the regions of the vertebral column. The name of a spinal cord region corresponds to the level at which spinal nerves pass through the intervertebral foramina. Immediately adjacent to the brain stem is the cervical region, followed by the thoracic, then the lumbar, and finally the sacral region. The spinal cord is not the full length of the vertebral column because the spinal cord does not grow significantly longer after the first or second year, but the skeleton continues to grow. The nerves that emerge from the spinal cord pass through the intervertebral formina at the respective levels. As the vertebral column grows, these nerves grow with it and result in a long bundle of nerves that resembles a horse’s tail and is named the cauda equina. The sacral spinal cord is at the level of the upper lumbar vertebral bones. The spinal nerves extend from their

various levels to the proper level of the vertebral column.

Gray Horns

In cross-section, the gray matter of the spinal cord has the appearance of an ink-blot test, with the spread of the gray matter on one side replicated on the other—a shape reminiscent of a bulbous capital "H." As shown in Figure, the gray matter is subdivided into regions that are referred to as horns. The posterior horn is responsible for sensory processing. The anterior horn sends out motor signals to the skeletal muscles. The lateral horn, which is only found in the thoracic, upper lumbar, and sacral regions, is the central component of the sympathetic division of the autonomic nervous system.

Some of the largest neurons of the spinal cord are the multipolar motor neurons in the anterior horn. The fibers that cause contraction of skeletal muscles are the axons of these neurons. The motor neuron that causes contraction of the big toe, for example, is located in the sacral spinal cord. The axon that has to reach all the way to the belly of that muscle may be a meter in length. The neuronal cell body that maintains that long fiber must be quite large, possibly several hundred micrometers in diameter, making it one of the largest cells in the body.

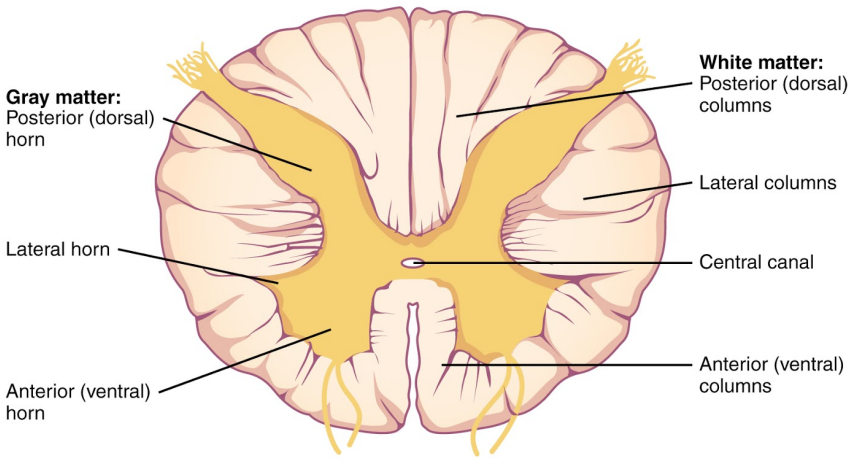

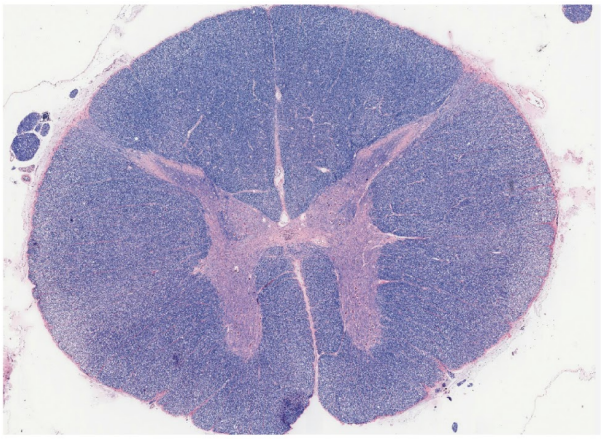

White Columns

Just as the gray matter is separated into horns, the white matter of the spinal cord is separated into columns. Ascending tracts of nervous system fibers in these columns carry sensory information up to the brain, whereas descending tracts carry motor commands from the brain. Looking at the spinal cord longitudinally, the columns extend along its length as continuous bands of white matter. Between the two posterior horns of gray matter are the posterior columns. Between the two anterior horns, and bounded by the axons of motor neurons emerging from that gray matter area, are the anterior columns. The white matter on either side of the spinal cord, between the posterior horn and the axons of the anterior horn neurons, are the lateral columns. The posterior columns are composed of axons of ascending tracts. The anterior and

lateral columns are composed of many different groups of axons of both ascending and descending tracts—the latter carrying motor commands down from the brain to the spinal cord to control output to the periphery.

(Micrograph provided by the Regents of University of Michigan Medical School © 2012)

DISORDERS OF THE…Basal Nuclei

Parkinson's disease is a disorder of the basal nuclei, specifically of the substantia nigra, that demonstrates the effects of the direct and indirect pathways. Parkinson's disease is the result of neurons in the substantia nigra pars compacta dying. These neurons release dopamine into the striatum. Without that modulatory influence, the basal nuclei are stuck in the indirect pathway, without the direct pathway being activated. The direct pathway is responsible for increasing cortical movement commands. The increased activity of the indirect pathway results in the hypokinetic disorder of Parkinson's disease.

Parkinson's disease is neurodegenerative, meaning that neurons die that cannot be replaced, so there is no cure for the disorder. Treatments for Parkinson's disease are aimed at increasing dopamine levels in the striatum. Currently, the most common way of doing that is by providing the amino acid L-DOPA, which is a precursor to the neurotransmitter dopamine and can cross the blood-brain barrier. With levels of the precursor elevated, the remaining cells of the substantia nigra pars compacta can make more neurotransmitter and have a greater effect. Unfortunately, the patient will become less responsive to L-DOPA treatment as time progresses, and it can cause increased dopamine levels elsewhere in the brain, which are associated with psychosis or schizophrenia.

The Peripheral Nervous System

The PNS is not as contained as the CNS because it is defined as everything that is not the CNS. Some peripheral structures are incorporated into the other organs of the body. In describing the anatomy of the PNS, it is necessary to describe the common structures, the nerves and the ganglia, as they are found in various parts of the body. Many of the neural structures that are incorporated into other organs are features of the digestive system; these structures are known as the enteric nervous system and are a special subset of the PNS.

Ganglia

A ganglion is a group of neuron cell bodies in the periphery. Ganglia can be categorized, for the most part, as either sensory ganglia or autonomic ganglia, referring to their primary functions. The most common type of sensory ganglion is a dorsal (posterior) root ganglion. These ganglia are the cell bodies of neurons with axons that are sensory endings in the periphery, such as in the skin, and that extend into the CNS through the dorsal nerve root.

Dorsal Root Ganglion

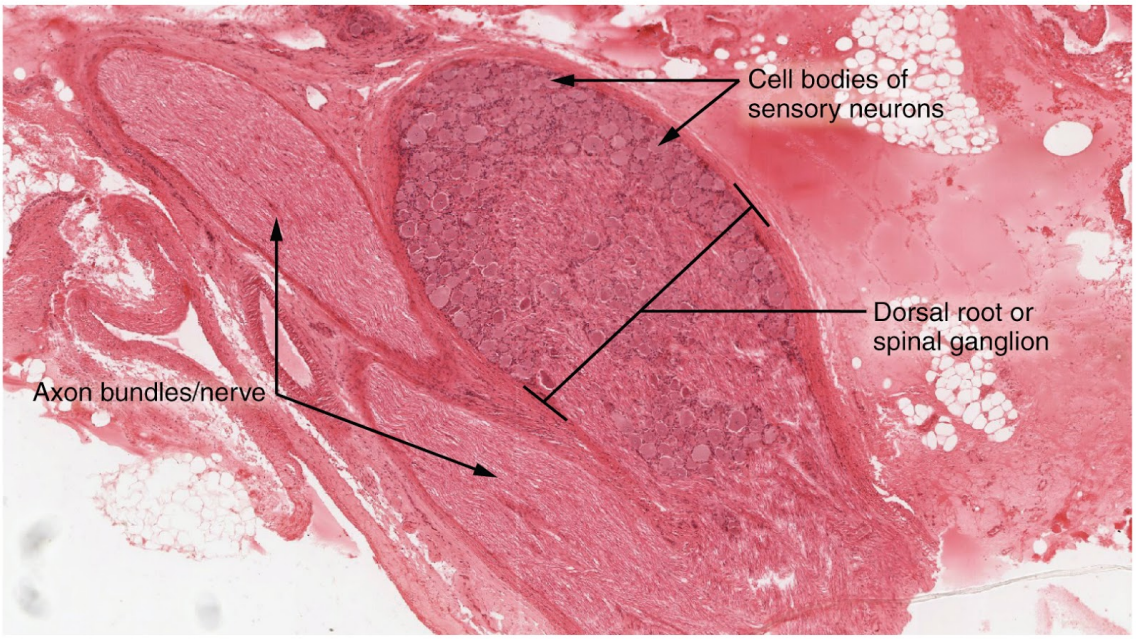

The cell bodies of sensory neurons, which are unipolar neurons by shape, are seen in this photomicrograph. Also, the fibrous region is composed of the axons of these neurons that are passing through the ganglion to be part of the dorsal nerve root (tissue source: canine). LM × 40. (Micrograph provided by the Regents of University of Michigan Medical School © 2012)

Spinal Cord and Root Ganglion

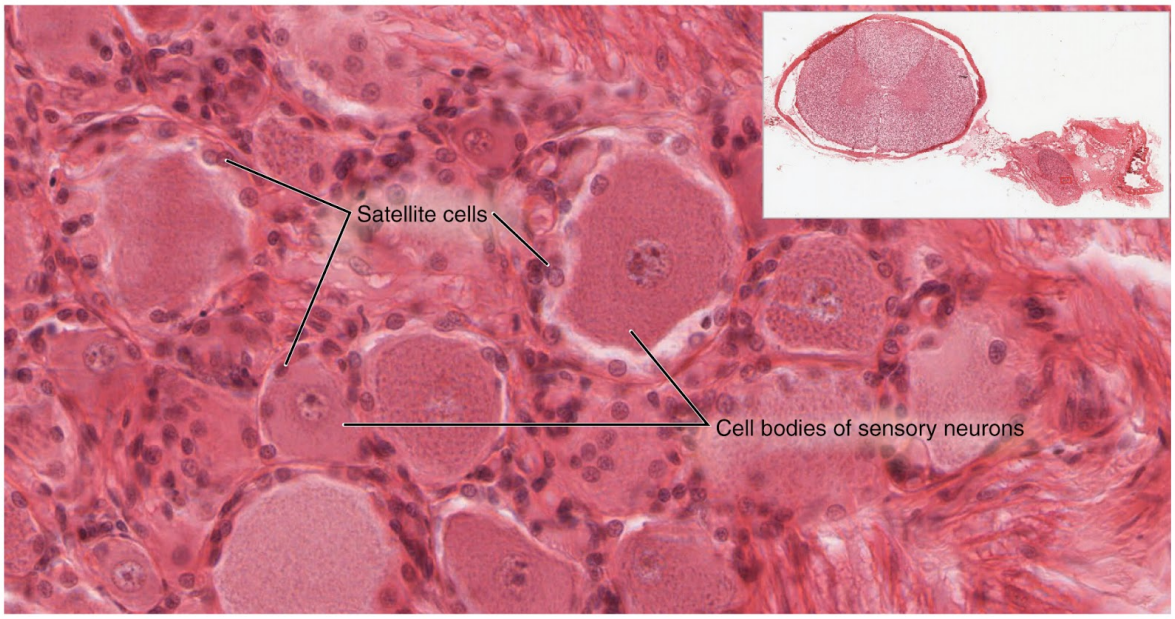

The slide includes both a cross-section of the lumbar spinal cord and a section of the dorsal root ganglion (see also Figure) (tissue source: canine). LM × 1600. (Micrograph provided by the Regents of University of Michigan Medical School © 2012)

Another type of sensory ganglion is a cranial nerve ganglion. This is analogous to the dorsal root ganglion, except that it is associated with a cranial nerve instead of a spinal nerve. The roots of cranial nerves are within the cranium, whereas the ganglia are outside the skull. For example, the trigeminal ganglion is superficial to the temporal bone whereas its associated nerve is attached to the mid-pons region of the brain stem. The neurons of cranial nerve ganglia are also unipolar in shape with associated satellite cells.

- The other major category of ganglia are those of the autonomic nervous system, which is divided into the sympathetic and parasympathetic nervous systems.
- Another group of autonomic ganglia are the terminal ganglia that receive input from cranial nerves or sacral spinal nerves and are responsible for regulating the parasympathetic aspect of homeostatic mechanisms.
- These two sets of ganglia, sympathetic and parasympathetic, often project to the same organs—one input from the chain ganglia and one input from a terminal ganglion—to regulate the overall function of an organ. For example, the heart receives two inputs such as these; one increases heart rate, and the other decreases it.

Nerves

Bundles of axons in the PNS are referred to as nerves. These structures in the periphery are different than the central counterpart, called a tract. Nerves are composed of more than just nervous tissue. They have connective tissues in their structure, as well as blood vessels supplying the tissues with nourishment. The outer surface of a nerve is a surrounding layer of fibrous connective tissue called the epineurium. Within the nerve, axons are further bundled into fascicles, which are each surrounded by their own layer of fibrous connective tissue called perineurium. Finally, individual axons are surrounded by loose connective tissue called the endoneurium (Figure). These three layers are similar to the connective tissue sheaths for muscles. Nerves are associated with the region of the CNS to which they are connected,

either as cranial nerves connected to the brain or spinal nerves connected to the spinal cord.

Nerve Structure

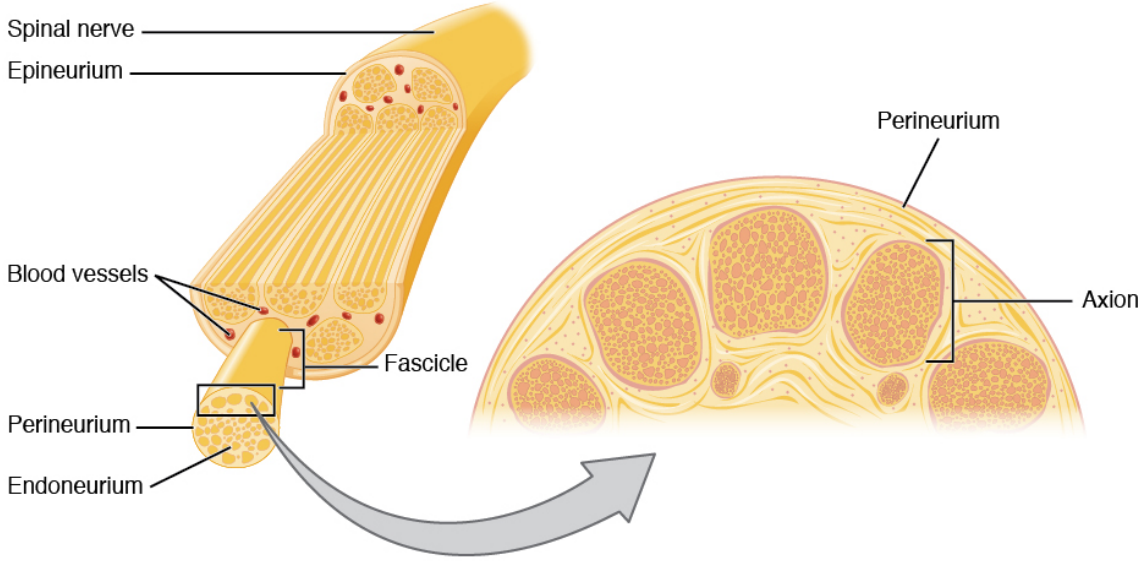

(a)

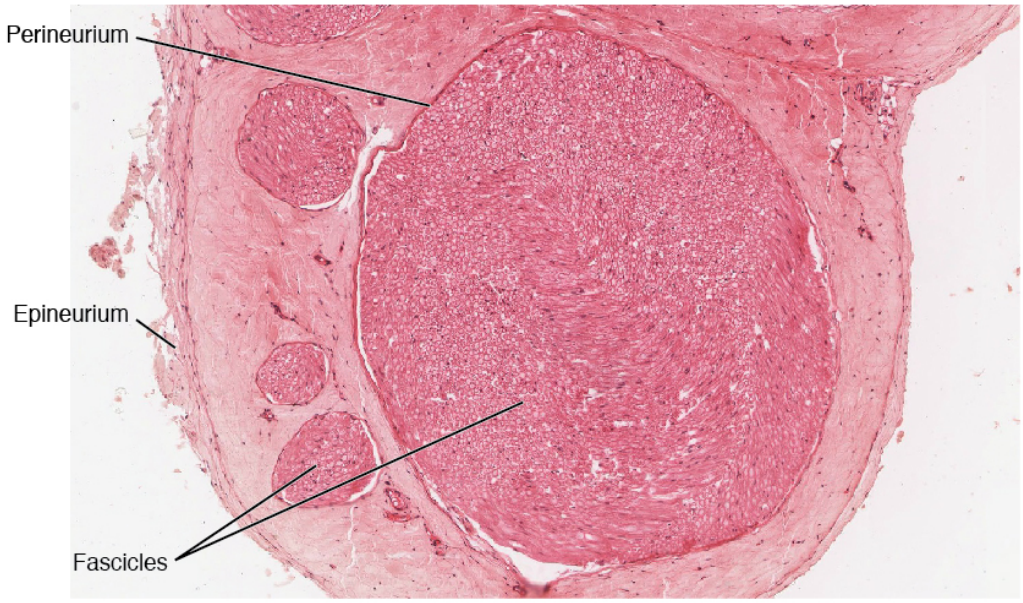

(b)

The structure of a nerve is organized by the layers of connective tissue on the outside, around each fascicle, and surrounding the individual nerve fibers (tissue source: simian). LM × 40. (Micrograph provided by the Regents of University of Michigan Medical School © 2012)

Close-Up of Nerve Trunk

Zoom in on this slide of a nerve trunk to examine the endoneurium, perineurium, and epineurium in greater detail (tissue source: simian). LM × 1600. (Micrograph provided by the Regents of University of Michigan Medical School © 2012)

Cranial Nerves

The nerves attached to the brain are the cranial nerves, which are primarily responsible for the sensory and motor functions of the head and neck .There are twelve cranial nerves, which are designated CNI through CNXII (the CN is for "Cranial Nerve"). Cranial nerves can be classified as sensory nerves, motor nerves, or a combination of both.

- **olfactory**: sense of smell.
- **optic**: vision.
- **oculomotor**: four of the extraocular muscles. lifting the upper eyelid when the eyes point up, and pupillary constriction.
- **trochlear / abducens:** each control different extraocular muscles for eye movement..
- **trigeminal**: cutaneous sensations of the face and controlling the muscles of mastication.
- **facial**: muscles involved in facial expressions, sense of taste, and salivation.
- **vestibulocochlear**: senses of hearing and balance.
- **glossopharyngeal**: oral and upper throat muscles, sense of taste, and salivation.
- **vagus**: contributes to parasympathetic control of the organs of the thoracic and upper abdominal cavities. For example it stimulates the GI tract, but decreases the heart rate.
- **spinal accessory**: controlling the muscles of the neck, along with cervical spinal nerves.
- The **hypoglossal**: controlling the muscles of the lower throat and tongue.

The Cranial Nerves

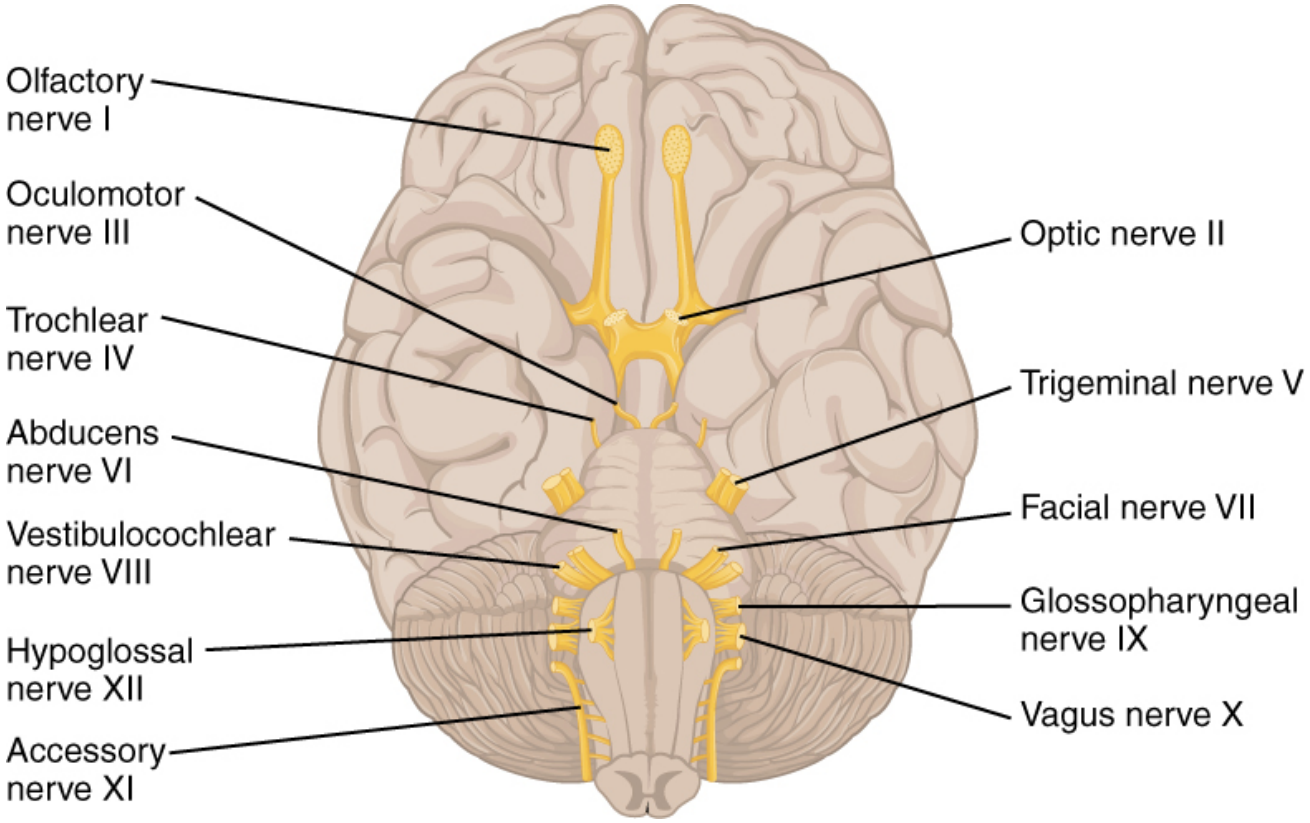

The anatomical arrangement of the roots of the cranial nerves

- ❑ The first, second, and eighth nerves are purely sensory: the olfactory (CNI), optic (CNII), and vestibulocochlear (CNVIII) nerves.
- ❑ The three eye-movement nerves are all motor: the oculomotor (CNIII), trochlear (CNIV), and abducens (CNVI).
- ❑ The spinal accessory (CNXI) and hypoglossal (CNXII) nerves are also strictly motor.
- ❑ The remainder of the nerves contain both sensory and motor fibers. They are the trigeminal (CNV), facial (CNVII), glossopharyngeal (CNIX), and vagus (CNX) nerves.
    - ❑ The nerves that convey both are often related to each other.
    - ❑ The trigeminal and facial nerves both concern the face; one concerns the sensations and the other concerns the muscle movements.
    - ❑ The facial and glossopharyngeal nerves are both responsible for conveying gustatory, or taste, sensations as well as controlling salivary glands.
    - ❑ The vagus nerve is involved in visceral responses to taste, namely the gag reflex.

Cranial Nerves S = Sensory M = Motor B = Both sensory and motor (sensorimotor)					
Mnemonic	#	Name	Function (S/M/B)	Central connection (nuclei)	Peripheral connection (ganglion or muscle)

On	I	Olfactory	Smell (S)	Olfactory bulb	Olfactory epithelium
Old	II	Optic	Vision (S)	Hypothalamus/thalamus/midbrain	Retina (retinal ganglion cells)
Olympus'	III	Oculomotor	Eye movements (M)	Oculomotor nucleus	Extraocular muscles (other 4), levator palpebrae superioris, ciliary ganglion (autonomic)
Towering	IV	Trochlear	Eye movements (M)	Trochlear nucleus	Superior oblique muscle
Tops	V	Trigeminal	Sensory/motor – face (B)	Trigeminal nuclei in the midbrain, pons, and medulla	Trigeminal
A	VI	Abducens	Eye movements (M)	Abducens nucleus	Lateral rectus muscle
Finn	VII	Facial	Motor – face, Taste (B)	Facial nucleus, solitary nucleus, superior salivatory nucleus	Facial muscles, Geniculate ganglion, Pterygopalatine ganglion (autonomic)
And	VIII	Auditory (Vestibulocochlear)	Hearing/balance (S)	Cochlear nucleus, Vestibular nucleus/cerebellum	Spiral ganglion (hearing), Vestibular ganglion (balance)
German	IX	Glossopharyngeal	Motor – throat Taste (B)	Solitary nucleus, inferior salivatory nucleus, nucleus ambiguus	Pharyngeal muscles, Geniculate ganglion, Otic ganglion (autonomic)
Viewed	X	Vagus	Motor/sensory – viscera (autonomic) (B)	Medulla	Terminal ganglia serving thoracic and upper abdominal organs (heart and small intestines)
Some	XI	Spinal Accessory	Motor – head and neck (M)	Spinal accessory nucleus	Neck muscles
Hops	XII	Hypoglossal	Motor – lower throat (M)	Hypoglossal nucleus	Muscles of the larynx and lower pharynx

Spinal Nerves

There are 31 spinal nerves, named for the level of the spinal cord at which each one emerges. There are eight pairs of cervical nerves designated C1 to C8, twelve thoracic nerves designated T1 to T12, five pairs of lumbar nerves designated L1 to L5, five pairs of sacral nerves designated S1 to S5, and one pair of coccygeal nerves.

Nerve Plexuses

Axons from different spinal nerves will come together into a systemic nerve plexus.
There are four main nerve plexuses in the human body. The cervical plexus supplies nerves to the posterior head and neck, as well as to the diaphragm. The brachial plexus supplies nerves to the arm. The lumbar plexus supplies nerves to the anterior leg. The sacral plexus supplies nerves to the posterior leg.

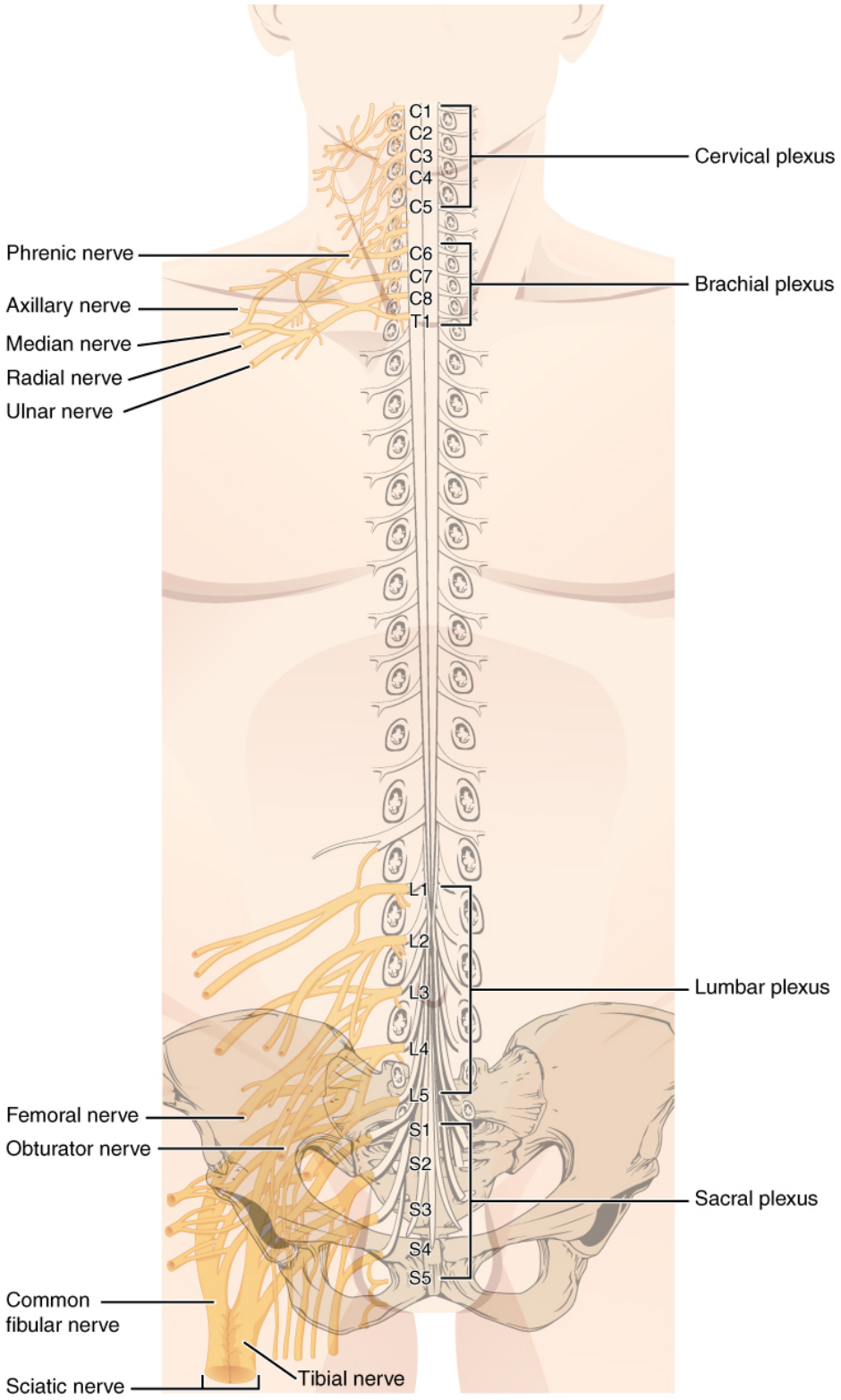

AGING AND THE…Nervous System

Anosmia is the loss of the sense of smell. It is often the result of the olfactory nerve being severed, usually because of blunt force trauma to the head. The sensory neurons of the olfactory epithelium have a limited lifespan of approximately one to four months, and new ones are made on a regular basis. The new neurons extend their axons into the CNS by growing along the existing fibers of the olfactory nerve. The ability of these neurons to be replaced is lost with age. Age-related anosmia is not the result of impact trauma to the head, but rather a slow loss of the sensory neurons with no new neurons born to replace them.

Smell is an important sense, especially for the enjoyment of food. There are only five tastes sensed by the tongue, and two of them are generally thought of as unpleasant tastes (sour and bitter). The rich sensory experience of food is the result of odor molecules associated with the food, both as food is moved into the mouth, and therefore passes under the nose, and when it is chewed and molecules are released to move up the pharynx into the posterior nasal cavity. Anosmia results in a loss of the enjoyment of food.

As the replacement of olfactory neurons declines with age, anosmia can set in. Without the sense of smell, many sufferers complain of food tasting bland. Often, the only way to enjoy food is to add seasoning that can be sensed on the tongue, which usually means adding table salt. The problem with this solution, however, is that this increases sodium intake, which can lead to cardiovascular problems through water retention and the associated increase in blood pressure.

Divisions of the Autonomic Nervous System

Besides the CNS and PNS, the nervous system can be divided into two other functional parts: the somatic nervous system and the autonomic nervous system.

- ❑ The somatic nervous system causes contraction of skeletal muscles.
- ❑ The autonomic nervous system controls cardiac and smooth muscle, as well as glandular tissue.

The somatic nervous system is associated with voluntary responses (though many can happen without conscious awareness, like breathing), and the autonomic nervous system is associated with involuntary responses, such as those related to homeostasis.

The autonomic nervous system regulates many of the internal organs through a balance of two aspects, or divisions. In addition to the endocrine system, the autonomic nervous system is instrumental in homeostatic mechanisms in the body. The two divisions of the autonomic nervous system are the sympathetic division and the parasympathetic division. The sympathetic system is associated with the fight-or-flight response, and parasympathetic activity is referred to by the epithet of rest and digest. Homeostasis is the balance between the two systems. At each target effector, dual innervation determines activity. For example, the heart receives connections from both the sympathetic and parasympathetic divisions. One causes heart rate to increase, whereas the other causes heart rate to decrease.

Sympathetic Division of the Autonomic Nervous System

To respond to a threat—to fight or to run away—the sympathetic system causes divergent effects as many different effector organs are activated together for a common purpose. More oxygen needs to be inhaled and delivered to skeletal muscle. The respiratory, cardiovascular, and musculoskeletal systems are all activated together. Additionally, sweating keeps the excess heat that comes from muscle contraction

from causing the body to overheat. The digestive system shuts down so that blood is not absorbing nutrients when it should be delivering oxygen to skeletal muscles. To coordinate all these responses, the connections in the sympathetic system diverge from a limited region of the central nervous system (CNS) to a wide array of ganglia that project to the many effector organs simultaneously. The complex set of structures that compose the output of the sympathetic system make it possible for these disparate effectors to come together in a coordinated, systemic change.

A diagram that shows the connections of the sympathetic system is somewhat like a circuit diagram that shows the electrical connections between different receptacles and devices.

Connections of Sympathetic Division of the Autonomic Nervous System

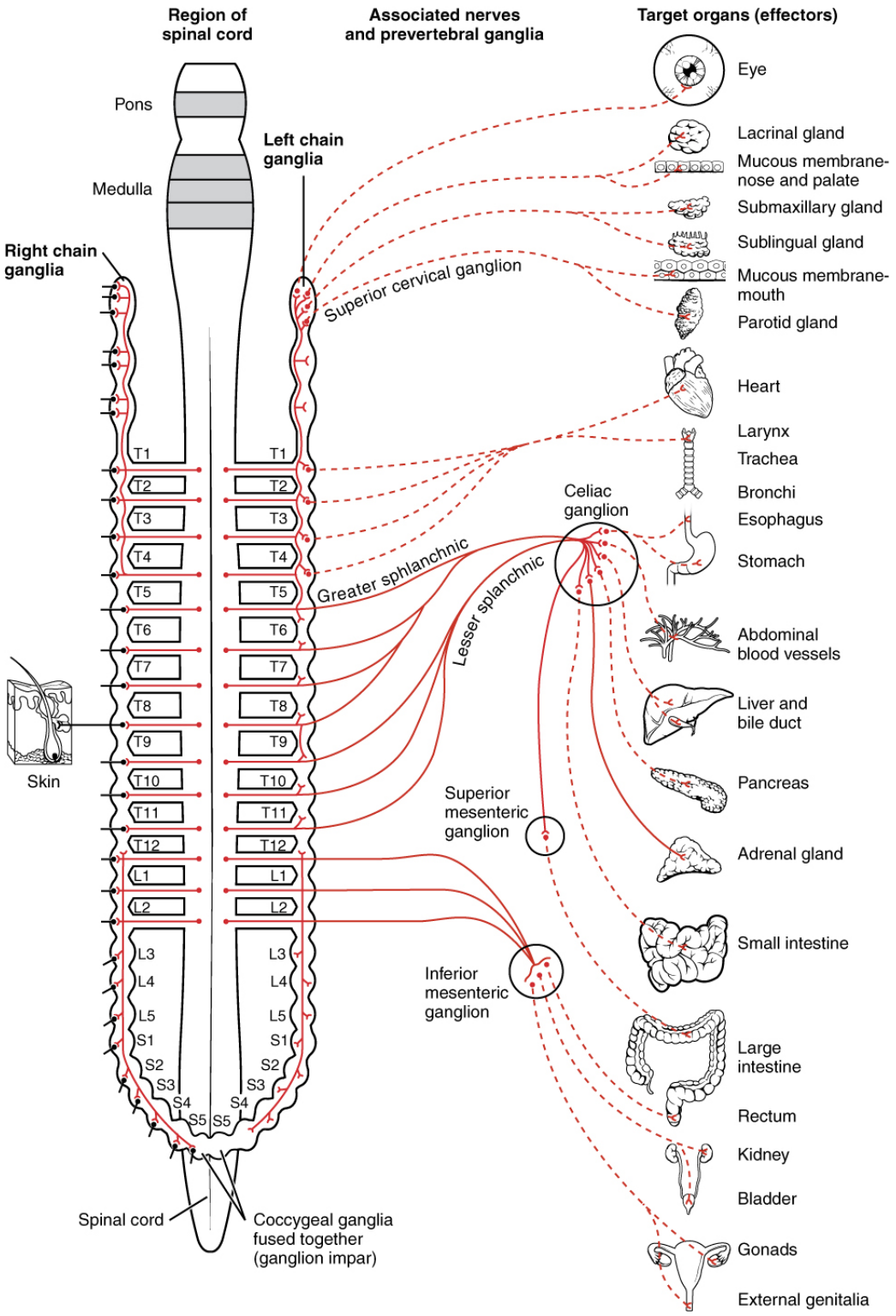

Connections of Parasympathetic Division of the Autonomic Nervous System

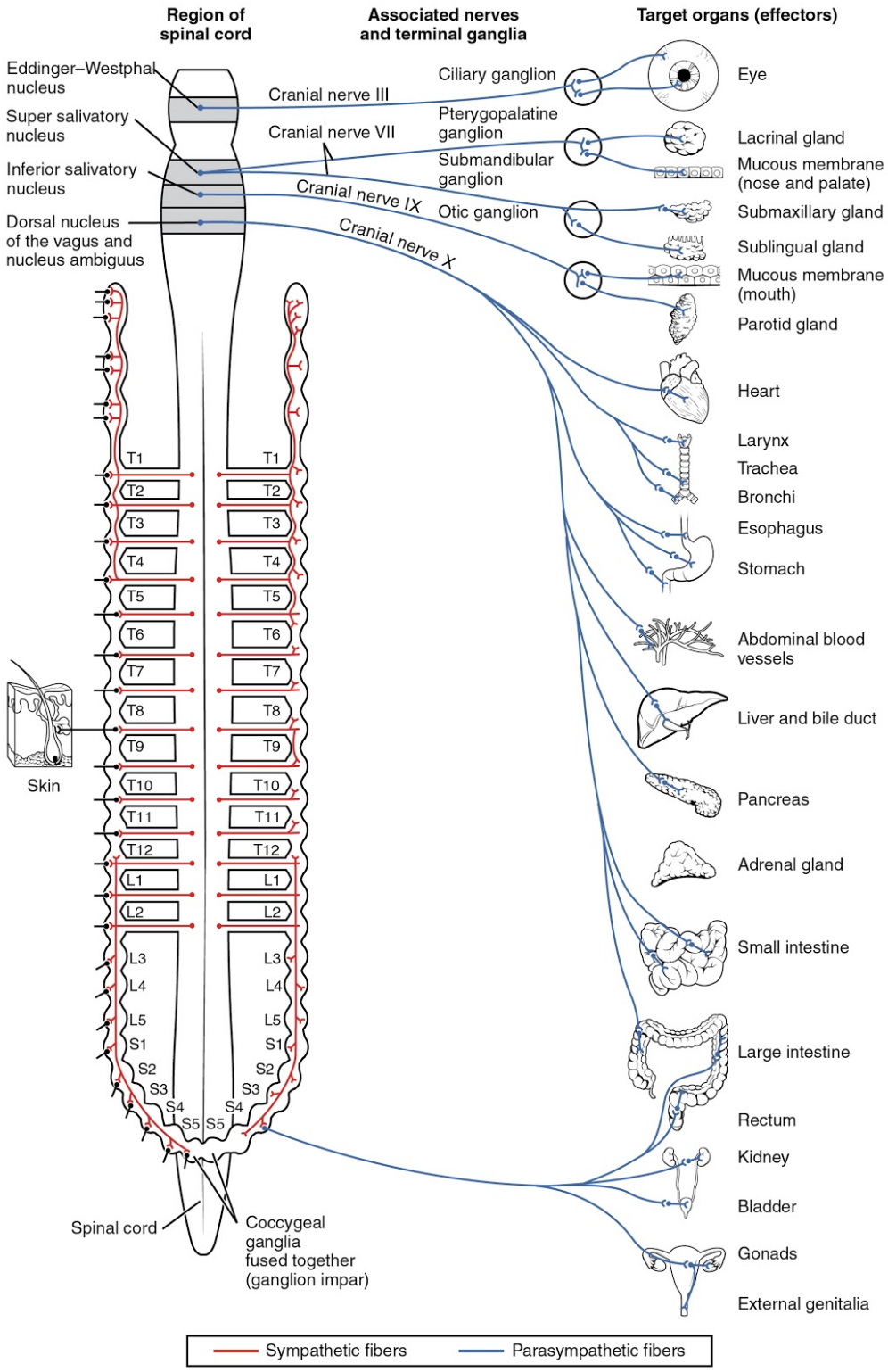

Sensory Perception

A major role of sensory receptors is to help us learn about the environment around us, or about the state of our internal environment. Stimuli from varying sources, and of different types, are received and changed into the electrochemical signals of the nervous system. This occurs when a stimulus changes the cell membrane potential of a sensory neuron. The stimulus causes the sensory cell to produce an action potential that is relayed into the central nervous system (CNS), where it is integrated with other sensory information—or sometimes higher cognitive functions—to become a conscious perception of that stimulus. The central integration may then lead to a motor response.

Describing sensory function with the term sensation or perception is a deliberate distinction.

- ❑ Sensation is the *activation of sensory receptor cells at the level of the stimulus.*
- ❑ Perception is *the central processing of sensory stimuli into a meaningful pattern*.

Perception is dependent on sensation, but not all sensations are perceived. Receptors are the cells or structures that detect sensations. A receptor cell is changed directly by a stimulus.

Sensory Receptors

Stimuli in the environment activate specialized receptor cells in the peripheral nervous system. Different types of stimuli are sensed by different types of receptor cells. Receptor cells can be classified into types on the basis of three different criteria: cell type, position, and function. Receptors can be classified structurally on the basis of cell type and their position in relation to stimuli they sense. They can also be classified functionally on the basis of the transduction of stimuli, or how the mechanical stimulus, light, or chemical changed the cell membrane potential.

Structural Receptor Types

The cells that interpret information about the environment can be either

- ❑ a neuron that has a free nerve ending, with dendrites embedded in tissue that would receive a sensation;
- ❑ a neuron that has an encapsulated ending in which the sensory nerve endings are encapsulated in connective tissue that enhances their sensitivity; or
- ❑ a specialized receptor cell, which has distinct structural components that interpret a specific type of stimulus
    - ❑ The pain and temperature receptors in the dermis of the skin are examples of neurons that have free nerve endings. Also located in the dermis of the skin are lamellated corpuscles, neurons with encapsulated nerve endings that respond to pressure and touch. The cells in the retina that respond to light stimuli are an example of a specialized receptor, a photoreceptor.

Receptor Classification by Cell Type

Receptor cell types can be classified on the basis of their structure. Sensory neurons can have either (a) free nerve endings or (b) encapsulated endings. Photoreceptors in the eyes, such as rod cells, are examples of (c) specialized receptor cells. These cells release neurotransmitters onto a bipolar cell, which then synapses with the optic nerve neurons.

Functional Receptor Types

A third classification of receptors is by how the receptor transduces stimuli into membrane potential changes. For humans, the only electromagnetic energy that is perceived by our eyes is visible light. Some other organisms have receptors that humans lack, such as the heat sensors of snakes, the ultraviolet light sensors of bees, or magnetic receptors in migratory birds.

Receptor cells can be further categorized on the basis of the type of stimuli they transduce. Chemical stimuli can be interpreted by a chemoreceptor that interprets chemical stimuli, such as an object's taste or smell. Osmoreceptors respond to solute concentrations of body fluids. Additionally, pain is primarily a chemical sense that interprets the presence of chemicals from tissue damage, or similar intense stimuli, through a nociceptor. Physical stimuli, such as pressure and vibration, as well as the sensation of sound and body position (balance), are interpreted through a mechanoreceptor. Another physical stimulus that has its own type of receptor is temperature, which is sensed through a thermoreceptor that is either sensitive to temperatures above (heat) or below (cold) normal body temperature.

Sensory Modalities

Ask anyone what the senses are, and they are likely to list the five major senses—taste, smell, touch, hearing, and sight. However, these are not all of the senses. The most obvious omission from this list is balance. Also, what is referred to simply as touch can be further subdivided into pressure, vibration, stretch, and hair-follicle position, on the basis of the type of mechanoreceptors that perceive these touch sensations. Other overlooked senses include temperature perception by thermoreceptors and pain perception by nociceptors.

Within the realm of physiology, senses can be classified as either general or specific. A general sense is one that is distributed throughout the body and has receptor cells within the structures of other organs. Mechanoreceptors in the skin, muscles, or the walls of blood vessels are examples of this type. General senses often contribute to the sense of touch, as described above, or to proprioception (body movement) and kinesthesia (body movement), or to a visceral sense, which is most important to autonomic functions. A special sense is one that has a specific organ devoted to it, namely the eye, inner ear, tongue, or nose.

Each of the senses is referred to as a sensory modality. Modality refers to the way that information is encoded, which is similar to the idea of transduction. The main sensory modalities can be described on the basis of how each is transduced. The chemical senses are taste and smell. The general sense that is usually referred to as touch includes chemical sensation in the form of nociception, or pain. Pressure, vibration, muscle stretch, and the movement of hair by an external stimulus, are all sensed by mechanoreceptors. Hearing and balance are also sensed by mechanoreceptors. Finally, vision involves the

activation of photoreceptors.

Gustation (Taste)

Only a few recognized submodalities exist within the sense of taste, or gustation. Until recently, only four tastes were recognized:

- ❑ Sweet
- ❑ Salty
- ❑ Sour
- ❑ Bitter

Research at the turn of the 20th century led to recognition of the fifth taste, umami, during the mid-1980s. Umami is a Japanese word that means "delicious taste," and is often translated to mean savory. Very recent research has suggested that there may also be a sixth taste for fats, or lipids.

Gustation is the special sense associated with the tongue. The surface of the tongue, along with the rest of the oral cavity, is lined by a stratified squamous epithelium. Raised bumps called papillae (singular = papilla) contain the structures for gustatory transduction. Receptor cells are sensitive to the chemicals contained within foods that are ingested, and they release neurotransmitters based on the amount of the chemical in the food. Neurotransmitters from the gustatory cells can activate sensory neurons in the facial, glossopharyngeal, and vagus cranial nerves.

The Tongue

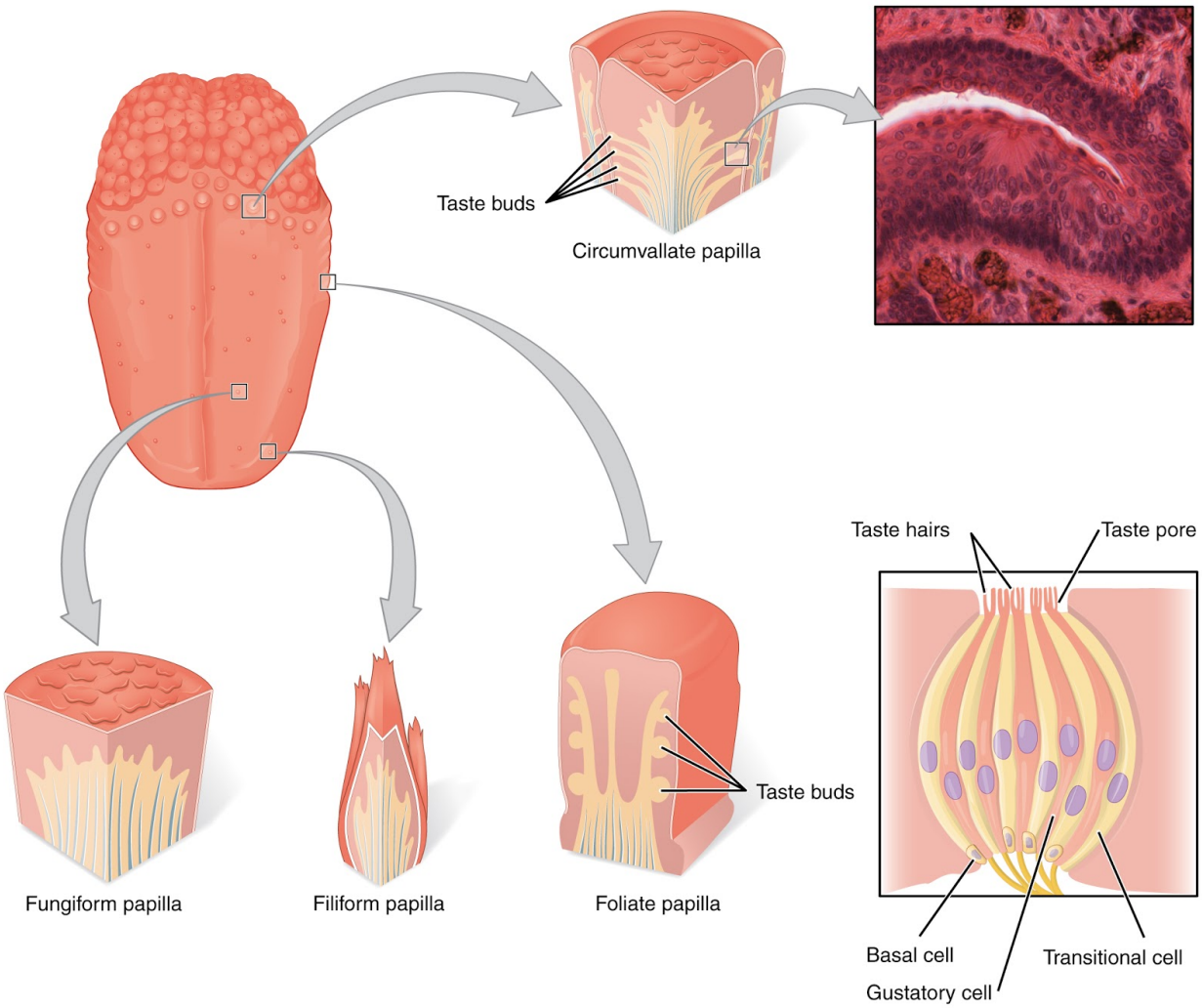

(Micrograph provided by the Regents of University of Michigan Medical School © 2012)

The tongue is covered with small bumps, called papillae, which contain taste buds that are sensitive to chemicals in ingested food or drink. Different types of papillae are found in different regions of the tongue. The taste buds contain specialized gustatory receptor cells that respond to chemical stimuli dissolved in the saliva. These receptor cells activate sensory neurons that are part of the facial and glossopharyngeal nerves.

- Salty taste is simply the perception of sodium ions (Na+) in the saliva. When you eat something salty, the salt crystals dissociate into the component ions Na+ and Cl–, which dissolve into the saliva in your mouth. The Na+ concentration becomes high outside the gustatory cells, creating a strong concentration gradient that drives the diffusion of the ion into the cells. The entry of Na+ into these cells results in the depolarization of the cell membrane and the generation of a receptor potential.
- Sour taste is the perception of H+ concentration. Just as with sodium ions in salty flavors, these hydrogen ions enter the cell and trigger depolarization. Sour flavors are, essentially, the perception of acids in our food. Increasing hydrogen ion concentrations in the saliva (lowering saliva pH) triggers progressively stronger graded potentials in the gustatory cells. For example, orange juice—which contains citric acid—will taste sour because it has a pH value of approximately 3. Of course, it is often sweetened so that the sour taste is masked.
- The sweet taste is the sensitivity of gustatory cells to the presence of glucose dissolved in the saliva.
    - fructose, or artificial sweeteners such as aspartame (NutraSweet™), saccharine, or sucralose (Splenda™) also activate the sweet receptors. The affinity for each of these molecules varies, and some will taste sweeter than glucose because they bind to the G protein–coupled receptor differently.
- Bitter taste is similar to sweet in that food molecules bind to G protein–coupled receptors. However, there are a number of different ways in which this can happen because there are a large diversity of bitter-tasting molecules.
    - One major group of bitter-tasting molecules are alkaloids. Alkaloids are nitrogen containing molecules that are commonly found in bitter-tasting plant products, such as coffee, hops (in beer), tannins (in wine), tea, and aspirin.

Olfaction (Smell)

Like taste, the sense of smell, or olfaction, is also responsive to chemical stimuli. The olfactory receptor neurons are located in a small region within the superior nasal cavity (Figure). This region is referred to as the olfactory epithelium and contains bipolar sensory neurons. Each olfactory sensory neuron has dendrites that extend from the apical surface of the epithelium into the mucus lining the cavity. As airborne molecules are inhaled through the nose, they pass over the olfactory epithelial region and

dissolve into the mucus. These odorant molecules bind to proteins that keep them dissolved in the mucus and help transport them to the olfactory dendrites. The odorant–protein complex binds to a receptor protein within the cell membrane of an olfactory dendrite. These receptors are G protein–coupled, and will produce a graded membrane potential in the olfactory neurons.

The axon of an olfactory neuron extends from the basal surface of the epithelium, through an olfactory foramen in the cribriform plate of the ethmoid bone, and into the brain. The group of axons called the olfactory tract connect to the olfactory bulb on the ventral surface of the frontal lobe. Smell is the one sensory modality that does not synapse in the thalamus before connecting to the cerebral cortex. This intimate connection between the olfactory system and the cerebral cortex is one reason why smell can be a potent trigger of memories and emotion.

- ❑ The nasal epithelium, including the olfactory cells, can be harmed by airborne toxic chemicals. Therefore, the olfactory neurons are regularly replaced within the nasal epithelium, after which the axons of the new neurons must find their appropriate connections in the olfactory bulb. These new axons grow along the axons that are already in place in the cranial nerve.

The Olfactory System

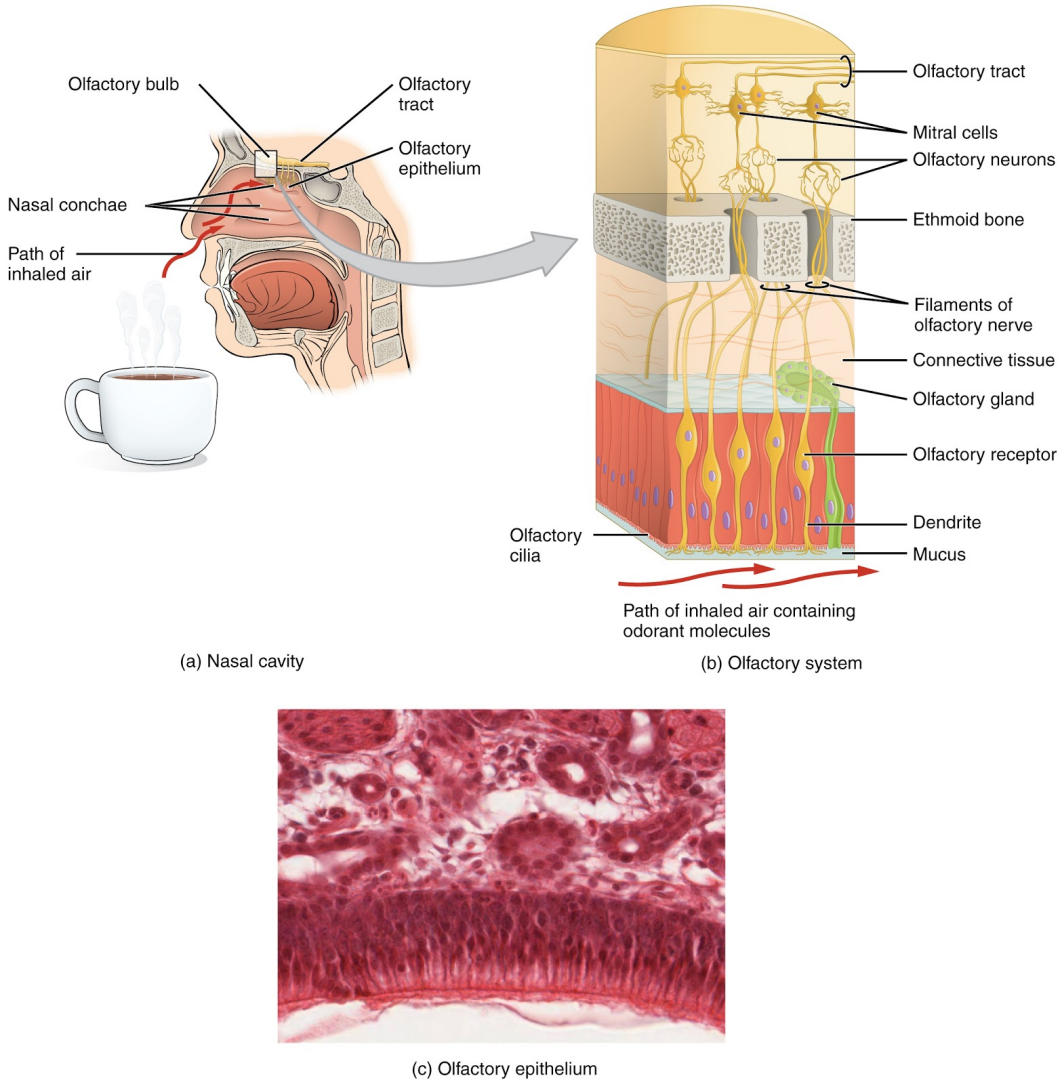

(a) The olfactory system begins in the peripheral structures of the nasal cavity. (b) The olfactory receptor neurons are within the olfactory epithelium. (c) Axons of the olfactory receptor neurons project through the cribriform plate of

the ethmoid bone and synapse with the neurons of the olfactory bulb (tissue source: simian). LM × 812. (Micrograph provided by the Regents of University of Michigan Medical School © 2012)

DISORDERS OF THE…Olfactory System: Anosmia

Blunt force trauma to the face, such as that common in many car accidents, can lead to the loss of the olfactory nerve, and subsequently, loss of the sense of smell. This condition is known as anosmia. When the frontal lobe of the brain moves relative to the ethmoid bone, the olfactory tract axons may be sheared apart. Professional fighters often experience anosmia because of repeated trauma to face and head. In addition, certain pharmaceuticals, such as antibiotics, can cause anosmia by killing all the olfactory neurons at once. If no axons are in place within the olfactory nerve, then the axons from newly formed olfactory neurons have no guide to lead them to their connections within the olfactory bulb. There are temporary causes of anosmia, as well, such as those caused by inflammatory responses related to respiratory infections or allergies.

Loss of the sense of smell can result in food tasting bland. A person with an impaired sense of smell may require additional spice and seasoning levels for food to be tasted. Anosmia may also be related to some presentations of mild depression, because the loss of enjoyment of food may lead to a general sense of despair.

The ability of olfactory neurons to replace themselves decreases with age, leading to age-related anosmia. This explains why some elderly people salt their food more than younger people do. However, this increased sodium intake can increase blood volume and blood pressure, increasing the risk of cardiovascular diseases in the elderly.

Audition (Hearing)

Hearing, or audition, is the transduction of sound waves into a neural signal that is made possible by the structures of the ear. The visible ear is known as the auricle. Some sources will also refer to this structure as the pinna, though that term is more appropriate for a structure that can be moved, such as the external ear of a cat. The C-shaped curves of the auricle direct sound waves toward the auditory canal. The canal enters the skull through the external auditory meatus of the temporal bone. At the end of the auditory canal is the tympanic membrane, or ear drum, which vibrates after it is struck by sound waves. The auricle, ear canal, and tympanic membrane are often referred to as the external ear. The middle ear consists of a space spanned by three small bones called the ossicles. The three ossicles are the malleus, incus, and stapes, which are Latin names that roughly translate to hammer, anvil, and stirrup.

- ❑ The malleus is attached to the tympanic membrane and articulates with the incus.
- ❑ The incus, in turn, articulates with the stapes.
- ❑ The stapes is then attached to the inner ear, where the sound waves will be transduced into a neural signal.

The middle ear is connected to the pharynx through the Eustachian tube, which helps equilibrate air pressure across the tympanic membrane. The tube is normally closed but will pop open when the muscles of the pharynx contract during swallowing or yawning, which is why we do that to equalize the pressure on the middle ear while flying to O`ahu, for instance.

Structures of the Ear

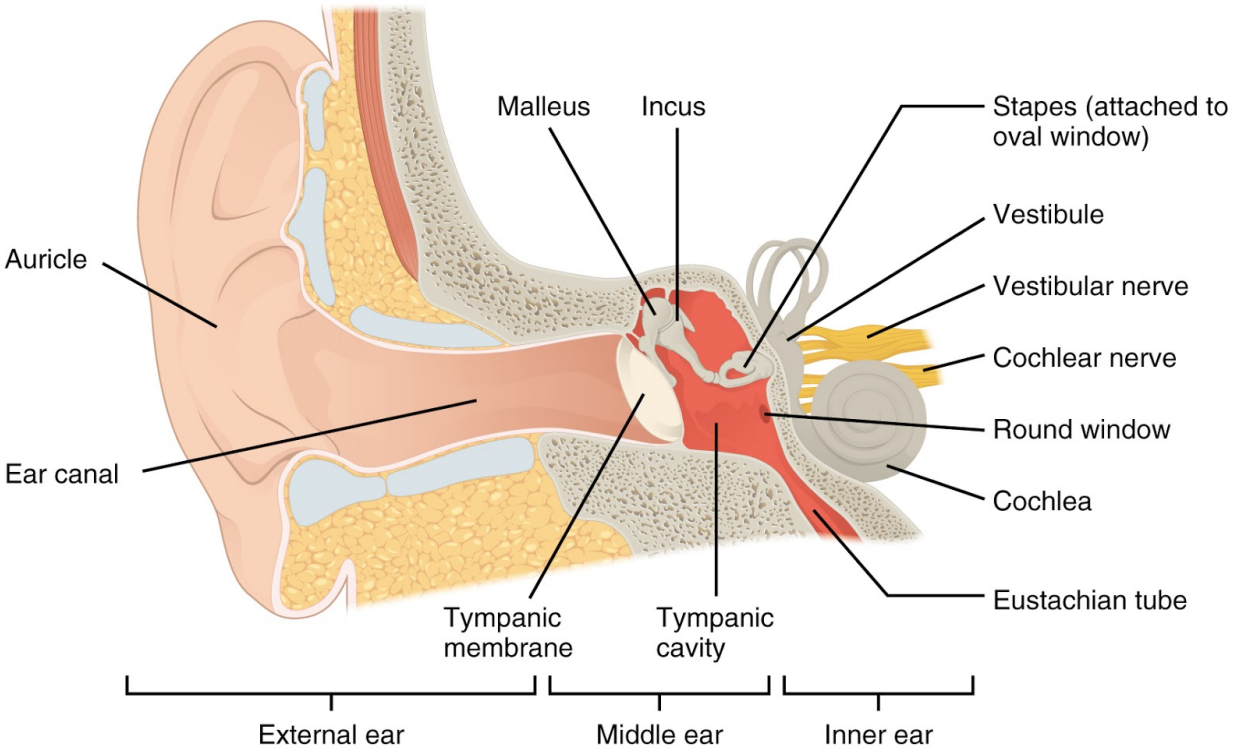

❑ The external ear contains the auricle, ear canal, and tympanic membrane. The middle ear contains the ossicles and is connected to the pharynx by the Eustachian tube. The inner ear contains the cochlea and vestibule, which are responsible for audition and equilibrium, respectively.

The inner ear is often described as a bony labyrinth, as it is composed of a series of canals embedded within the temporal bone. It has two separate regions, the cochlea and the vestibule, which are responsible for hearing and balance, respectively. The neural signals from these two regions are relayed to the brain stem through separate fiber bundles. However, these two distinct bundles travel together from the inner ear to the brain stem as the vestibulocochlear nerve. Sound is transduced into neural signals within the cochlear region of the inner ear, which contains the sensory neurons of the spiral ganglia. These ganglia are located within the spiral-shaped cochlea of the inner ear. The cochlea is attached to the stapes through the oval window.

The oval window is located at the beginning of a fluid-filled tube within the cochlea called the scala vestibuli. As vibrations of the ossicles travel through the oval window, the fluid of the scala vestibuli and scala tympani moves in a wave-like motion. The frequency of the fluid waves match the frequencies of the sound waves (Figure). The membrane covering the round window will bulge out or pucker in with the movement of the fluid within the scala tympani.

Transmission of Sound Waves to Cochlea

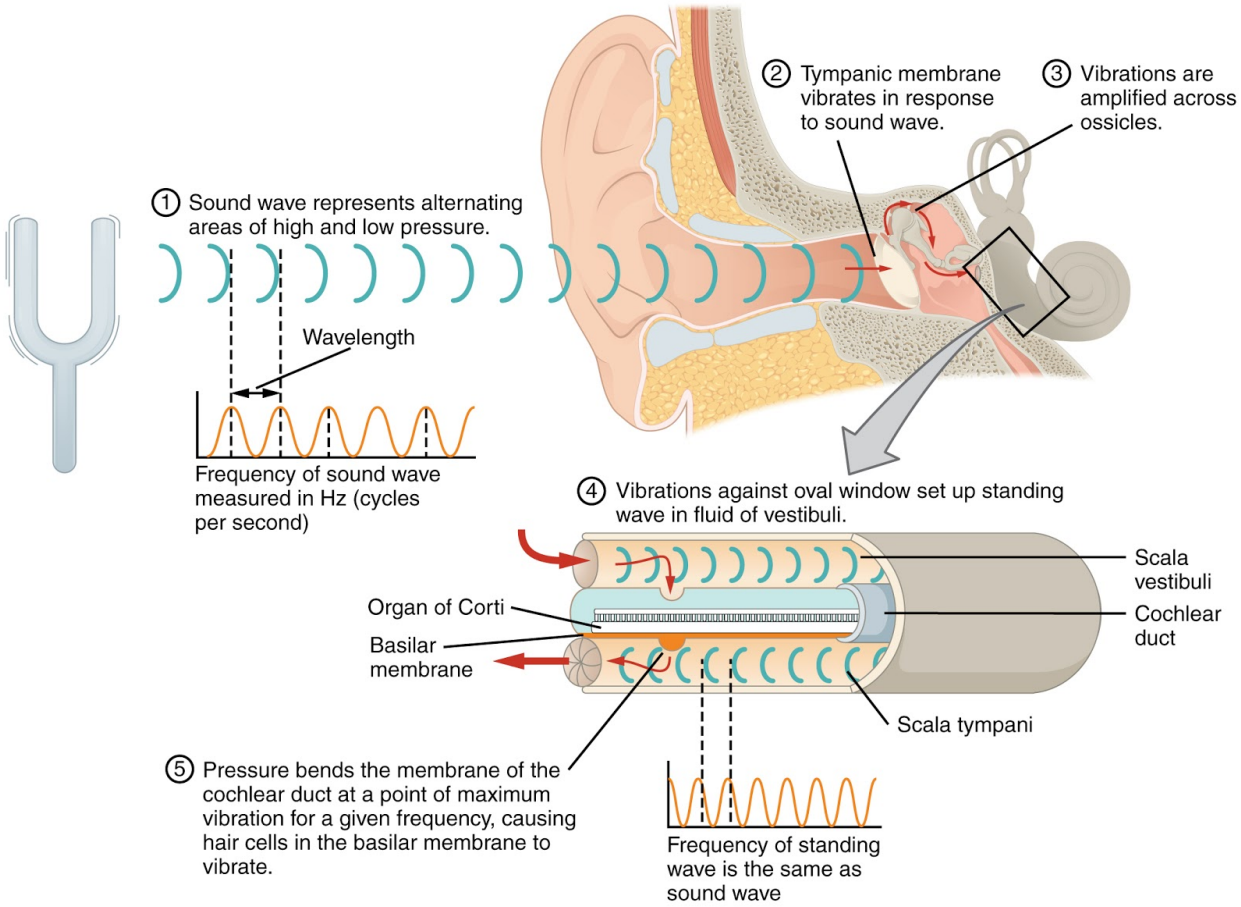

A

sound wave causes the tympanic membrane to vibrate. This vibration is amplified as it moves across the malleus, incus, and stapes. The amplified vibration is picked up by the oval window causing pressure waves in the fluid of the scala vestibuli and scala tympani.

Cross Section of the Cochlea

The scala tympani and scala vestibuli lie on either side of the cochlear duct.

The organ of Corti, containing the mechanoreceptor hair cells, is adjacent to the scala tympani, where it sits atop the basilar membrane.

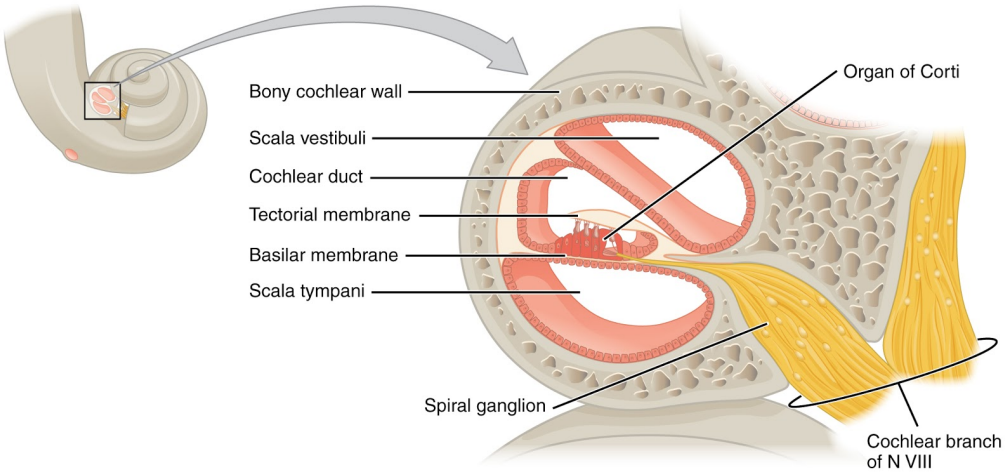

The organs of Corti contain hair cells called stereocillia. Protein fibers tether adjacent hairs together within each array, such that the array will bend in response to movements of the basilar membrane. When the pressure waves from the scala move the basilar membrane, the tectorial membrane slides across the stereocilia. This bends the stereocilia either toward or away from the tallest member of each array. When the stereocilia bend toward the tallest member of their array, tension in the protein tethers opens ion channels in the hair cell membrane. This will depolarize the hair cell membrane, triggering nerve impulses that travel down the afferent nerve fibers attached to the hair cells. When the

stereocilia bend toward the shortest member of their array, the tension on the tethers slackens and the ion channels close. When no sound is present, and the stereocilia are standing straight, a small amount of tension still exists on the tethers, keeping the membrane potential of the hair cell slightly depolarized.

Hair Cell

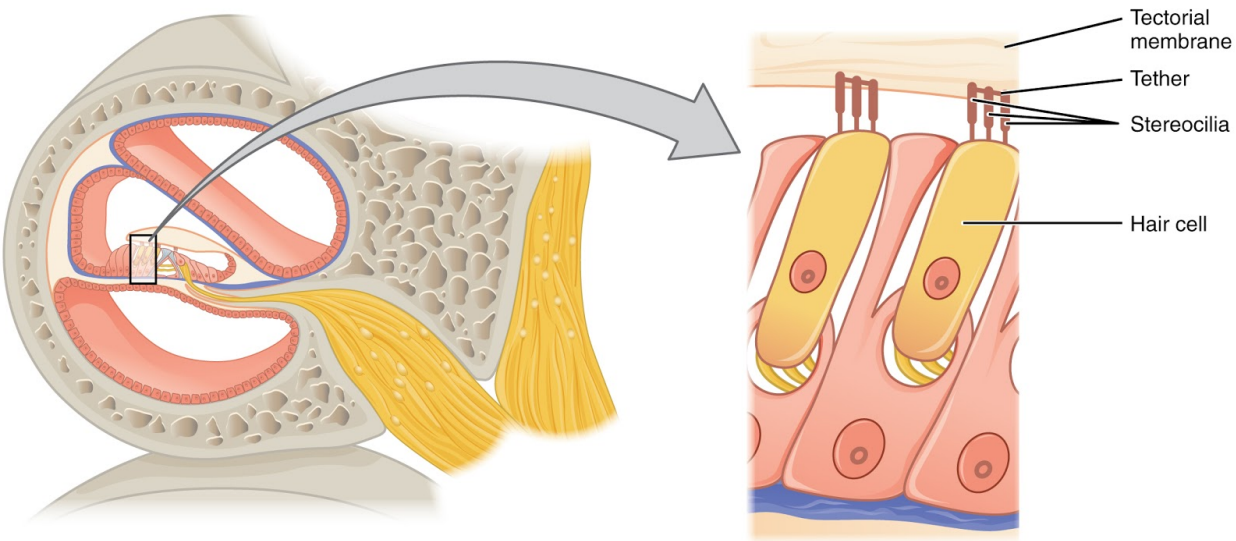

The hair cell is a mechanoreceptor with an array of stereocilia emerging from its apical surface. The stereocilia are tethered together by proteins that open ion channels when the array is bent toward the tallest member of their array, and closed when the array is bent toward the shortest member of their array.

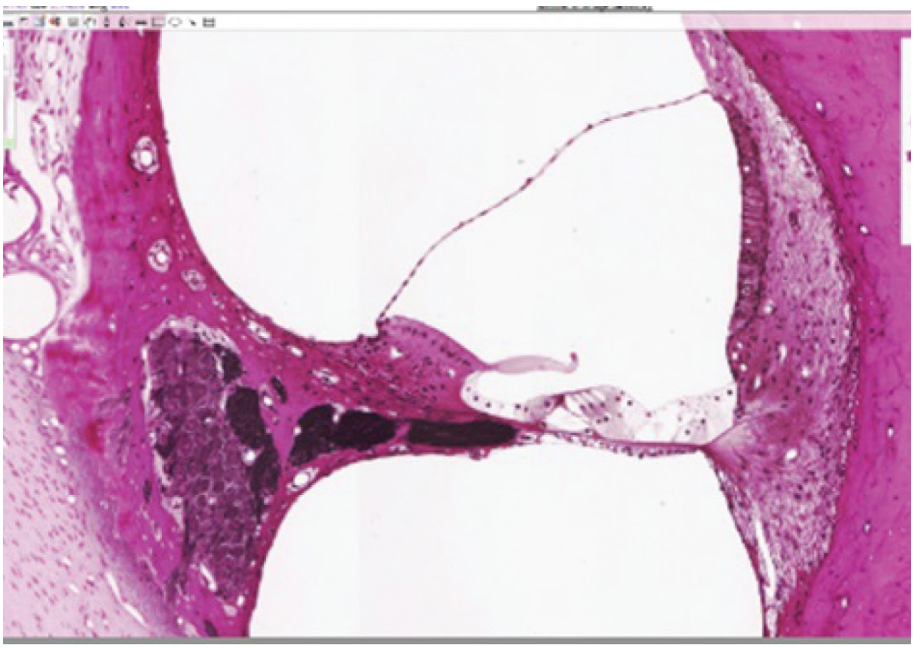

Micrograph showing the cross-section of the cochlea

(Micrograph provided by the Regents of University of Michigan Medical School © 2012)

Equilibrium (Balance)

Along with audition, the inner ear is responsible for encoding information about equilibrium, the sense of balance. A similar mechanoreceptor—a hair cell with stereocilia—senses head position, head movement, and whether our bodies are in motion. These cells are located within the vestibule of the inner ear. Head position is sensed by the utricle and saccule, whereas head movement is sensed by the semicircular canals. The neural signals generated in the vestibular ganglion are transmitted through the

vestibulocochlear nerve to the brain stem and cerebellum.

The utricle and saccule are both largely composed of macula tissue (plural = maculae). The macula is composed of hair cells surrounded by support cells. The stereocilia of the hair cells extend into a viscous gel called the otolithic membrane (Figure). On top of the otolithic membrane is a layer of calcium carbonate crystals, called otoliths. The otoliths essentially make the otolithic membrane top-heavy. The otolithic membrane moves separately from the macula in response to head movements. Tilting the head causes the otolithic membrane to slide over the macula in the direction of gravity.

Linear Acceleration Coding by Maculae

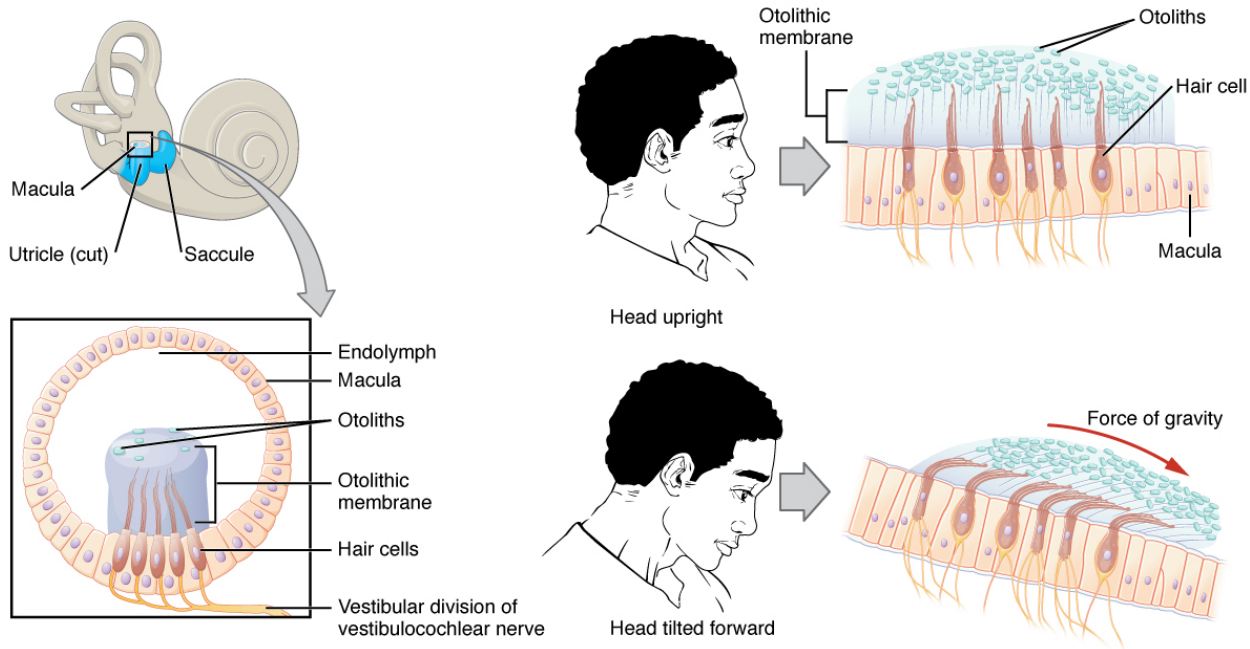

The maculae are specialized for sensing linear acceleration, such as when gravity acts on the tilting head, or if the head starts moving in a straight line. The difference in inertia between the hair cell stereocilia and the otolithic membrane in which they are embedded leads to a shearing force that causes the stereocilia to bend in the direction of that linear acceleration.

The semicircular canals are three ring-like extensions of the vestibule. One is oriented in the horizontal plane, whereas the other two are oriented in the vertical plane. The anterior and posterior vertical canals are oriented at approximately 45 degrees relative to the sagittal plane (Figure). The base of each semicircular canal, where it meets with the vestibule, connects to an enlarged region known as the ampulla. The ampulla contains the hair cells that respond to rotational movement, such as turning the head while saying “no.” The stereocilia of these hair cells extend into the cupula, a membrane that attaches to the top of the ampulla. As the head rotates in a plane parallel to the semicircular canal, the fluid lags, deflecting the cupula in the direction opposite to the head movement. The semicircular canals contain several ampullae, with some oriented horizontally and others oriented vertically. By comparing the relative movements of both the horizontal and vertical ampullae, the vestibular system can detect the direction of most head movements within three-dimensional (3-D) space.

Rotational Coding by Semicircular Canals

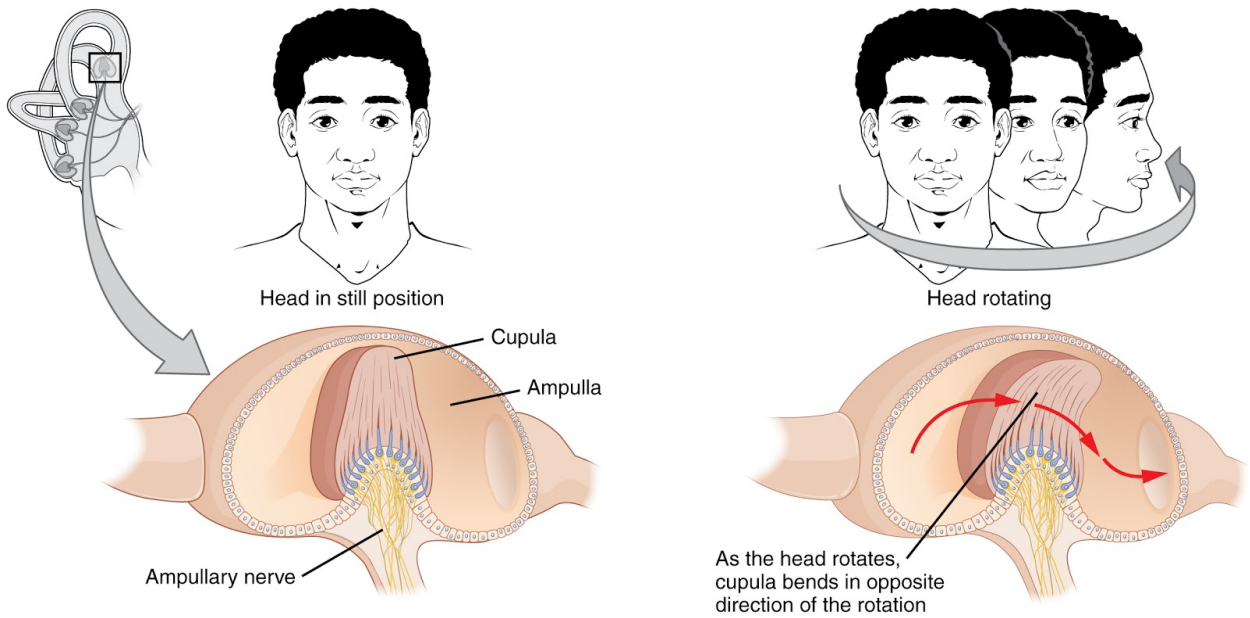

Rotational movement of the head is encoded by the hair cells in the base of the semicircular canals. As one of the canals moves in an arc with the head, the internal fluid moves in the opposite direction, causing the cupula and stereocilia to bend. The movement of two canals within a plane results in information about the direction in which the head is moving, and activation of all six canals can give a very precise indication of head movement in three dimensions.

Vision

Vision is the special sense of sight that is based on the transduction of light stimuli received through the eyes. The eyes are located within either orbit in the skull. The bony orbits surround the eyeballs, protecting them and anchoring the soft tissues of the eye (Figure). The eyelids, with lashes at their leading edges, help to protect the eye from abrasions by blocking particles that may land on the surface of the eye. The inner surface of each lid is a thin membrane known as the palpebral conjunctiva. The conjunctiva extends over the white areas of the eye (the sclera), connecting the eyelids to the eyeball. Tears are produced by the lacrimal gland, located beneath the lateral edges of the nose. Tears produced by this gland flow through the lacrimal duct to the medial corner of the eye, where the tears flow over the conjunctiva, washing away foreign particles.

The Eye in the Orbit

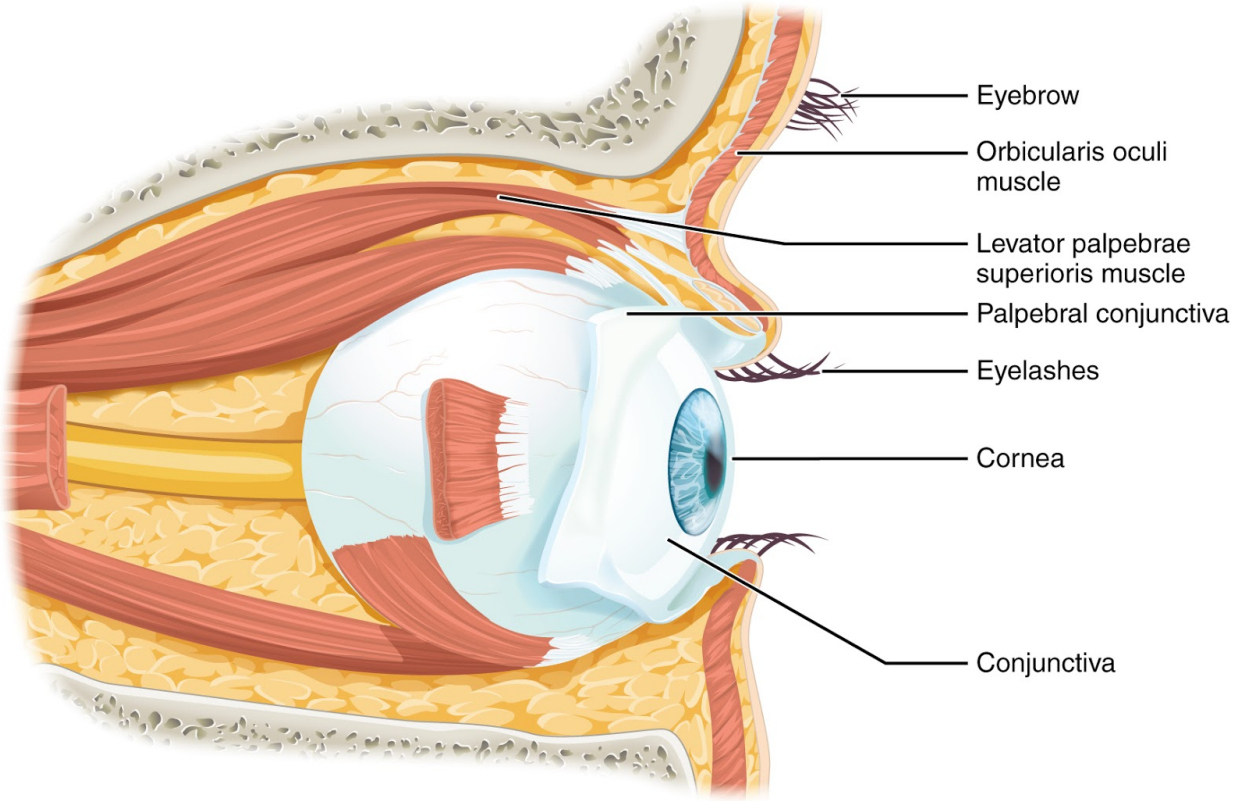

The eye is located within the orbit and surrounded by soft tissues that protect and support its function. The orbit is surrounded by cranial bones of the skull.

Movement of the eye within the orbit is accomplished by the contraction of six extraocular muscles that originate from the bones of the orbit and insert into the surface of the eyeball (Figure). Four of the muscles are arranged at the cardinal points around the eye and are named for those locations. They are the superior rectus, medial rectus, inferior rectus, and lateral rectus. When each of these muscles contract, the eye to moves toward the contracting muscle. For example, when the superior rectus contracts, the eye rotates to look up. The superior oblique originates at the posterior orbit, near the origin of the four rectus muscles. However, the tendon of the oblique muscles threads through a pulley-like piece of cartilage known as the trochlea. The tendon inserts obliquely into the superior surface of the eye. The angle of the tendon through the trochlea means that contraction of the superior oblique rotates the eye medially. The inferior oblique muscle originates from the floor of the orbit and inserts into the inferolateral surface of the eye. When it contracts, it laterally rotates the eye, in opposition to the superior oblique. Rotation of the eye by the two oblique muscles is necessary because the eye is not perfectly aligned on the sagittal plane. When the eye looks up or down, the eye must also rotate slightly to compensate for the superior rectus pulling at approximately a 20-degree angle, rather than straight up. The same is true for the inferior rectus, which is compensated by contraction of the inferior oblique. A seventh muscle in the orbit is the levator palpebrae superioris, which is responsible for elevating and retracting the upper eyelid, a movement that usually occurs in concert with elevation of the eye by the superior rectus (see Figure).

The extraocular muscles are innervated by three cranial nerves. The lateral rectus, which causes abduction of the eye, is innervated by the abducens nerve. The superior oblique is innervated by the

trochlear nerve. All of the other muscles are innervated by the oculomotor nerve, as is the levator palpebrae superioris. The motor nuclei of these cranial nerves connect to the brain stem, which coordinates eye movements.

Extraocular Muscles

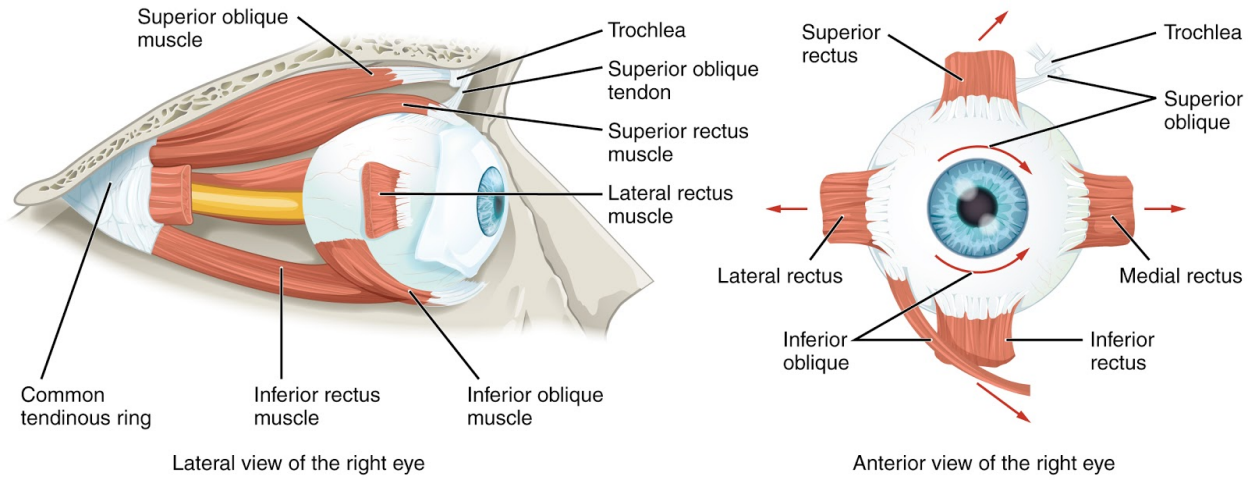

The extraocular muscles move the eye within the orbit.

Structure of the Eyeball

The eye itself is a hollow sphere composed of three layers of tissue.

- The outermost layer is the fibrous tunic, which includes the white sclera and clear cornea. The sclera accounts for five sixths of the surface of the eye, most of which is not visible, though humans are unique compared with many other species in having so much of the "white of the eye" visible.The transparent cornea covers the anterior tip of the eye and allows light to enter the eye.
- The middle layer of the eye is the vascular tunic, which is mostly composed of the choroid, ciliary body, and iris. The choroid is a layer of highly vascularized connective tissue that provides a blood supply to the eyeball. The choroid is posterior to the ciliary body, a muscular structure that is attached to the lens by suspensory ligaments, or zonule fibers. These two structures bend the lens, allowing it to focus light on the back of the eye. Overlaying the ciliary body, and visible in the anterior eye, is the iris—the colored part of the eye. The iris is a smooth muscle that opens or closes the pupil, which is the hole at the center of the eye that allows light to enter. The iris constricts the pupil in response to bright light and dilates the pupil in response to dim light.
- The innermost layer of the eye is the neural tunic, or retina, which contains the nervous tissue responsible for photoreception.

The eye is also divided into two cavities: the anterior cavity and the posterior cavity. The anterior cavity is the space between the cornea and lens, including the iris and ciliary body. It is filled with a watery fluid called the aqueous humor. The posterior cavity is the space behind the lens that extends to the posterior side of the interior eyeball, where the retina is located. The posterior cavity is filled with a more viscous fluid called the vitreous humor.

The Retina

The retina is composed of several layers and contains specialized cells for the initial processing of visual stimuli. The photoreceptors (rods and cones) change their membrane potential when stimulated by light energy. The change in membrane potential alters the amount of neurotransmitter that the photoreceptor cells release onto bipolar cells in the outer synaptic layer. It is the bipolar cell in the retina that connects a photoreceptor to a retinal ganglion cell (RGC) in the inner synaptic layer. There, amacrine cells additionally contribute to retinal processing before an action potential is produced by the RGC. The axons of RGCs, which lie at the innermost layer of the retina, collect at the optic disc and leave the eye as the optic nerve (see Figure). Because these axons pass through the retina, there are no photoreceptors at the very back of the eye, where the optic nerve begins. This creates a "blind spot" in the retina, and a corresponding blind spot in our visual field.

Structure of the Eye

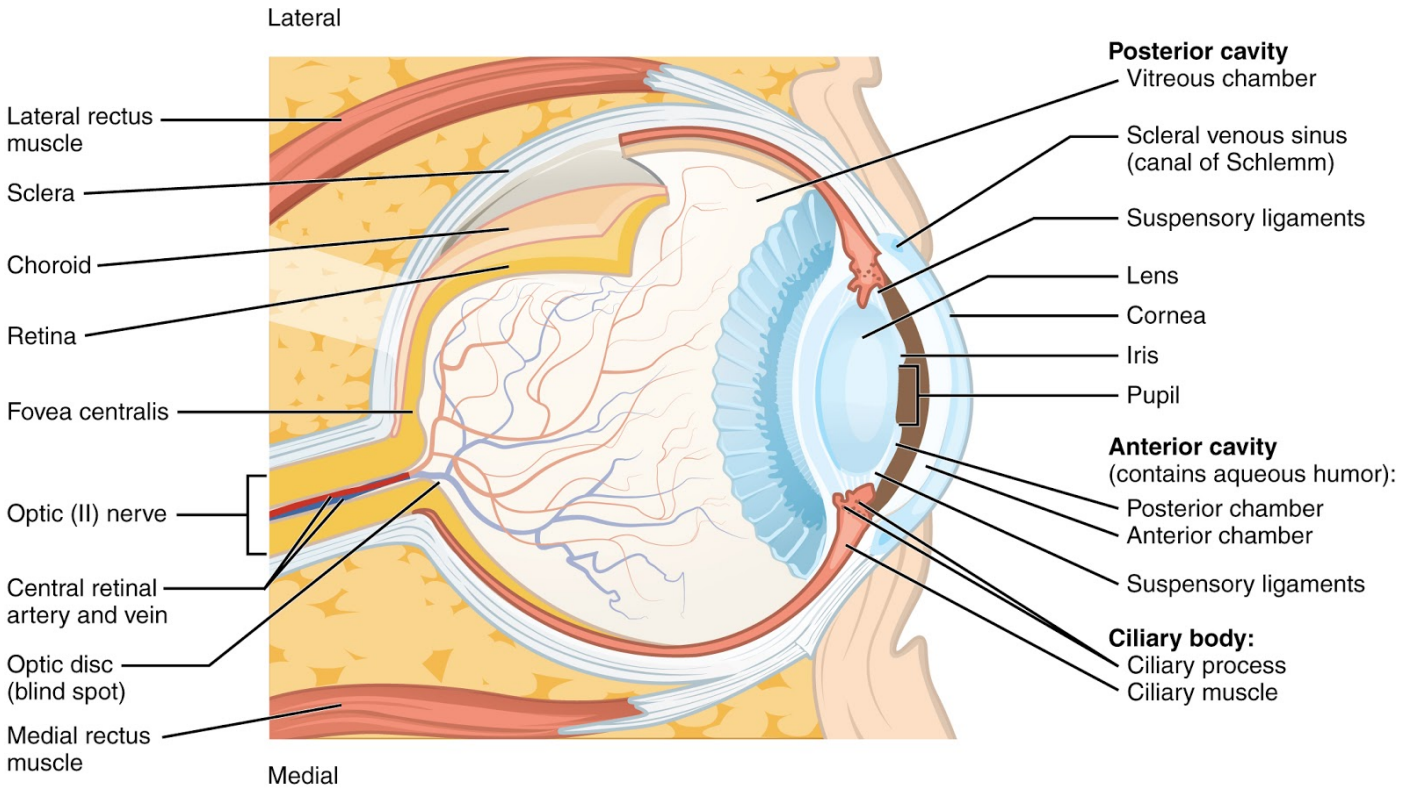

The sphere of the eye can be divided into anterior and posterior chambers. The wall of the eye is composed of three layers: the fibrous tunic, vascular tunic, and neural tunic. Within the neural tunic is the retina, with three layers of cells and two synaptic layers in between. The center of the retina has a small indentation known as the fovea.

Note that the photoreceptors in the retina (rods and cones) are located behind the axons, RGCs, bipolar cells, and retinal blood vessels. A significant amount of light is absorbed by these structures before the light reaches the photoreceptor cells. However, at the exact center of the retina is a small area known as the fovea. At the fovea, the retina lacks the supporting cells and blood vessels, and only contains photoreceptors. Therefore, visual acuity, or the sharpness of vision, is greatest at the fovea. This is because the fovea is where the least amount of incoming light is absorbed by other retinal structures (see Figure). As one moves in either direction from this central point of the retina, visual acuity drops significantly. In addition, each photoreceptor cell of the fovea is connected to a single RGC. Therefore,

this RGC does not have to integrate inputs from multiple photoreceptors, which reduces the accuracy of visual transduction. Toward the edges of the retina, several photoreceptors converge on RGCs (through the bipolar cells) up to a ratio of 50 to 1. The difference in visual acuity between the fovea and peripheral retina is easily evidenced by looking directly at a word in the middle of this paragraph. The visual stimulus in the middle of the field of view falls on the fovea and is in the sharpest focus. Without moving your eyes off that word, notice that words at the beginning or end of the paragraph are not in focus. The images in your peripheral vision are focused by the peripheral retina, and have vague, blurry edges and words that are not as clearly identified. As a result, a large part of the neural function of the eyes is concerned with moving the eyes and head so that important visual stimuli are centered on the fovea.

Light falling on the retina causes chemical changes to pigment molecules in the photoreceptors, ultimately leading to a change in the activity of the RGCs. Photoreceptor cells have two parts, the inner segment and the outer segment (Figure). The inner segment contains the nucleus and other common organelles of a cell, whereas the outer segment is a specialized region in which photoreception takes place. There are two types of photoreceptors—rods and cones—which differ in the shape of their outer segment. The rod-shaped outer segments of the rod photoreceptor contain a stack of membrane-bound discs that contain the photosensitive pigment rhodopsin. The cone-shaped outer segments of the cone photoreceptor contain their photosensitive pigments in infoldings of the cell membrane. There are three cone photopigments, called opsins, which are each sensitive to a particular wavelength of light. The wavelength of visible light determines its color. The pigments in human eyes are specialized in perceiving three different primary colors: red, green, and blue.

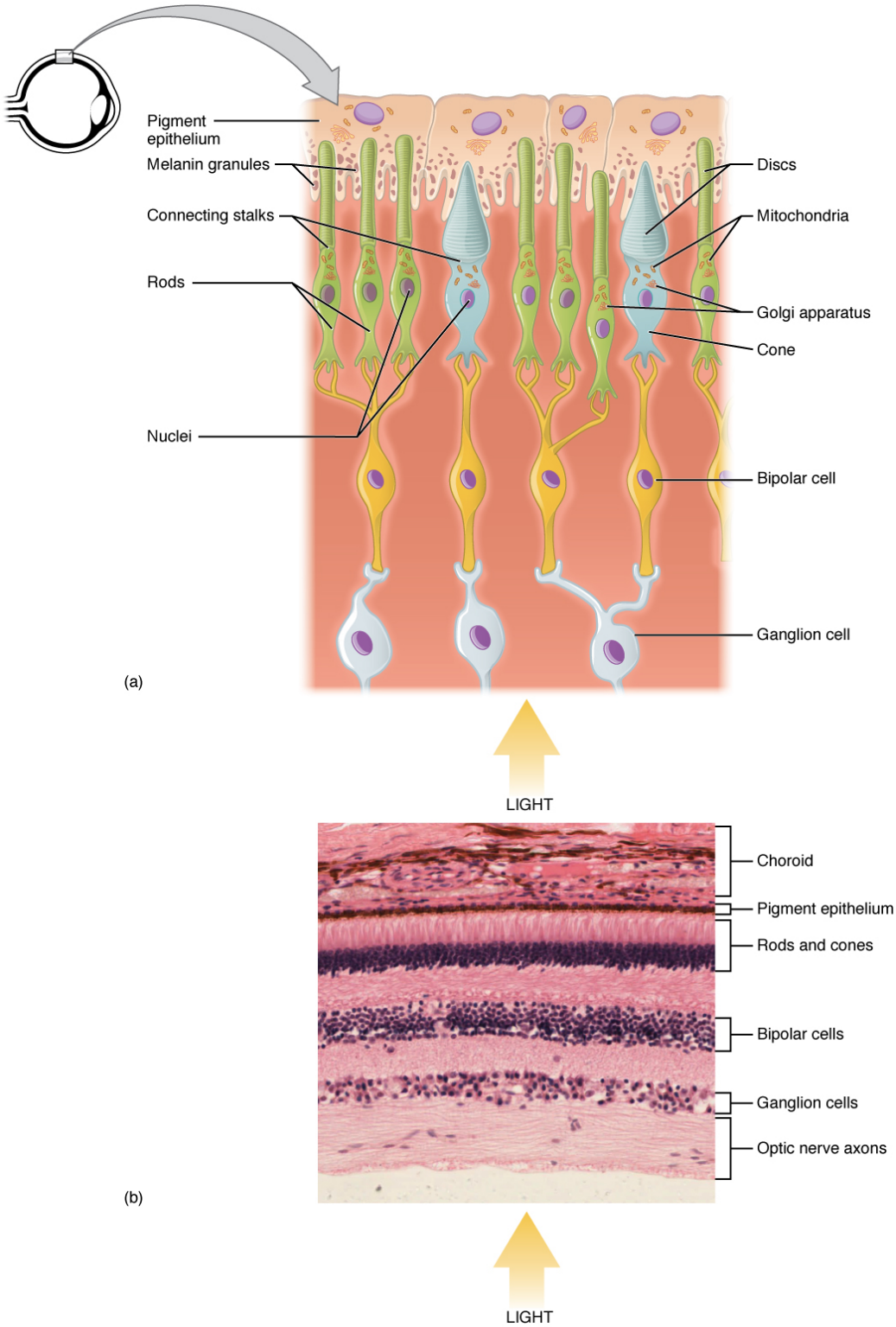

(Micrograph provided by the Regents of University of Michigan Medical School © 2012)

Somatosensation (Touch)

Somatosensation is considered a general sense, as opposed to the special senses discussed in this

section. Somatosensation is the group of sensory modalities that are associated with touch, proprioception, and interoception. These modalities include pressure, vibration, light touch, tickle, itch, temperature, pain, proprioception, and kinesthesia. This means that its receptors are not associated with a specialized organ, but are instead spread throughout the body in a variety of organs. Many of the somatosensory receptors are located in the skin, but receptors are also found in muscles, tendons, joint capsules, ligaments, and in the walls of visceral organs.

- ❑ Two types of somatosensory signals that are transduced by free nerve endings are pain and temperature. These two modalities use thermoreceptors and nociceptors to transduce temperature and pain stimuli, respectively.
- ❑ Temperature receptors are stimulated when local temperatures differ from body temperature. Some thermoreceptors are sensitive to just cold and others to just heat.
- ❑ Nociception is the sensation of potentially damaging stimuli. Mechanical, chemical, or thermal stimuli beyond a set threshold will elicit painful sensations. Stressed or damaged tissues release chemicals that activate receptor proteins in the nociceptors.
    - ❑ For example, the sensation of heat associated with spicy foods involves capsaicin, the active molecule in hot peppers.

Capsaicin molecules bind to a transmembrane ion channel in nociceptors that is sensitive to temperatures above 37°C. The dynamics of capsaicin binding with this transmembrane ion channel is unusual in that the molecule remains bound for a long time. Because of this, it will decrease the ability of other stimuli to elicit pain sensations through the activated nociceptor. For this reason, capsaicin can be used as a topical analgesic, such as in products such as Icy Hot™.

If you drag your finger across a textured surface, the skin of your finger will vibrate. Such low frequency vibrations are sensed by mechanoreceptors called Merkel cells, also known as type I cutaneous mechanoreceptors. Merkel cells are located in the stratum basale of the epidermis. Deep pressure and vibration is transduced by lamellated (Pacinian) corpuscles, which are receptors with encapsulated endings found deep in the dermis, or subcutaneous tissue. Light touch is transduced by the encapsulated endings known as tactile (Meissner) corpuscles. Follicles are also wrapped in a plexus of nerve endings known as the hair follicle plexus. These nerve endings detect the movement of hair at the surface of the skin, such as when an insect may be walking along the skin. Stretching of the skin is transduced by stretch receptors known as bulbous corpuscles. Bulbous corpuscles are also known as Ruffini corpuscles, or type II cutaneous mechanoreceptors.

Other somatosensory receptors are found in the joints and muscles. Stretch receptors monitor the stretching of tendons, muscles, and the components of joints. For example, have you ever stretched your

muscles before or after exercise and noticed that you can only stretch so far before your muscles spasm back to a less stretched state? This spasm is a reflex that is initiated by stretch receptors to avoid muscle tearing. Such stretch receptors can also prevent over-contraction of a muscle. In skeletal muscle tissue, these stretch receptors are called muscle spindles. Golgi tendon organs similarly transduce the stretch levels of tendons. Bulbous corpuscles are also present in joint capsules, where they measure stretch in the components of the skeletal system within the joint. The types of nerve endings, their locations, and the stimuli they transduce are presented in Table.

Mechanoreceptors of Somatosensation			
Name	Historical (eponymous) name	Location(s)	Stimuli
Free nerve endings	*	Dermis, cornea, tongue, joint capsules, visceral organs	Pain, temperature, mechanical deformation
Mechanoreceptors	Merkel's discs	Epidermal–dermal junction, mucosal membranes	Low frequency vibration (5–15 Hz)
Bulbous corpuscle	Ruffini's corpuscle	Dermis, joint capsules	Stretch
Tactile corpuscle	Meissner's corpuscle	Papillary dermis, especially in the fingertips and lips	Light touch, vibrations below 50 Hz
Lamellated corpuscle	Pacinian corpuscle	Deep dermis, subcutaneous tissue	Deep pressure, high-frequency vibration (around 250 Hz)
Hair follicle plexus	*	Wrapped around hair follicles in the dermis	Movement of hair
Muscle spindle	*	In line with skeletal muscle fibers	Muscle contraction and stretch
Tendon stretch organ	Golgi tendon organ	In line with tendons	Stretch of tendons

Glossary

Central Nervous System

alar plate: developmental region of the spinal cord that gives rise to the posterior horn of the gray matter

amygdala: nucleus deep in the temporal lobe of the cerebrum that is related to memory and emotional behavior

anterior column: white matter between the anterior horns of the spinal cord composed of many different groups of axons of both ascending and descending tracts

anterior horn: gray matter of the spinal cord containing multipolar motor neurons, sometimes referred to as the ventral horn

anterior median fissure: deep midline feature of the anterior spinal cord, marking the separation between the right and left sides of the cord

ascending tract: central nervous system fibers carrying sensory information from the spinal cord or periphery to the brain

basal forebrain: nuclei of the cerebrum related to modulation of sensory stimuli and attention through broad projections to the cerebral cortex, loss of which is related to Alzheimer's disease

basal nuclei: nuclei of the cerebrum (with a few components in the upper brain stem and diencephalon) that are responsible for assessing cortical movement commands and comparing them with the general state of the individual through broad modulatory activity of dopamine neurons; largely related to motor functions, as evidenced through the symptoms of Parkinson's and Huntington's diseases

basal plate: developmental region of the spinal cord that gives rise to the lateral and anterior horns of gray matter

Broca's area: region of the frontal lobe associated with the motor commands necessary for speech production and located only in the cerebral hemisphere responsible for language production, which is the left side in approximately 95 percent of the population

Brodmann's areas: mapping of regions of the cerebral cortex based on microscopic anatomy that relates specific areas to functional differences, as described by Brodmann in the early 1900s

cauda equina: bundle of spinal nerve roots that descend from the lower spinal cord below the first lumbar vertebra and lie within the vertebral cavity; has the appearance of a horse's tail

caudate: nucleus deep in the cerebrum that is part of the basal nuclei; along with the putamen, it is part of the striatum

central sulcus: surface landmark of the cerebral cortex that marks the boundary between the frontal and parietal lobes

cerebral cortex: outer gray matter covering the forebrain, marked by wrinkles and folds known as gyri and sulci

cerebrum: region of the adult brain that develops from the telencephalon and is responsible for higher neurological functions such as memory, emotion, and consciousness

cerebellum: region of the adult brain connected primarily to the pons that developed from the metencephalon (along with the pons) and is largely responsible for comparing information from the cerebrum with sensory feedback from the periphery through the spinal cord

cerebral hemisphere: one half of the bilaterally symmetrical cerebrum

corpus callosum: large white matter structure that connects the right and left cerebral hemispheres

descending tract: central nervous system fibers carrying motor commands from the brain to the spinal cord or periphery

direct pathway: connections within the basal nuclei from the striatum to the globus pallidus internal segment and substantia nigra pars reticulata that disinhibit the thalamus to increase cortical control of movement

disinhibition: disynaptic connection in which the first synapse inhibits the second cell, which then stops inhibiting the final target

dorsal (posterior) nerve root: axons entering the posterior horn of the spinal cord

epithalamus: region of the diecephalon containing the pineal gland

frontal eye field: region of the frontal lobe associated with motor commands to orient the eyes toward an object of visual attention

frontal lobe: region of the cerebral cortex directly beneath the frontal bone of the cranium

globus pallidus: nuclei deep in the cerebrum that are part of the basal nuclei and can be divided into the internal and external segments

gyrus: ridge formed by convolutions on the surface of the cerebrum or cerebellum

hippocampus: gray matter deep in the temporal lobe that is very important for long-term memory formation

hypothalamus: major region of the diencephalon that is responsible for coordinating autonomic and endocrine control of homeostasis

indirect pathway: connections within the basal nuclei from the striatum through the globus pallidus external segment and subthalamic nucleus to the globus pallidus internal segment/substantia nigra pars compacta that result in inhibition of the thalamus to decrease cortical control of movement

inferior colliculus: half of the midbrain tectum that is part of the brain stem auditory pathway

inferior olive: nucleus in the medulla that is involved in processing information related to motor control

kinesthesia: general sensory perception of movement of the body

lateral column: white matter of the spinal cord between the posterior horn on one side and the axons from the anterior horn on the same side; composed of many different groups of axons, of both ascending and descending tracts, carrying motor commands to and from the brain

lateral horn: region of the spinal cord gray matter in the thoracic, upper lumbar, and sacral regions that is the central component of the sympathetic division of the autonomic nervous system

lateral sulcus: surface landmark of the cerebral cortex that marks the boundary between the temporal lobe and the frontal and parietal lobes

limbic cortex: collection of structures of the cerebral cortex that are involved in emotion, memory, and behavior and are part of the larger limbic system

limbic system: structures at the edge (limit) of the boundary between the forebrain and hindbrain that are most associated with emotional behavior and memory formation

longitudinal fissure: large separation along the midline between the two cerebral hemispheres

occipital lobe: region of the cerebral cortex directly beneath the occipital bone of the cranium

olfaction: special sense responsible for smell, which has a unique, direct connection to the cerebrum

parietal lobe: region of the cerebral cortex directly beneath the parietal bone of the cranium

parieto-occipital sulcus: groove in the cerebral cortex representing the border between the parietal and occipital cortices

postcentral gyrus: ridge just posterior to the central sulcus, in the parietal lobe, where somatosensory processing initially takes place in the cerebrum

posterior columns: white matter of the spinal cord that lies between the posterior horns of the gray matter, sometimes referred to as the dorsal column; composed of axons of ascending tracts that carry sensory information up to the brain

posterior horn: gray matter region of the spinal cord in which sensory input arrives, sometimes referred to as the dorsal horn

posterior median sulcus: midline feature of the posterior spinal cord, marking the separation between right and left sides of the cord

posterolateral sulcus: feature of the posterior spinal cord marking the entry of posterior nerve roots and the separation between the posterior and lateral columns of the white matter

precentral gyrus: primary motor cortex located in the frontal lobe of the cerebral cortex

prefrontal lobe: specific region of the frontal lobe anterior to the more specific motor function areas, which can be related to the early planning of movements and intentions to the point of being personality-type functions

premotor area: region of the frontal lobe responsible for planning movements that will be executed through the primary motor cortex

proprioception: general sensory perceptions providing information about location and movement of body parts; the "sense of the self"

putamen: nucleus deep in the cerebrum that is part of the basal nuclei; along with the caudate, it is part of the striatum

reticular formation: diffuse region of gray matter throughout the brain stem that regulates sleep, wakefulness, and states of consciousness

somatosensation: general senses related to the body, usually thought of as the senses of touch, which would include pain, temperature, and proprioception

striatum: the caudate and putamen collectively, as part of the basal nuclei, which receive input from the cerebral cortex

subcortical nucleus: all the nuclei beneath the cerebral cortex, including the basal nuclei and the basal forebrain

substantia nigra pars compacta: nuclei within the basal nuclei that release dopamine to modulate the function of the striatum; part of the motor pathway

substantia nigra pars reticulata: nuclei within the basal nuclei that serve as an output center of the nuclei; part of the motor pathway

subthalamus: nucleus within the basal nuclei that is part of the indirect pathway

sulcus: groove formed by convolutions in the surface of the cerebral cortex

superior colliculus: half of the midbrain tectum that is responsible for aligning visual, auditory, and somatosensory spatial perceptions

tectum: region of the midbrain, thought of as the roof of the cerebral aqueduct, which is subdivided into the inferior and superior colliculi

tegmentum: region of the midbrain, thought of as the floor of the cerebral aqueduct, which continues into the pons and medulla as the floor of the fourth ventricle

temporal lobe: region of the cerebral cortex directly beneath the temporal bone of the cranium

thalamus: major region of the diencephalon that is responsible for relaying information between the cerebrum and the hindbrain, spinal cord, and periphery

ventral (anterior) nerve root: axons emerging from the anterior or lateral horns of the spinal cord

The Peripheral Nervous System

abducens nerve: sixth cranial nerve; responsible for contraction of one of the extraocular muscles

axillary nerve: systemic nerve of the arm that arises from the brachial plexus

brachial plexus: nerve plexus associated with the lower cervical spinal nerves and first thoracic spinal nerve

cervical plexus: nerve plexus associated with the upper cervical spinal nerves

cranial nerve: one of twelve nerves connected to the brain that are responsible for sensory or motor functions of the head and neck

cranial nerve ganglion: sensory ganglion of cranial nerves

dorsal (posterior) root ganglion: sensory ganglion attached to the posterior nerve root of a spinal nerve

endoneurium: innermost layer of connective tissue that surrounds individual axons within a nerve

enteric nervous system: peripheral structures, namely ganglia and nerves, that are incorporated into the digestive system organs

enteric plexus: neuronal plexus in the wall of the intestines, which is part of the enteric nervous system

epineurium: outermost layer of connective tissue that surrounds an entire nerve

esophageal plexus: neuronal plexus in the wall of the esophagus that is part of the enteric nervous system

extraocular muscles: six skeletal muscles that control eye movement within the orbit

facial nerve: seventh cranial nerve; responsible for contraction of the facial muscles and for part of the sense of taste, as well as causing saliva production

fascicle: small bundles of nerve or muscle fibers enclosed by connective tissue

femoral nerve: systemic nerve of the anterior leg that arises from the lumbar plexus

fibular nerve: systemic nerve of the posterior leg that begins as part of the sciatic nerve

gastric plexuses: neuronal networks in the wall of the stomach that are part of the enteric nervous system

glossopharyngeal nerve: ninth cranial nerve; responsible for contraction of muscles in the tongue and throat and for part of the sense of taste, as well as causing saliva production

hypoglossal nerve: twelfth cranial nerve; responsible for contraction of muscles of the tongue

intercostal nerve: systemic nerve in the thoracic cavity that is found between two ribs

lumbar plexus: nerve plexus associated with the lumbar spinal nerves

median nerve: systemic nerve of the arm, located between the ulnar and radial nerves

nerve plexus: network of nerves without neuronal cell bodies included

oculomotor nerve: third cranial nerve; responsible for contraction of four of the extraocular muscles, the muscle in the upper eyelid, and pupillary constriction

olfactory nerve: first cranial nerve; responsible for the sense of smell

optic nerve: second cranial nerve; responsible for visual sensation

paravertebral ganglia: autonomic ganglia superior to the sympathetic chain ganglia

perineurium: layer of connective tissue surrounding fascicles within a nerve

phrenic nerve: systemic nerve from the cervical plexus that enervates the diaphragm

plexus: network of nerves or nervous tissue

prevertebral ganglia: autonomic ganglia that are anterior to the vertebral column and functionally related to the sympathetic chain ganglia

radial nerve: systemic nerve of the arm, the distal component of which is located near the radial bone

sacral plexus: nerve plexus associated with the lower lumbar and sacral spinal nerves

saphenous nerve: systemic nerve of the lower anterior leg that is a branch from the femoral nerve

sciatic nerve: systemic nerve from the sacral plexus that is a combination of the tibial and fibular nerves and extends across the hip joint and gluteal region into the upper posterior leg

sciatica: painful condition resulting from inflammation or compression of the sciatic nerve or any of the spinal nerves that contribute to it

spinal accessory nerve: eleventh cranial nerve; responsible for contraction of neck muscles

spinal nerve: one of 31 nerves connected to the spinal cord

sympathetic chain ganglia: autonomic ganglia in a chain along the anterolateral aspect of the vertebral column that are responsible for contributing to homeostatic mechanisms of the autonomic nervous system

systemic nerve: nerve in the periphery distal to a nerve plexus or spinal nerve

terminal ganglion: autonomic ganglia that are near or within the walls of organs that are responsible for contributing to homeostatic mechanisms of the autonomic nervous system

tibial nerve: systemic nerve of the posterior leg that begins as part of the sciatic nerve

trigeminal ganglion: sensory ganglion that contributes sensory fibers to the trigeminal nerve

trigeminal nerve: fifth cranial nerve; responsible for cutaneous sensation of the face and contraction of the muscles of mastication

trochlear nerve: fourth cranial nerve; responsible for contraction of one of the extraocular muscles

ulnar nerve: systemic nerve of the arm located close to the ulna, a bone of the forearm

vagus nerve: tenth cranial nerve; responsible for the autonomic control of organs in the thoracic and upper abdominal cavities

vestibulocochlear nerve: eighth cranial nerve; responsible for the sensations of hearing and balance

Autonomic Nervous system

alpha (α)-adrenergic receptor: one of the receptors to which epinephrine and norepinephrine bind, which comes in three subtypes: α1, α2, and α3

acetylcholine (ACh): neurotransmitter that binds at a motor end-plate to trigger depolarization

adrenal medulla: interior portion of the adrenal (or suprarenal) gland that releases epinephrine and norepinephrine into the bloodstream as hormones

adrenergic: synapse where norepinephrine is released, which binds to α- or β-adrenergic receptors

beta (β)-adrenergic receptor: one of the receptors to which epinephrine and norepinephrine bind, which comes in two subtypes: β1 and β2

celiac ganglion: one of the collateral ganglia of the sympathetic system that projects to the digestive system

central neuron: specifically referring to the cell body of a neuron in the autonomic system that is located in the central nervous system, specifically the lateral horn of the spinal cord or a brain stem nucleus

cholinergic: synapse at which acetylcholine is released and binds to the nicotinic or muscarinic receptor

chromaffin cells: neuroendocrine cells of the adrenal medulla that release epinephrine and norepinephrine into the bloodstream as part of sympathetic system activity

ciliary ganglion: one of the terminal ganglia of the parasympathetic system, located in the posterior orbit, axons from which project to the iris

collateral ganglia: ganglia outside of the sympathetic chain that are targets of sympathetic preganglionic fibers, which are the celiac, inferior mesenteric, and superior mesenteric ganglia

craniosacral system: alternate name for the parasympathetic division of the autonomic nervous system that is based on the anatomical location of central neurons in brain-stem nuclei and the lateral horn of the sacral spinal cord; also referred to as craniosacral outflow

dorsal nucleus of the vagus nerve: location of parasympathetic neurons that project through the vagus nerve to terminal ganglia in the thoracic and abdominal cavities

Eddinger–Westphal nucleus: location of parasympathetic neurons that project to the ciliary ganglion

endogenous: describes substance made in the human body

epinephrine: signaling molecule released from the adrenal medulla into the bloodstream as part of the sympathetic response

exogenous: describes substance made outside of the human body

fight-or-flight response: set of responses induced by sympathetic activity that lead to either fleeing a threat or standing up to it, which in the modern world is often associated with anxious feelings

G protein–coupled receptor: membrane protein complex that consists of a receptor protein that binds to a signaling molecule—a G protein—that is activated by that binding and in turn activates an effector protein (enzyme) that creates a second-messenger molecule in the cytoplasm of the target cell

ganglionic neuron: specifically refers to the cell body of a neuron in the autonomic system that is located in a ganglion

gray rami communicantes: (singular = **ramus communicans**) unmyelinated structures that provide a short connection from a sympathetic chain ganglion to the spinal nerve that contains the postganglionic sympathetic fiber

greater splanchnic nerve: nerve that contains fibers of the central sympathetic neurons that do not synapse in the chain ganglia but project onto the celiac ganglion

inferior mesenteric ganglion: one of the collateral ganglia of the sympathetic system that projects to the digestive system

intramural ganglia: terminal ganglia of the parasympathetic system that are found within the walls of the target effector

lesser splanchnic nerve: nerve that contains fibers of the central sympathetic neurons that do not synapse in the chain ganglia but project onto the inferior mesenteric ganglion

ligand-gated cation channel: ion channel, such as the nicotinic receptor, that is specific to positively charged ions and opens when a molecule such as a neurotransmitter binds to it

mesenteric plexus: nervous tissue within the wall of the digestive tract that contains neurons that are the targets of autonomic preganglionic fibers and that project to the smooth muscle and glandular tissues in the digestive organ

muscarinic receptor: type of acetylcholine receptor protein that is characterized by also binding to muscarine and is a metabotropic receptor

nicotinic receptor: type of acetylcholine receptor protein that is characterized by also binding to nicotine and is an ionotropic receptor

norepinephrine: signaling molecule released as a neurotransmitter by most postganglionic sympathetic fibers as part of the sympathetic response, or as a hormone into the bloodstream from the adrenal medulla

nucleus ambiguus: brain-stem nucleus that contains neurons that project through the vagus nerve to terminal ganglia in the thoracic cavity; specifically associated with the heart

parasympathetic division: division of the autonomic nervous system responsible for restful and digestive functions

paravertebral ganglia: autonomic ganglia superior to the sympathetic chain ganglia

postganglionic fiber: axon from a ganglionic neuron in the autonomic nervous system that projects to and synapses with the target effector; sometimes referred to as a postganglionic neuron

preganglionic fiber: axon from a central neuron in the autonomic nervous system that projects to and synapses with a ganglionic neuron; sometimes referred to as a preganglionic neuron

prevertebral ganglia: autonomic ganglia that are anterior to the vertebral column and functionally related to the sympathetic chain ganglia

rest and digest: set of functions associated with the parasympathetic system that lead to restful actions and digestion

superior cervical ganglion: one of the paravertebral ganglia of the sympathetic system that projects to the head

superior mesenteric ganglion: one of the collateral ganglia of the sympathetic system that projects to the digestive system

sympathetic chain ganglia: series of ganglia adjacent to the vertebral column that receive input from central sympathetic neurons

sympathetic division: division of the autonomic nervous system associated with the fight-or-flight response

target effector: organ, tissue, or gland that will respond to the control of an autonomic or somatic or endocrine signal

terminal ganglia: ganglia of the parasympathetic division of the autonomic system, which are located near or within the target effector, the latter also known as intramural ganglia

thoracolumbar system: alternate name for the sympathetic division of the autonomic nervous system that is based on the anatomical location of central neurons in the lateral horn of the thoracic and upper lumbar spinal cord

varicosity: structure of some autonomic connections that is not a typical synaptic end bulb, but a string of swellings along the length of a fiber that makes a network of connections with the target effector

white rami communicantes: (singular = **ramus communicans**) myelinated structures that provide a short connection from a sympathetic chain ganglion to the spinal nerve that contains

the preganglionic sympathetic fiber

Sensory Perception

alkaloid: substance, usually from a plant source, that is chemically basic with respect to pH and will stimulate bitter receptors

amacrine cell: type of cell in the retina that connects to the bipolar cells near the outer synaptic layer and provides the basis for early image processing within the retina

ampulla: in the ear, the structure at the base of a semicircular canal that contains the hair cells and cupula for transduction of rotational movement of the head

anosmia: loss of the sense of smell; usually the result of physical disruption of the first cranial nerve

aqueous humor: watery fluid that fills the anterior chamber containing the cornea, iris, ciliary body, and lens of the eye

audition: sense of hearing

auricle: fleshy external structure of the ear

basilar membrane: in the ear, the floor of the cochlear duct on which the organ of Corti sits

bipolar cell: cell type in the retina that connects the photoreceptors to the RGCs

capsaicin: molecule that activates nociceptors by interacting with a temperature-sensitive ion channel and is the basis for "hot" sensations in spicy food

chemoreceptor: sensory receptor cell that is sensitive to chemical stimuli, such as in taste, smell, or pain

choroid: highly vascular tissue in the wall of the eye that supplies the outer retina with blood

ciliary body: smooth muscle structure on the interior surface of the iris that controls the shape of the lens through the zonule fibers

cochlea: auditory portion of the inner ear containing structures to transduce sound stimuli

cochlear duct: space within the auditory portion of the inner ear that contains the organ of Corti and is adjacent to the scala tympani and scala vestibuli on either side

cone photoreceptor: one of the two types of retinal receptor cell that is specialized for color vision through the use of three photopigments distributed through three separate populations of cells

contralateral: word meaning "on the opposite side," as in axons that cross the midline in a fiber tract

cornea: fibrous covering of the anterior region of the eye that is transparent so that light can pass through it

cupula: specialized structure within the base of a semicircular canal that bends the stereocilia of hair cells when the head rotates by way of the relative movement of the enclosed fluid

encapsulated ending: configuration of a sensory receptor neuron with dendrites surrounded by specialized structures to aid in transduction of a particular type of sensation, such as the lamellated corpuscles in the deep dermis and subcutaneous tissue

equilibrium: sense of balance that includes sensations of position and movement of the head

external ear: structures on the lateral surface of the head, including the auricle and the ear canal back to the tympanic membrane

exteroceptor: sensory receptor that is positioned to interpret stimuli from the external environment, such as photoreceptors in the eye or somatosensory receptors in the skin

extraocular muscle: one of six muscles originating out of the bones of the orbit and inserting into the surface of the eye which are responsible for moving the eye

fibrous tunic: outer layer of the eye primarily composed of connective tissue known as the sclera and cornea

fovea: exact center of the retina at which visual stimuli are focused for maximal acuity, where the retina is thinnest, at which there is nothing but photoreceptors

free nerve ending: configuration of a sensory receptor neuron with dendrites in the connective tissue of the organ, such as in the dermis of the skin, that are most often sensitive to chemical, thermal, and mechanical stimuli

general sense: any sensory system that is distributed throughout the body and incorporated into organs of multiple other systems, such as the walls of the digestive organs or the skin

gustation: sense of taste

gustatory receptor cells: sensory cells in the taste bud that transduce the chemical stimuli of gustation (tasting)

hair cells: mechanoreceptor cells found in the inner ear that transduce stimuli for the senses of hearing and balance

incus: (also, anvil) ossicle of the middle ear that connects the malleus to the stapes

inferior oblique: extraocular muscle responsible for lateral rotation of the eye

inferior rectus: extraocular muscle responsible for looking down

inner ear: structure within the temporal bone that contains the sensory apparati of hearing and balance

inner segment: in the eye, the section of a photoreceptor that contains the nucleus and other major organelles for normal cellular functions

inner synaptic layer: layer in the retina where bipolar cells connect to RGCs

interoceptor: sensory receptor that is positioned to interpret stimuli from internal organs, such as stretch receptors in the wall of blood vessels

ipsilateral: word meaning on the same side, as in axons that do not cross the midline in a fiber tract

iris: colored portion of the anterior eye that surrounds the pupil

kinesthesia: sense of body movement based on sensations in skeletal muscles, tendons, joints, and the skin

lacrimal duct: duct in the medial corner of the orbit that drains tears into the nasal cavity

lacrimal gland: gland lateral to the orbit that produces tears to wash across the surface of the eye

lateral rectus: extraocular muscle responsible for abduction of the eye

lens: component of the eye that focuses light on the retina

levator palpebrae superioris: muscle that causes elevation of the upper eyelid, controlled by fibers in the oculomotor nerve

macula: enlargement at the base of a semicircular canal at which transduction of equilibrium stimuli takes place within the ampulla

malleus: (also, hammer) ossicle that is directly attached to the tympanic membrane

mechanoreceptor: receptor cell that transduces mechanical stimuli into an electrochemical signal

medial rectus: extraocular muscle responsible for adduction of the eye

middle ear: space within the temporal bone between the ear canal and bony labyrinth where the ossicles amplify sound waves from the tympanic membrane to the oval window

neural tunic: layer of the eye that contains nervous tissue, namely the retina

nociceptor: receptor cell that senses pain stimuli

odorant molecules: volatile chemicals that bind to receptor proteins in olfactory neurons to stimulate the sense of smell

olfaction: sense of smell

olfactory bulb: central target of the first cranial nerve; located on the ventral surface of the frontal lobe in the cerebrum

olfactory epithelium: region of the nasal epithelium where olfactory neurons are located

olfactory sensory neuron: receptor cell of the olfactory system, sensitive to the chemical stimuli of smell, the axons of which compose the first cranial nerve

opsin: protein that contains the photosensitive cofactor retinal for phototransduction

optic disc: spot on the retina at which RGC axons leave the eye and blood vessels of the inner retina pass

optic nerve: second cranial nerve, which is responsible visual sensation

organ of Corti: structure in the cochlea in which hair cells transduce movements from sound waves into electrochemical signals

osmoreceptor: receptor cell that senses differences in the concentrations of bodily fluids on the basis of osmotic pressure

ossicles: three small bones in the middle ear

otolith: layer of calcium carbonate crystals located on top of the otolithic membrane

otolithic membrane: gelatinous substance in the utricle and saccule of the inner ear that contains calcium carbonate crystals and into which the stereocilia of hair cells are embedded

outer segment: in the eye, the section of a photoreceptor that contains opsin molecules that transduce light stimuli

outer synaptic layer: layer in the retina at which photoreceptors connect to bipolar cells

oval window: membrane at the base of the cochlea where the stapes attaches, marking the beginning of the scala vestibuli

palpebral conjunctiva: membrane attached to the inner surface of the eyelids that covers the anterior surface of the cornea

papilla: for gustation, a bump-like projection on the surface of the tongue that contains taste buds

photoisomerization: chemical change in the retinal molecule that alters the bonding so that it switches from the 11-*cis*-retinal isomer to the all-*trans*-retinal isomer

photon: individual "packet" of light

photoreceptor: receptor cell specialized to respond to light stimuli

proprioception: sense of position and movement of the body

proprioceptor: receptor cell that senses changes in the position and kinesthetic aspects of the body

pupil: open hole at the center of the iris that light passes through into the eye

receptor cell: cell that transduces environmental stimuli into neural signals

retina: nervous tissue of the eye at which phototransduction takes place

retinal: cofactor in an opsin molecule that undergoes a biochemical change when struck by a photon (pronounced with a stress on the last syllable)

retinal ganglion cell (RGC): neuron of the retina that projects along the second cranial nerve

rhodopsin: photopigment molecule found in the rod photoreceptors

rod photoreceptor: one of the two types of retinal receptor cell that is specialized for low-light vision

round window: membrane that marks the end of the scala tympani

saccule: structure of the inner ear responsible for transducing linear acceleration in the vertical plane

scala tympani: portion of the cochlea that extends from the apex to the round window

scala vestibuli: portion of the cochlea that extends from the oval window to the apex

sclera: white of the eye

semicircular canals: structures within the inner ear responsible for transducing rotational movement information

sensory modality: a particular system for interpreting and perceiving environmental stimuli by the nervous system

somatosensation: general sense associated with modalities lumped together as touch

special sense: any sensory system associated with a specific organ structure, namely smell, taste, sight, hearing, and balance:

spiral ganglion: location of neuronal cell bodies that transmit auditory information along the eighth cranial nerve

stapes: (also, stirrup) ossicle of the middle ear that is attached to the inner ear

stereocilia: array of apical membrane extensions in a hair cell that transduce movements when they are bent

submodality: specific sense within a broader major sense such as sweet as a part of the sense of taste, or color as a part of vision

superior oblique: extraocular muscle responsible for medial rotation of the eye

superior rectus: extraocular muscle responsible for looking up

taste buds: structures within a papilla on the tongue that contain gustatory receptor cells

tectorial membrane: component of the organ of Corti that lays over the hair cells, into which the stereocilia are embedded

thermoreceptor: sensory receptor specialized for temperature stimuli

topographical: relating to positional information

transduction: process of changing an environmental stimulus into the electrochemical signals of the nervous system

trochlea: cartilaginous structure that acts like a pulley for the superior oblique muscle

tympanic membrane: ear drum

umami: taste submodality for sensitivity to the concentration of amino acids; also called the savory sense

utricle: structure of the inner ear responsible for transducing linear acceleration in the horizontal plane

vascular tunic: middle layer of the eye primarily composed of connective tissue with a rich blood supply

vestibular ganglion: location of neuronal cell bodies that transmit equilibrium information along the eighth cranial nerve

vestibule: in the ear, the portion of the inner ear responsible for the sense of equilibrium

visceral sense: sense associated with the internal organs

vision: special sense of sight based on transduction of light stimuli

visual acuity: property of vision related to the sharpness of focus, which varies in relation to retinal position

vitreous humor: viscous fluid that fills the posterior chamber of the eye

zonule fibers: fibrous connections between the ciliary body and the lens