Anatomy and Physiology 2 Lab Manual

Anatomy and Physiology 2 Lab Manual

SHERYL SHOOK

Anatomy and Physiology 2 Lab Manual by Sheryl Shook is licensed under a Creative Commons Attribution 4.0 International License, except where otherwise noted.

Contents

Front Cover Image Credits vii
Sheryl Shook

Introduction viii
Sheryl Shook

Lab Orientation and Safety ix
Sheryl Shook

PHYL 142L Study Guide xiii
Sheryl Shook

Chapter 1. Endocrine Anatomy 1
Sheryl Shook

Chapter 2. Blood Lab 3
Sheryl Shook

Chapter 3. Cardiovascular Anatomy 23
Sheryl Shook

Chapter 4. Cardiovascular Experiments 27
Sheryl Shook

Chapter 5. Heart Dissection 41
Sheryl Shook

Chapter 6. Respiratory System Anatomy 56
Sheryl Shook

Chapter 7. Respiratory Physiology Experiment 59
Sheryl Shook

Chapter 8. Digestive System Anatomy 73
Sheryl Shook

Chapter 9. Urinary System Anatomy 76
Sheryl Shook
Chapter 10. Reproductive System Anatomy 79
Sheryl Shook
Chapter 11. Fetal Pig Dissection 83
Sheryl Shook

Appendix 115
Sheryl Shook

Front Cover Image Credits

SHERYL SHOOK

Clockwise from far left top row:

Throw ya hands in the air, like ya just don't care by Steve Halama / CC0

Untitled by Brooke Cagle / CC0

Untitled by Andreas Fidler / CC0

Man Looking Outside Window Carrying Black and Brown Backpack While Holding His Hand on Window / CC0

Man Work Think Laptop Professional by Keshav Naidu / CC0

Womens wheelchair basketball by Audi Nissen / CC0

Untitled by Mimi Thian / CC0

Two Women Looking Up by Riya Kumari / CC0

Introduction

SHERYL SHOOK

Anatomy and Physiology 2 Laboratory Manual provides the background and guidance necessary for conducting laboratories that include studies in the following areas:

- Endocrine
- Blood
- Cardiovascular
- Respiratory
- Digestive
- Urinary
- Reproductive
- Fetal Pig Dissection

Lab Orientation and Safety

SHERYL SHOOK

Resources

KCC Anatomy and Physiology STEM Center Annex

An on-campus place to study gross anatomy models. Located inside the main KCC STEM Center (Kokiʻo 203).

The main STEM Center also has resources such as computers, printing, free coffee, peer mentoring and more. Bring your lunch, get some free tutoring, study in a comfortable space, and succeed! Please note, the main STEM Center space is separate from the A&P annex. Food is not allowed in the A&P annex in an attempt to keep the models clean.

Always sign in when using the STEM Center.

See the KCC STEM website for hours for the main room and A&P annex.

KCC A&P Website

See the KCC A&P Online Resources website for computer and mobile device access to images of gross anatomy models and microanatomy:

http://stemap.kcc.hawaii.edu

Username and password provided by your instructor and at the bottom of your class schedule.

Rules

Laboratory Rooms

Your lab may be conducted in different rooms (Kokiʻo 203 and 205) during the semester. Check your schedule. Kokiʻo 205 is a wet lab so has different rules and safety requirements, such as shoes that completely cover the feet. There are no exceptions to the safety rules, so you will be turned away from class if you show up in sandals to room 205.

1. Shoes that completely cover the feet are required in the wet laboratory (Kokiʻo 205).
2. Eating and drinking are not allowed in the lab. Report to instructor any equipment malfunctions or breakages.
3. Never cut with a scalpel toward your body or hand or a classmate's hand who may be holding the specimen.
4. Ask instructor if you do not understand the proper use of lab instruments.
5. Disinfect your lab table after every dissection and experiment.
6. The use of the laboratory is restricted to assigned lab exercises only.
7. Know the location of the first aid kit and eye wash station.
8. Report to instructor any cuts, pokes, splashes, or chemical reactions.

Anatomical Models

1. Wash your hands before handling the anatomical models.
2. Locate the models in storage cabinets. Please return models to the appropriate cabinet when finished.

3. Certain models (reproductive and brain models) must be checked out from the student monitor and require the presentation of identification.
4. No student should write on, mark or re-label any of the anatomical models.

Safety and Warnings

The animal specimens have been fixed in formalin, an aqueous fluid that contains formaldehyde. Formalin is an irritant of the upper respiratory tract, eyes, and skin. The U.S. EPA classifies formaldehyde as Group B1, a probable human carcinogen; and the World Health Organization classifies it as carcinogenic to humans. For these reasons our animal specimens, once fixed in formalin, are preserved and shipped in other formalin-free liquids, such as ethylene glycol. Nevertheless, when specimens are cut open, formaldehyde is released, and the following precautions should be made.

1. Wear appropriate gloves and avoid any skin contact with the specimen and fluids. Any skin contact with preservative fluids should be washed off immediately. Report any skin reactions to the instructor.
2. Wearing a lab coat or covering of a long sleeve shirt is recommended to protect your arms and clothing that can be damaged by the fluids.
3. Wear protective goggles at all times when specimens or chemicals are out in the lab. Glasses are not sufficient; goggles are required.
4. Never drink any fluid in the lab as it may be lethal.
5. Drain, rinse with water, and pat dry your specimen before use to minimize fumes.
6. Keep dissection tray clear of fluid accumulation.

7. All dissections in Koki‘o 205 must be done with all windows and doors fully open and all fans running.
8. Students who are pregnant or have health concerns, chronic health conditions, or sensitivities, including but not limited to respiratory conditions, should consult with the instructor about alternate learning activities for dissection days. Many professors provide the online-course version of the dissection assignment.
9. Do not remove any specimens or materials from the lab.
10. On biohazard days, dispose of all biohazard materials in boxes clearly marked for biohazard waste.
11. Any broken glass or sharp waste needs to be disposed of in sharps container.

Risk and Release Form

Your instructor will handout a department form stating assumption of risk and release from claims. All students sign before participation in this lab course.

PHYL 142L Study Guide

SHERYL SHOOK

Exam 1
(30 *multiple choice questions*)

1. **Microanatomy** (5 *questions*)
    1. Endocrine System
    2. Circulatory System
    3. Lymphatic System
2. **Models**
    1. Endocrine Model Images (5 *questions*)
    2. Heart Model (5 *questions*)
    3. Circulatory System Model (5 *questions*)
3. **Experiment Labs**
    1. Blood Experiment Lab (5 *questions*)
    2. Cardiovascular Experiment Lab (5 *questions*)
    3. Pig Heart Dissection Lab (*not on exam*)

Exam 2
(30 *multiple choice questions*)

1. **Microanatomy**
    1. Respiratory System (5 *questions*)
    2. Digestive System (5 *questions*)
2. **Models**
    1. Respiratory System Model (5 *questions*)
    2. Digestive System Model (5 *questions*)
3. **Experiment Labs**

    1. Respiratory Experiment Lab (5 *questions*)
    2. Body Composition Experiment Lab (5 *questions*)

Exam 3
(35 *multiple choice questions*)

1. **Microanatomy**

1. Urinary System (5 *questions*)
2. Reproductive System (5 *questions*)

1. **Models**
    1. Kidney Model (5 *questions*)
    2. Urinary System Model (5 *questions*)
    3. Male Reproductive System Model (5 *questions*)
    4. Female Reproductive System Model (5 *questions*)
2. **Experiment Labs**
    1. Urinalysis Experiment Lab (5 *questions*)
    2. Fetal Pig Dissection Lab (*not on exam*)

Attribution:
Marissa Sumida / CC BY 4.0

SHERYL SHOOK

Endocrine Anatomy

Learning Objectives

- Identify endocrine system gross anatomical structures.
- Identify endocrine system microscopic structures.

Gross and Microscopic Anatomy

Use local resources to view structures of the endocrine system.

Teach students the technique of swift and rough sketches of microscopic anatomy in preparation for playing a small-group game with students using their notes to identify endocrine microanatomy on projected slides.

Endocrine Structures List

- Hypothalamus
- Pituitary gland
- Pineal gland
- Thyroid

- Parathyroid gland
- Thymus
- Adrenal Glands
- Pancreas
- Ovaries
- Testes

SHERYL SHOOK

Blood Lab

Learning Objectives

- Explain hematocrit, including the significance of values outside of the normal range.
- Determine hematocrit from a blood sample image.
- Explain the ABO and Rh blood groups and their clinical significance.
- Conduct blood typing on a synthetic-blood sample.
- Identify and describe all formed elements in a human blood smear.
- State the relative proportions of formed elements in human blood.
- Demonstrate proficient microscope use.

Blood Composition and Hematocrit

Composition of blood

Overview of Blood [link opens in new window]

1. 55% = Plasma

    1. Proteins (for blood pressure, clotting, and immune functions)
    2. Water (92% of plasma)
    3. Electrolytes
    4. Hormones
    5. Nutrients
    6. Blood gases
    7. Waste
2. 45% = Formed Elements
    1. Red Blood Cells (erythrocytes)
    2. Platelets (thrombocytes)
    3. White Blood Cells (leukocytes)

Hematocrit

- Definition: The volume—reported as a percentage—of packed elements (mainly red blood cells) in a blood sample.
- Clinical relevance: Provides information about the oxygen-carrying capacity of blood. Low hematocrit means less red blood cells carrying O2.
- Healthy ranges:
    - Male: _____%
    - Female:_____%

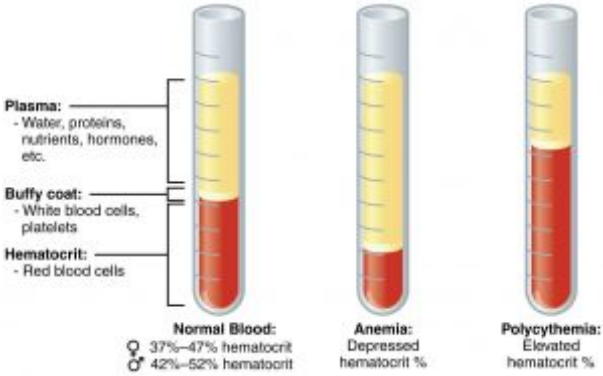

Figure 2.1. Composition of Blood by Open Stax / CC BY 4.0.

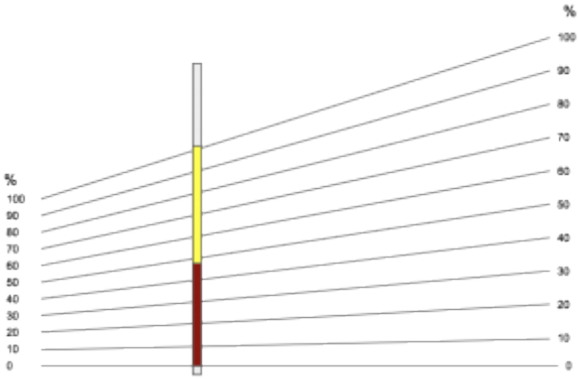

Figure 2.2. Measuring hematocrit by Ashley Kajioka / CC BY 4.0

What is the hematocrit for this sample?

_____

Blood Typing

Blood Typing

Blood type refers to the presence or absence of specific molecules, called antigens, on the red blood cell (RBC) RBC surface. Antigens are molecules, such as proteins, lipids, carbohydrates or nucleic acids, that your body can use to differentiate self and non-self. People with different blood types have different antigens on their RBCs.

Antibodies are produced in response to some antigens (non-self), and are generally used by the immune system to recognize and facilitate removal of objects (viruses, bacteria, tumorous cells, etc.) that do not belong in the body.

There are more than 50 blood types in the human population. The most clinically significant are the ABO and Rh(+/-) blood groups.

The ABO Blood Group

A and B antigens are glycoproteins on the RCC surface. ABO typing does not affect a person's Rh (+ or -) designation. Figure 2.3 Blood Type

Type A blood: A antigens on cell; anti-B antibodies in plasma

Type B blood: B antigens on cell; anti-A antibodies in plasma

Type AB blood: both A and B antigens on cell; neither anti-A nor anti-B antibodies in plasma

Type O blood: neither A nor B antigens on cell; both anti-A and anti-B antibodies in plasma

If a different type of blood is put into your bloodstream, the blood will agglutinate (clump) and hemolysis (bursting) occurs within the foreign blood cells. Agglutination due to antibodies and antigens is a different process than blood clotting, which involves fibrin and other cascades associated with hemostasis.

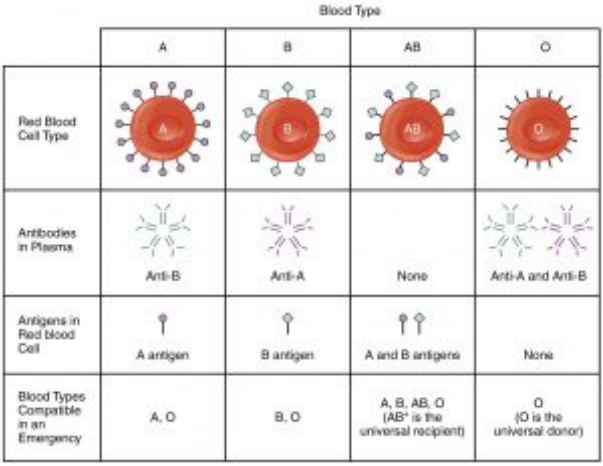

Figure 2.3. Blood Type by Open Stax / CC BY 4.0

Rh Blood Group

Rh antigens are named after the rhesus macaque, a primate with many blood similarities to human. There are many Rh antigens in humans, but the D type of Rh antigen is the most clinically significant. Because of this, in blood typing, sometimes D and Rh are used interchangeably. The Rh factor is grouped with ABO blood group to identify a blood type (example A+, B-, O-).

Type Rh+ (positive) blood: Rh antigens on cell

Type Rh- (negative) blood: no Rh antigens on cell

Unlike ABO blood type, no anti-Rh antibodies are present in Rh- individuals unless they have been exposed to Rh antigens. If Rh+ blood is introduced into an Rh- individual, anti-Rh antibodies will be produced against the Rh(+) blood.

Importance of Rh during Pregnancy

This is a critical consideration in pregnancy for Rh- mothers if the

fetus is Rh+. If any of the Rh+ blood enters the mother's circulation, the mother's immune system will produce anti-Rh antibodies that will hemolyze her baby's blood (and any future Rh+ fetuses). This is called hemolytic disease of the newborn or erythroblastosis fetalis. It is prevented with RhoGAM, a dosage of anti-Rh antibodies, given to the mother at 27 weeks and within 72 hours of giving birth in order to destroy any fetal blood cells in her blood so she will not produce her own anti-Rh antibodies. RhoGam antibody dosage is small enough not to hurt fetus, but strong enough to keep mom's immune system from attacking fetus. See Figure 2.4.

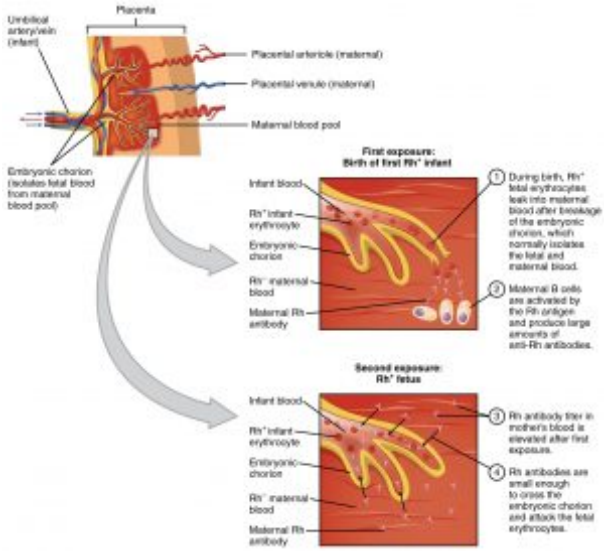

Figure 2.4. Erythroblastosis_Fetalis by Open Stax / CC BY 4.0

Determining Blood Type

To determine blood types, antiserum is used. The serum contains antibodies that may react with antigens on the RBC surface.

If using anti-A antiserum (contains anti-A antibodies) and the blood sample agglutinates (clumps), this indicates the presence of A antigens.

Which blood types have A antigens? Fill in the type.
Type _____ and Type _____

If using anti-B antiserum (contains anti-B antibodies) and the blood sample agglutinates (clumps), this indicates the presence of B antigens.

Which blood types have B antigens? Fill in the type.
Type _____ and Type _____

If using anti-Rh (anti-D) antiserum (contains anti-Rh (anti-D) antibodies) and the blood sample agglutinates (clumps), this indicates the presence of Rh antigens.

Which blood type has Rh antigens? Fill in the type.
Type _____

Blood Typing Data

Complete the blood typing on your samples and enter your data in Table 2.1.

For each blood sample:

1. Place a drop of blood in each of the three depressions of one testing tray. Each depression has a label of A, B, or Rh(D). One tray is used for each blood sample.
2. Place a drop of the antiserum that is associated with each depression. For example anti-A antiserum (containing anti-A antibodies) goes into the depression marked A. In that depression, you will be testing to see if the anti-A antibodies agglutinate RBCs with A antigens. Do the same for anti-B and anti-Rh sera into each of their depressions in the tray.
3. Stir the combination of the blood and antiserum in each depression with the color coded toothpick. Do not mix toothpicks across depressions.
4. Examine the samples for agglutination and fill out your data table to determine the blood type for each sample.

Using blood sample	Antiserum contains antibody Anti-A and tests for antigen A	Antiserum contains antibody Anti-B and tests for antigen B	Antiserum contains antibody Anti-Rh (D) and tests for antigen Rh (D)	What is the blood type?
Blood sample 1	Agglutinated? Yes or No	Agglutinated? Yes or No	Agglutinated? Yes or No	Type:
Blood sample 2	Agglutinated? Yes or No	Agglutinated? Yes or No	Agglutinated? Yes or No	Type:
Blood sample 3	Agglutinated? Yes or No	Agglutinated? Yes or No	Agglutinated? Yes or No	Type:
Blood sample 4	Agglutinated? Yes or No	Agglutinated? Yes or No	Agglutinated? Yes or No	Type:

Table 2.1 Blood Typing Data

Human Blood Microscopy and General Microscope Use

In this part of the lab you will use a microscope to examine erythrocytes, leukocytes, and platelets. These three constituents are referred to as the formed elements of blood. Platelets are not considered a cell, as they are enclosed cytoplasmic fragments. A complete blood count with differential is a clinical measure that states the percentages of each blood cell type and is used for various diagnostics such as determining anemia or types of infections or allergic reactions. Erythrocytes are the most numerous blood cell, and then the count of the different leukocytes goes from most to

least numerous in this order: neutrophils, lymphocytes, monocytes, eosinophils, and basophils.

Formed Elements of Blood

Erythrocytes (Red Blood Cells)

Erythrocytes

See Figure 2.5 below and notice the numerous, round, pink cells in the background each of the leukocyte images. These are red blood cells (RBCs). Some look like they have a hole in the middle, but this is due to the thin area of the biconcave shape that allows for flexibility and to increase surface area.

Primary function: transport respiratory gases to and from tissues.

Lack a nucleus.

Most abundant of all blood cells.

Contains millions of Hemoglobin molecules: allow for binding of O2 and CO2.

Platelets

Platelets

Also called thrombocytes but not technically a cell. They are produced by the fragmentation megakaryocytes that are in bone marrow tissue.

Involved in coagulation: the process of clot formation.

During coagulation, molecules (fibrin) join to form long threads that form a net to trap platelets and plug the wound.

Leukocytes (White Blood Cells)

Leukocytes

See Figure 2.5 below.

Only formed elements with a nucleus.

Lacks hemoglobin.

Travel between endothelial cells of capillaries and tissues.

Two types of leukocytes: granular and agranular.

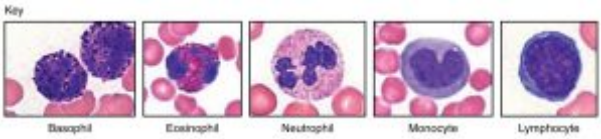

Figure 2.5. Leucocyte Key by Open Stax / CC BY 4.0

Granulocytes

See Figure 2.6 below.

All have granules in cytoplasm.

1. Neutrophils (40-60% of total white blood cell (WBC) count)
    1. most common WBC
    2. 1st to arrive at wound/infection site
    3. release cytotoxins
    4. capable of phagocytosis
2. Eosinophils (1-4% of total WBC count)
    1. phagocytize microbes that immune system has coated with antibodies
    2. decrease inflammatory response at site of wound
3. Basophil (0.5-1% of WBC count)
    1. release histamines (cause vasodilation) and heparin (prevents clotting)
    2. important in allergies

Figure 2.6. Granular Leucocytes by Open Stax / CC BY 4.0

Agranulocytes

Refer back to Figure 2.5

Fewer and less obvious granules in cytoplasm.

1. Monocytes (2-8% of total WBC count)
    1. wanderers, patrol body tissue for microbes and worn-out tissue cells
    2. 2nd to arrive at wound site
    3. phagocytize dead cells/debris that has accumulated at site of wound/infection
2. Lymphocytes (20-40% of WBCs)
    1. smallest leukocyte, abundant in bloodstream, occur in lymph nodes and glands
    2. specialized lymphocytes:
        1. T-cells: attach to and destroy infected or cancerous cells by releasing cytotoxic molecules and secreting antiviral/proinflammatory molecules
        2. B-cells: manufacture antibodies that attach to foreign pathogens/cells and help destroy them
        3. Natural Killer cells: can detect sick, cancerous, and infected cells and release cytotoxic molecules to destroy them

Follow the instructions below for microscope use, and examine a

human blood smear. Sketch each of the formed elements of blood as seen in your view.

Microscope Parts and How To Handle Them

There are many different types of microscopes. We shall learn about the compound light microscope. It uses visible light to visualize the specimen, and passes that light through two separate lenses to magnify the image. Compound microscopes have a lot of moving parts and can be damaged and broken through mishandling. A large part of learning how to use the microscope properly involves learning how to avoid damaging it. To do that, you first have to be familiar with the parts.

In Figure 2.7, there are two compound microscopes shown with key parts identified. The one on the left is monocular and the one on the right is binocular. Many of the parts of the two microscopes are in slightly different locations.

When you first sit in front of a microscope, take a moment to find the key parts, especially the knobs for focus, condenser adjustment, and stage control. When viewing a specimen, your eyes will be at the eyepieces (oculars), and if you grab the wrong knob by accident, you can lose your image or damage the microscope.



Figure 2.7 Key parts of a compound light microscope. Compound light microscope by Ross Whitwam / CC BY SA

Eyepiece (Ocular)

The eyepiece contains the eyepiece lens, one of the two lenses doing the magnifying in a compound microscope. If the microscope is binocular, use both eyepieces, adjusting them to ensure they fit the spacing of your eyes. For successful binocular viewing, bring your image into focus with the lowest power objective, while looking through only the non-adjustable ocular. Then while looking only through the adjustable ocular, rotate its focus ring to bring that ocular into clear focus. Now the image should be clear as you look through both oculars.

Carrying arm

When moving a microscope, even if it is just a few inches, always pick it up by the carrying arm. Do not drag the microscope: pick it up. The microscope will have rubber feet that prevent it from sliding, so if you try to drag it, it will shake and vibrate and possibly damage parts. Never pick up the microscope by any part other than the carrying arm. The other parts are generally much more fragile and prone to breaking.

Objective lenses

Most compound light microscopes will contain three to four objective lenses that can be rotated over the slide. Sometimes these lenses are just called objectives. When a particular objective has been fully rotated into position, you will feel a click as that objective locks into place. The objective lens is the second of the two lenses doing the magnifying in a compound microscope, so if it is not snapped into proper position, you will not see the proper image. Each objective lens can usually be unscrewed from its position in

the rotating turret that houses it, so be careful you are rotating the turret, not unscrewing an objective. Do not unscrew the objectives from the turret. Each objective lens has a different magnifying power, so the image on your slide will be magnified to lesser or greater extents, depending on which objective lens you have chosen. Each objective's magnification power will be written somewhere on the side of the objective.

Stage and stage clips

The slide will be held in place on the stage with stage clips that press against the sides of the slide. The clips do not sit above or below the slide. They are spring-loaded to hold the slide edges and lock the slide in place so that the stage controls can move the position of the slide smoothly.

Stage controls

These allow you to move your slide while you are viewing it, but only if the slide is properly clipped in with the stage clips. Find the stage control dials on your microscope before you start viewing your slide. There are two dials–one moves the slide left and right, the other moves the slide up and down. Notice in Figure 2.7, the dials are on top of each other and below the stage on the binocular microscope, however, they are two separate dials and above the stage on the monocular microscope.

Coarse focus

This is the larger of the two focus knobs. Use it with the lowest power objective to get the specimen approximately in focus. After

that, only use the fine focus knob, even after you change to a higher-power objective. Notice in Figure 2.7, the binocular microscope fine focus knob is surrounded by the coarse focus knob, however, the monocular microscope coarse focus and fine focus knobs are separated.

Fine focus

This is the smaller of the two focus knobs. This is the focus you will use repeatedly in viewing slides once they are focused with the coarse focus.

Condenser position adjustment

You typically will not need to adjust this knob. It controls how far the light condenser is from the slide, which should be properly adjusted before you use the microscope.

Condenser opening adjustment (not shown in figure)

This opening can be adjusted, usually by rotating a ring around the condenser. Be sure this has not been left closed by a previous user. Experiment with different opening sizes to determine what is best for your specimen.

Iris diaphragm lever

Find the lever under the stage where light passes through to the slide. It opens and closes an iris to let more or less light through the slide. In some specimens there is not much contrast between the

colours and shades of the different components being magnified. Changing the view by adjusting the iris can allow you to better see some of the details you are trying to magnify.

Rheostat: Light intensity (not shown in figure)

Rotate this dial to adjust the brightness of the light source. Turn this to its a low setting before looking through the eyepieces. You may need to increase the intensity as you increase the power of your objective. Turn the rheostat all the way down before turning off your microscope.

Lab exercises

Carry out the activities listed below and answer the questions.

1. Pick up your microscope and bring it close enough that you can look into it comfortably from where you are sitting with healthy posture. Arrange it so that the stage is facing you and the eyepieces are rotated toward you. What part of the microscope did you grab in order to pick it up and move it?
2. Where are the locations of the two stage adjustment knobs on your microscope?
3. Where is the location of the coarse focus knob?
4. Where is the location of the fine focus knob?

5. Is there a condenser opening adjustment ring?
6. Find the diaphragm lever. Looking in the hole in the center of the stage, what happens when you move the diaphragm lever in each direction?
7. After cleaning a slide as instructed by your professor, place the slide on the stage.
8. Take the steps described in the ocular section to obtain clear view through both of your oculars. If you wear glasses, try with and without to determine which is best for you.
9. Adjust the condenser opening and iris lever. How does this change your view?

Checking out and storing the microscope

When you finish your microscope work with the blood slide, be prepared to have your instructor check off each of these items before putting away your microscope.

1. Turn the rheostat to its dimmest setting.
2. Turn off the power, unplug, and wrap the cord around the base.
3. Wipe the objective lenses with methanol and lens paper. Notice this is lens paper, not kimwipes. Using any paper other than lens paper can scratch the lens.
4. Rotate the objective lens turret so the lowest power objective faces down.
5. Wipe the stage clean with a kimwipe and move it to the lowest position.

"Blood Lab" is MODIFIED from:

- Anatomy and Physiology by Open Stax / CC BY 4.0. Download for free at http://cnx.org/contents/14fb4ad7-39a1-4eee-ab6e-3ef2482e3e22@12.8.
- An Overview of Blood, Anatomy and Physiology by Open Stax / CC BY 4.0. https://cnx.org/contents/FPtK1zmh@12.8:IUrEdFyf@10/An-Overview-of-Blood
- UGA Anatomy and Physiology 2 Lab Manual by University System of Georgia / CC BY 4.0
- Human Anatomy and Physiology Lab (BSB 141) by Lumen Learning / CC BY-SA
- A&P Labs. Authored by: Ross Whitwam. Provided by: Mississippi University for Women. Located at: http://www.muw.edu/. License: CC BY-SA: Attribution-ShareAlike
- Labeled compound light microscope. Authored by: Ross Whitwam. Provided by: Mississippi University for Women. Located at: http://www.muw.edu/. License: CC BY-SA: Attribution-ShareAlike

Citation notes:

- Hesse, DeLoris; Cozart, Deanna; Szymik, Brett; and Nichols, Rob, "UGA Anatomy and Physiology 2 Lab Manual" (2017). Biological Sciences Open Textbooks. 14. https://oer.galileo.usg.edu/biology-textbooks/14

"Microscope Parts and How to Handle Them" is MODIFIED from:

- Lumen Learning. CC BY-SA https://courses.lumenlearning.com/ap1x9x1/chapter/the-parts-of-a-compound-microscope-and-how-to-handle-them-correctly/

- A&P Labs. Authored by: Ross Whitwam. Provided by: Mississippi University for Women. Located at: http://www.muw.edu/. License: CC BY-SA: Attribution-ShareAlike
- Labelled compound light microscope. Authored by: Ross Whitwam. Provided by: Mississippi University for Women. Located at: http://www.muw.edu/. License: CC BY-SA: Attribution-ShareAlike

SHERYL SHOOK

Cardiovascular Anatomy

Learning Objectives

- Identify cardiovascular system gross anatomical structures.
- Identify cardiovascular system microscopic structures.

Gross and Microscopic Anatomy

Use local resources to view structures of the cardiovascular system.

Circulatory System Structures List

1. Circulatory System- Arteries- Head and shoulders
    1. Aortic arch
    2. Brachiocephalic (brachiocephalic trunk)
    3. Common carotid arteries
        1. External carotid artery
            1. Facial artery

    4. Subclavian arteries
2. Circulatory System- Arteries- Trunk
    1. Descending aorta
    2. Celiac trunk
        1. Left gastric artery
        2. Splenic artery
        3. Common hepatic artery
    3. Superior mesenteric artery
    4. Renal artery
    5. Gonadal artery
    6. Inferior mesenteric artery
    7. Common iliac artery
        1. Internal iliac artery
        2. External iliac artery
    8. Median (medial) sacral artery
3. Circulatory System- Arteries- Arms
    1. Axillary artery
    2. Subscapular artery
    3. Humeral circumflex artery
    4. Brachial artery
    5. Radial artery
    6. Ulnar artery
    7. Interosseous artery
4. Circulatory System- Arteries- Hands and upper legs
    1. Superficial palmar arch
    2. Femoral artery
    3. Lateral circumflex artery
    4. Medial circumflex artery
    5. Deep femoral artery
    6. Descending genicular artery
    7. Popliteal artery
    8. Lateral superior genicular artery
    9. Medial superior genicular artery
    10. Lateral inferior genicular artery

    11. Medial inferior genicular artery
5. Circulatory System- Arteries- Lower legs and feet
    1. Anterior tibial artery
    2. Dorsalis pedis artery
    3. Peroneal artery
    4. Posterior tibial artery

Heart Structures List

1. Heart- Exterior- Anterior view
    1. Right atrium
    2. Right ventricle
    3. Left atrium
    4. Left ventricle
    5. Apex
    6. Base
    7. Superior vena cava
    8. Pulmonary trunk
    9. Pulmonary arteries
    10. Pulmonary veins
    11. Aorta
    12. Brachiocephalic trunk
    13. Anterior interventricular artery
    14. Great cardiac vein
2. Heart- Exterior- Left lateral view
    1. Inferior vena cava
    2. Circumflex branch of left coronary artery
    3. Left marginal artery
    4. Left marginal vein
    5. Coronary sinus
3. Heart- Exterior- Right lateral view
    1. Right coronary artery

        1. Muscular artery
        2. Right marginal artery
    2. Anterior cardiac vein
    3. Right marginal vein
4. Heart- Open atrium- Lateral view
    1. Pectinate muscle
    2. Fossa ovalis
5. Heart- Open ventricles- Right anterior view
    1. Tricuspid valve
    2. Chordae tendineae
    3. Papillary muscle
    4. Trabeculae carneae
    5. Pulmonary semilunar valve
6. Heart- Open ventricles- Left anterior view
    1. Interventricular septum
    2. Bicuspid valve
    3. Aortic semilunar valve

Attributions for “Cardiovascular Anatomy”:
Circulatory System Structures List by Marissa Sumida / CC BY 4.0
Heart Structures List by Marissa Sumida / CC BY 4.0

SHERYL SHOOK

Cardiovascular Experiments

Learning Objectives

- Explain the physiological basis for each wave of the electrocardiogram (ECG).
- Demonstrate the procedure for conducting an ECG.
- Identify cardiac cycle components from ECG data.
- Demonstrate the sites and techniques for taking pulse to measure heart rate.
- Compare heart rate values calculated from ECG to those from taking a pulse.
- Demonstrate sphygmomanometry (blood pressure measurement).

Electrocardiogram

By placement of surface electrodes on the body, it is possible to record the complex electrical signal of the heart. This tracing of the electrical signal is the electrocardiogram (ECG), also abbreviated EKG (K for kardiologie in German). Analysis of the ECG reveals a detailed picture of both normal and abnormal heart function. The standard electrocardiograph (the instrument that generates an ECG) uses 3, 5, or 12 leads. The term “lead” may be used to refer to

the cable from the electrode on the body to the electrical recorder, but "lead" typically describes the voltage difference between two of the electrodes, as if a "lead" is a view of electrical movement from a specific perspective. A given lead shows how the electrical activity travels through the heart in terms of a particular spatial orientation. For example, a "Lead II" ECG shows how the voltage travels through the heart along the frontal plane. The 12-lead electrocardiograph uses 10 electrodes placed in standard locations on the patient's skin (see Figure 4.1 below). In this lab we will use only the 4 electrodes, placed on the limbs, with the one on the right leg being the ground. This will allow viewing of Leads I, II, and III (Figure 4.2). The greater the number of leads an electrocardiograph uses, the more information the ECG provides.

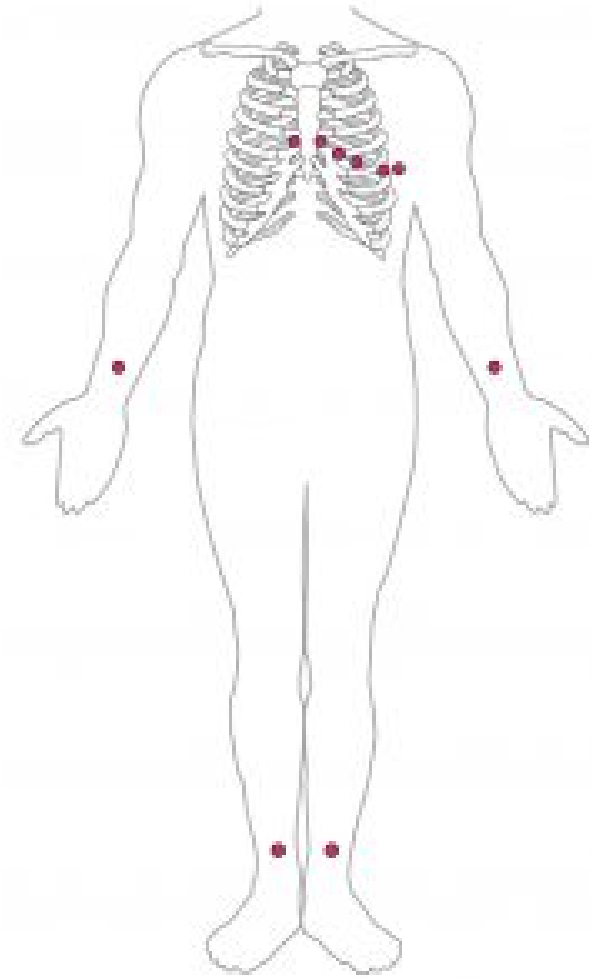

Figure 4.1. Standard Placement of ECG Leads by Open Stax / CC BY 4.0. Download for free at Open Stax.

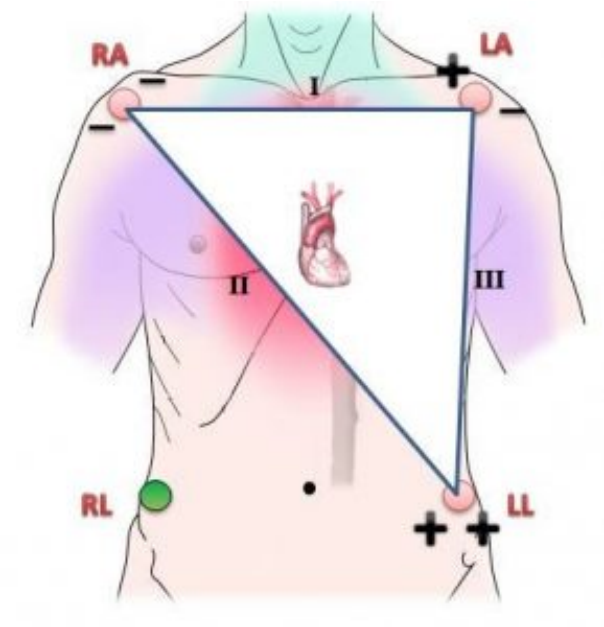

Figure 4.2. Leads I, II, and III.

Image derived from "Angina pectoris" by Ian Furst / CC BY-SA 3.0 and "Bipolar electrodes for leads I, II, and III" by Paul Sakuma / CC BY-SA 4.0

We will place our electrodes on the wrists for RA & LA and ankles for RL & LL.

A normal ECG tracing is presented in Figure 4.3. Each tiny square, 1mm, is the passing of 0.04 seconds. Notice there are 25mm every 1 second. You will use this when determining the values on your own ECG today. Segments are defined as the regions between two waves. Intervals include one segment plus one or more waves. Each wave, segment, and interval is related to electrical events associated with various stages of contraction and relaxation of the heart.

- P wave: Depolarization of the atria.
- PR interval: Time for voltage to travel from the SA node, through the atria, and into the ventricles.

- P-R segment: Time for voltage to travel from AV node to ventricles.
- QRS complex: Depolarization of the ventricles. The repolarization of the atria occurs during the QRS complex, which masks it on an ECG.
- S-T segment: Measures the delay between ventricular depolarization and repolarization.
- QT interval: The total time of the ventricular depolarization and repolarization cycle.
- T wave: repolarization of the ventricles.

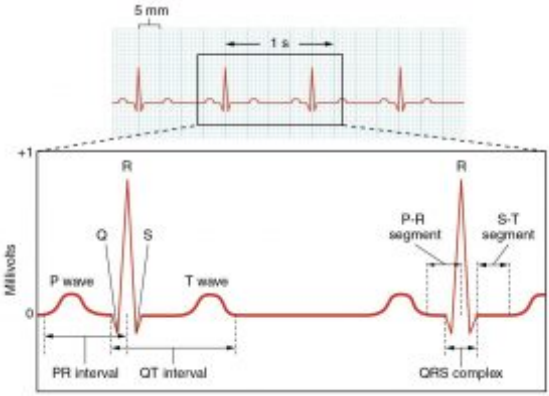

Figure 4.3. Electrocardiogram

Electrocardiogram by Open Stax / CC BY 4.0. Download for free at Open Stax.

Instructions for ECG

1. Gently clean the skin, using alcohol and tissue, on the wrists and medial surface of the ankles in the four limb locations shown in Figure 4.1.
2. Apply the electrode pads and clip the appropriate ECG cable to

the pad.

3. Have your participant sit still with hands relaxed on lap. Place a fabric or paper folder in lap, between thighs and hands, if participant's hands are touching the skin of the thighs (e.g. wearing shorts).
4. Press <9> button to start recording. The machine will print the ECG and stop automatically.
5. Label (waves, intervals, etc.) on your ECG and record values for all the items shown in Figure 4.3.

The time between R wave peaks is the time for a cardiac cycle, which is also the time between heart beats. In addition to labeling your ECG, calculate the heart rate (beats per minute) using the number of squares between two consecutive R wave peaks. Write this out on your ECG printout. For example, using Figure 4.3 data, there are 20 tiny boxes (mm squares) between each peak of the R wave and each tiny box represents 0.04 seconds:

20 tiny boxes x 0.04 seconds/1 tiny box = 0.8 seconds between R wave peaks.

Confirm 0.8 seconds looks correct based on the figure. Then:

1 heart beat/0.8 seconds x 60 seconds/minute = 75 beats/minute

Which units canceled out in the above equation?

Heart Sounds, Pulse, and Blood Pressure

Heart Sounds

Heart Sounds

A stethoscope is often used during auscultation, listening to sounds from body organs such as the lungs or heart. The healthy heart has two sounds, S1 (lub) and S2 (dup).

S1: blood turbulence from closing of atrioventricular valves.
S2: blood turbulence from closing of semilunar valves.

> The locations for best auscultation are not directly over the valves (Figure 4.4).
> What is directly over the valves (in between the heart and your stethoscope on the chest)? How might this be related to the auscultation sites?

Instructions for Heart Sounds

1. Using alcohol and wipes, clean the earpieces and stethoscope diaphragm and allow to dry.
2. Rotate the stethoscope earpieces so they will face slightly anterior before placing in your ears.
3. Facing your seated and relaxed partner, place the diaphragm of the stethoscope in each of the locations shown in Figure 4.4. Consider allowing your partner to place the stethoscope diaphragm over their own chest if that provides more comfort with the procedure.

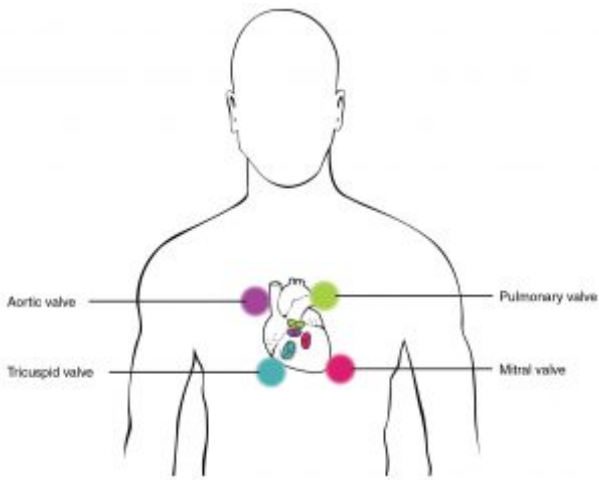

Figure 4.4. Stethoscope Placement for Auscultation.

Stethoscope Placement for Auscultation by Open Stax / CC BY 4.0. Download for free at Open Stax.

Pulse

Pulse

When the left ventricle contracts, creating the systolic pressure, a pressure wave travels through the arteries. This causes expansion and recoil of arteries that can be felt as a pulse at several body points (Figure 4.5).

Instructions for Pulse

1. On yourself and a partner, palpate at least three of the pulse sites below to feel confident you can find a pulse.
2. Select one site and take your partner's pulse for 60 seconds.

This is the heart rate in beats per minute. When you take the pulse in this manner, is it more or less accurate than using the ECG calculation based on R-R interval? Why?

3. Palpate the brachial pulse in preparation for the blood pressure lab that follows.

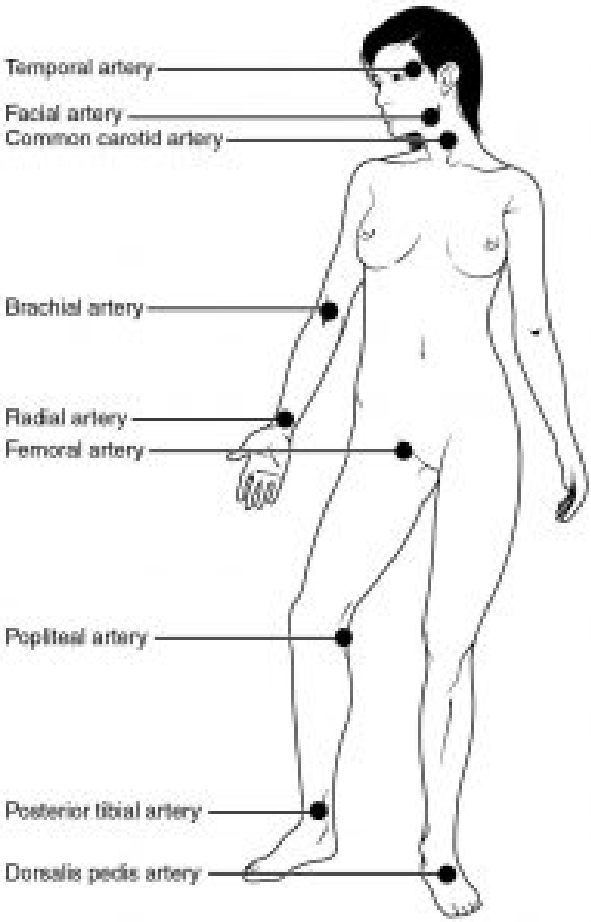

Figure 4.5. Pulse Sites

Pulse Sites by Open Stax / CC BY 4.0. Download for free at Open Stax.

Blood Pressure

Blood Pressure

As the heart contracts and relaxes, it creates a range of pressures against the blood vessel walls. Blood pressure is reported after taking two measurements:

> Systolic Blood Pressure (SBP) is the high arterial pressure caused by contraction of the left ventricle. The ideal range is 90-120 mm Hg.
>
> Diastolic Blood Pressure (DBP) is the low arterial pressure resulting from left ventricle relaxation. The ideal range is 60-80 mm Hg

The reading is recorded in this format SBP/DBP, for example 110/70.

> What is happening in the left ventricle when it is relaxing (diastole)?

To measure blood pressure, a sphygmomanometer is used. It is a cuff that blocks blood flow, an attached bulb and valve to control pressure, and a pressure dial for reading values (Figure 4.6). When the cuff is wrapped around upper arm and inflated enough to block the blood flow to the lower arm, the pressure is slowly released allowing readings to be taken for SBP and DBP (Figure 4.7). Traditionally this required use of a stethoscope to listen to noise from blood turbulence (Korotkoff sounds) at the brachial artery. Clinically, it is commonly automated and the stethoscope is not necessary.

Figure 4.6. Sphygmomanometer and Cuff / CC0

Sphygmomanometer and Cuff / CC0

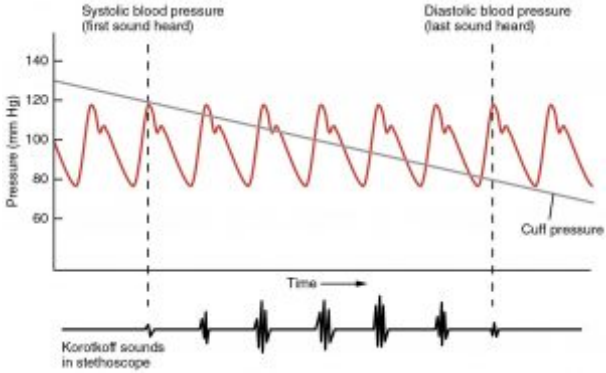

Figure 4.7 Blood Pressure Measurement.

Blood Pressure Measurement by Open Stax / CC BY 4.0. Download for free at Open Stax.

Instructions for Blood Pressure

Before beginning, view this video on blood pressure deflation rate.

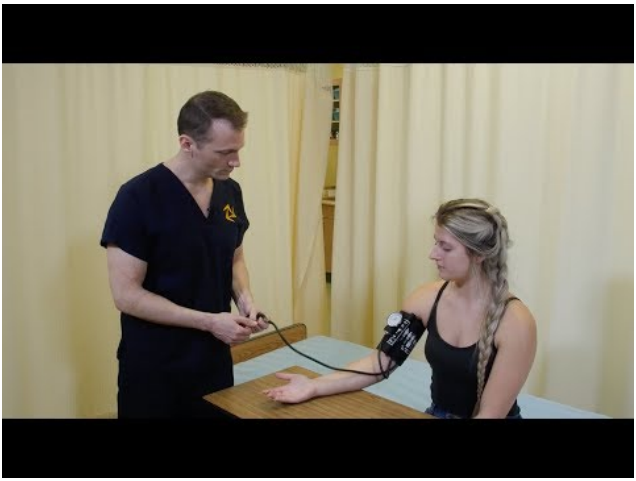

A YouTube element has been excluded from this version of the text. You can view it online here: http://pressbooks.oer.hawaii.edu/anatomyandphysiology2lab/?p=51

Video 4.1. Blood Pressure – Deflation Rate, Ryerson University / CC BY

1. Get comfortable opening and closing the pressure valve so you can hold the bulb and operate the valve easily with one hand. Turning valve to the right closes (right-tight) and turning to the left opens (left-loose). With the valve opened, squeeze all the air out of the cuff.
2. With your participant comfortably seated and arm resting on lab table, wrap cuff around the upper arm (brachium), about two fingers above the cubital fossa. The cuff arrow should be positioned over the brachial artery pulse point that you identified in the pulse-taking activity. Verify this positioning by palpating the brachial pulse. Secure the cuff loosely enough

that you can just slip two fingers inside between the cuff and the arm. Clip the pressure dial to the loop of the cuff so you can easily read it.

3. Place stethoscope earpieces in ears, and with one hand, hold the stethoscope diaphragm in place over the brachial artery (Figure 4.8).
4. In the next step you will inflate the cuff. Once the cuff is inflated, do not keep it inflated for more than 1 minute. Also, if you inflate the cuff and have difficulty taking the reading, change arms and start over so the original arm blood flow can reestablish.
5. Inflate the cuff to 160 mm Hg, notice you hear no sounds. While watching the pressure dial, slowly release the pressure while listening for the first sound of blood turbulence (Korotkoff sound). Notice and remember the pressure when you first hear the sound. This is the systolic blood pressure (SBP). There is turbulence because the vessel is constricted too much for a quiet smooth flow.
6. Continue slowly releasing the pressure as you listen for the instant the sounds go away. Note this mentally as the diastolic blood pressure (DBP). Silence means the blood is flowing smoothly and quietly. Release the rest of the pressure in the cuff and record your values as SBP/DBP.

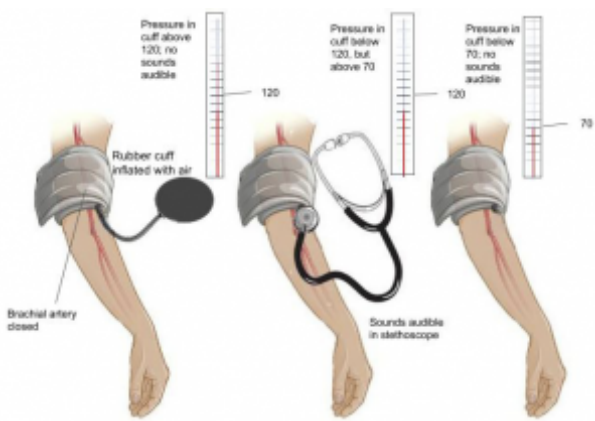

Figure 4.8. Blood pressure measurement of 120/70.

Image by Ashley Kajioka / CC BY 4.0

"Cardiovascular Experiments" is MODIFIED from:

Content on Electrocardiogram is modified from OpenStax College, Anatomy and Physiology.

Download for free at http://cnx.org/contents/14fb4ad7-39a1-4eee-ab6e-3ef2482e3e22@12.8.

SHERYL SHOOK

Heart Dissection

Learning Objectives

- Demonstrate proficient dissection skills.
- Identify external anatomical structures of the heart.
- Identify internal anatomical structures of the heart.

1. Instruments

Figure 5.1. Surgical instruments. Image by Karolinska Institutet / [CC BY 4.0]

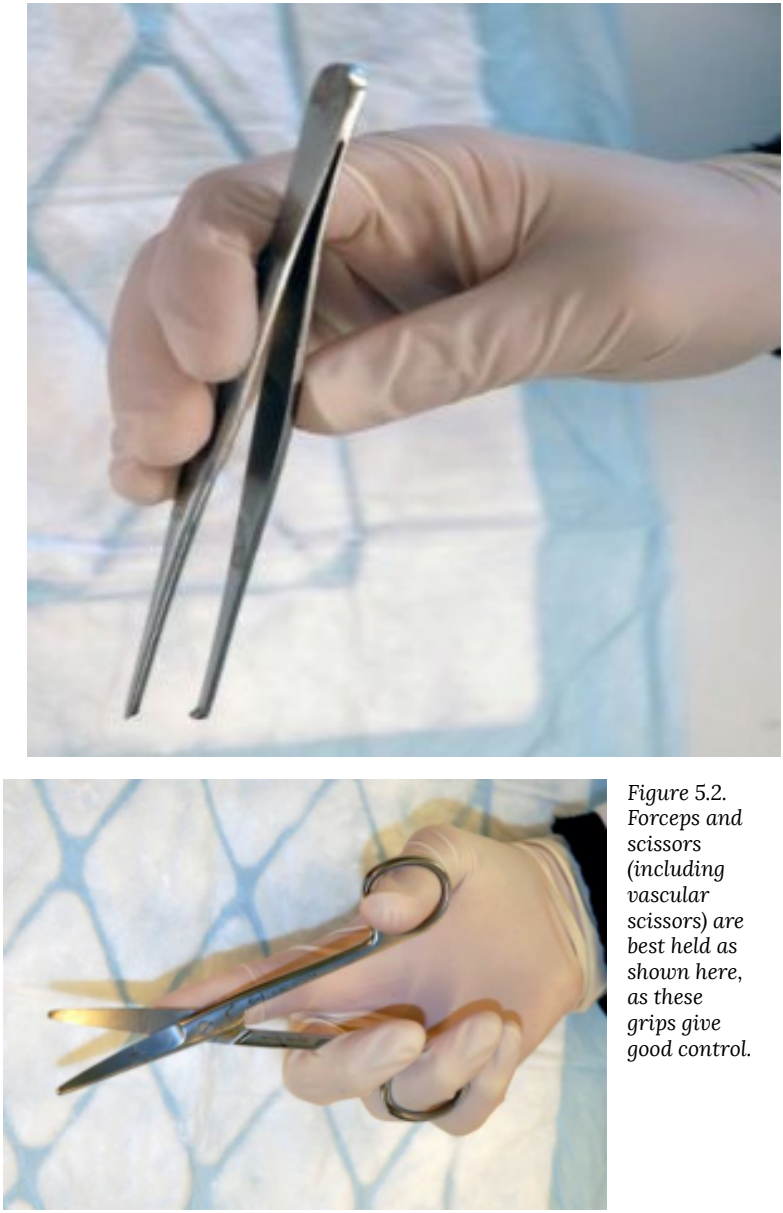

Figure 5.2. Forceps and scissors (including vascular scissors) are best held as shown here, as these grips give good control.

Images by Karolinska Institutet / CC BY 4.0

2. Surface anatomy of the heart

Begin by orienting the heart (Figure 5.3). Take note of its size and shape. Specimens may or may not have been perfused with a preservative that will cause a different heart color than shown. Identify the following landmarks:

- Apex
- Auricles
- Demarcation between the right and the left ventricle (interventricular septum)
- Entrances of superior vena cava and inferior vena cava
- Coronary blood vessels

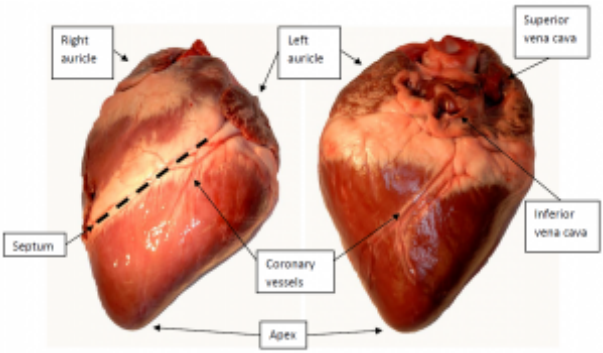

Figure 5.3. Left: Frontal view of the heart. Right: Posterior view.

Image by Karolinska Institutet / CC BY 4.0

The heart commonly has some adipose tissue on the outer surface. You also may find cuts that have been made when the heart was removed from the chest cavity.

The auricles are appendages to the atria. Their function is not

entirely known. It has been speculated that they function as reservoirs for blood, which may be mobilized in times of increased physiological need.

3. Aorta and the pulmonary arteries

Several vessels extend from the superior (topmost) side of the heart. It may be necessary to remove excessive tissue to visualize structures and for ease of dissection. Identify the aorta and the pulmonary artery and then cut them to make the valves visible (Figure 5.4). The aortic and pulmonary valves are each made up of three leaflets. Inspect the valves and palpate them (feel them with a finger).

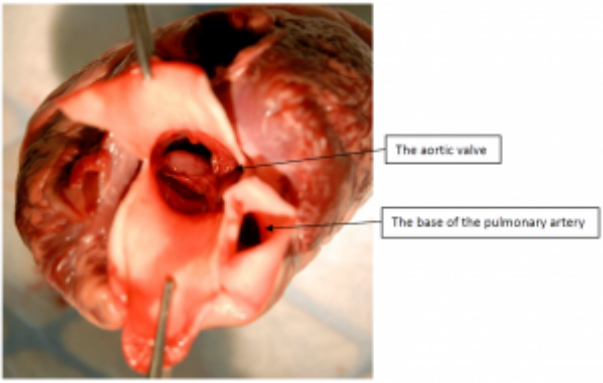

Figure 5.4. The aortic valve and base of the pulmonary artery.

Image by Karolinska Institutet / CC BY 4.0

Try pouring a little water on the valve and see if the valve closes.

Thought question:

Why do the arteries leading blood from the heart have thicker walls than the veins leading blood back to the heart?

4. Coronary arteries

The two main coronary arteries branch off from the aorta just above the aortic valve. Start by probing the coronary artery entrance (Figure 5.5). By gripping the heart with the forceps next to the entrance of the artery, you may straighten out the closest part of the artery, which makes it easier to cut. Cut the coronary arteries starting from the aorta and proceeding along one or more branches as far as their size permit (Figure 5.6). Use the forceps to visualize the opened the artery (Figure 5.7).

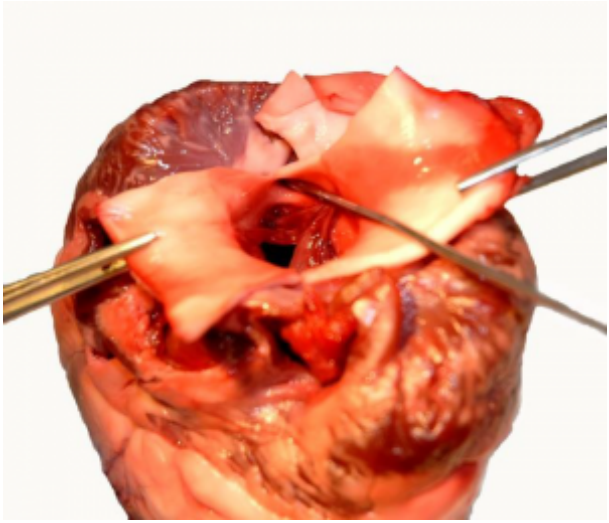

Figure 5.5. Probing of the entrance to the left coronary artery.

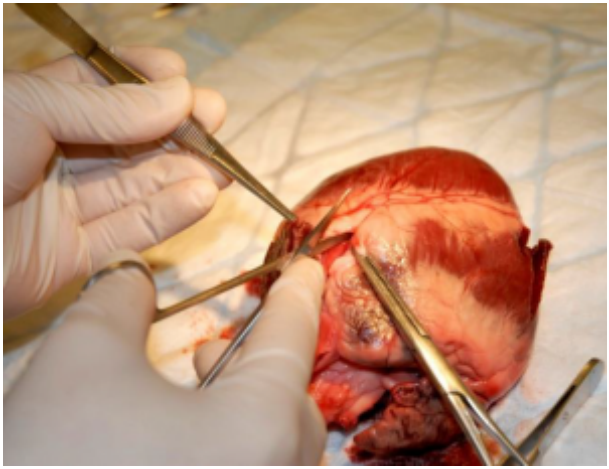

Figure 5.6. Cutting open the coronary artery.

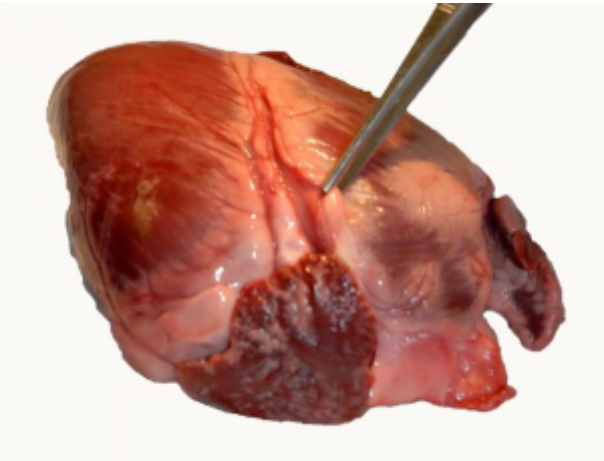

Figure 5.7. Opened coronary artery.

Images by Karolinska Institutet / CC BY 4.0

Thought question:

In angina or myocardial infarction, the myocardium (heart muscle) receives insufficient blood flow. The effect of diminished flow in one coronary artery depends on, among other things, whether other arteries can compensate for the decreased flow. The anatomy of the coronary vessels may vary greatly between individuals. How much of the heart appears to receive its blood supply from only one single artery?

5. The right atrium

Identify the openings for the superior and inferior vena cavae (Figure 5.8). Cut open the right atrium along the path between the vena cavae openings and continue into the auricle (Figure 5.9). Remove any coagulated blood that may be found here. Take note of the smoothness of the endocardium, the tissue lining the inside of the heart. Also notice the pectinate muscles.

During fetal life, when lungs are not used for gas exchange, there is an opening—foramen ovale. This opening normally closes at birth, leaving a shallow pit—fossa ovalis—in the myocardium. Sometimes, a small opening may persist, and is then termed a patent foramen ovale. Find the fossa ovalis and examine with a probe whether any opening remains (Figure 5.10).

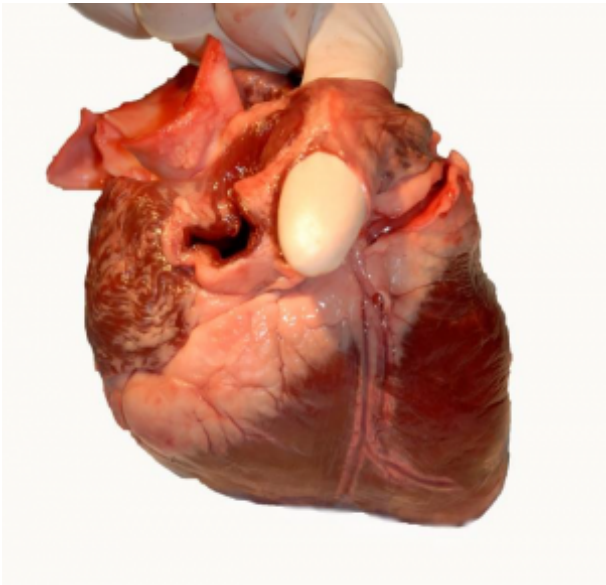

Figure 5.8. The two entrances of the vena cavae.

Image by Karolinska Institutet / CC BY 4.0

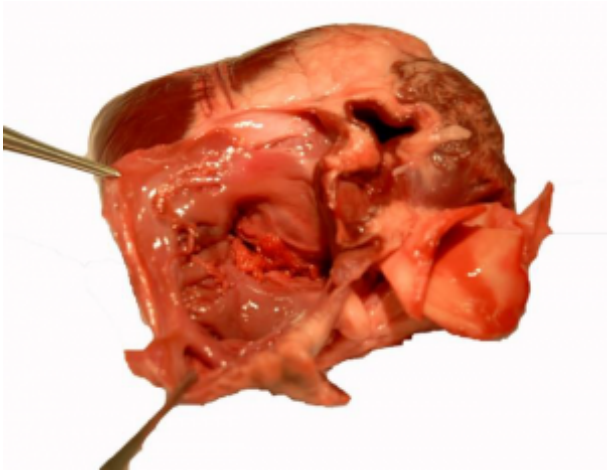

Figure 5.9. The right atrium, cut open.

Image by Karolinska Institutet / CC BY 4.0

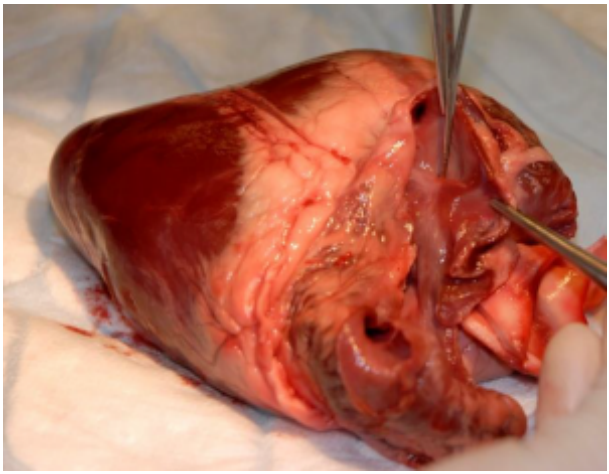

Figure 5.10. Probing of the fossa ovalis.

Image by Karolinska Institutet / CC BY 4.0

Thought question.

Deep venous thromboses are not uncommon. They may give rise to a thromboembolism, when part of a blood clot comes off, and is transported by the blood to some other part of the body thus blocking the blood flow. How would a patent (open) foramen ovale affect the range of possible outcomes?

6. The right ventricle

Cut open the right ventricle through the opening from the right atrium, along the right side of the heart (Figure 5.11). You will then cut through the tricuspid valve. Open the right ventricle and take note of the valve (Figure 5.12). This valve has three cusps, which are attached to papillary muscles extending from the inner wall of the ventricle. Observe and palpate the valve (Figure 5.13). Proceed to examine the muscular wall of the ventricle and take note of the trabeculae carneae (beam-like structures). Finally, identify the pulmonary valve and probe it from the inside of the ventricle.

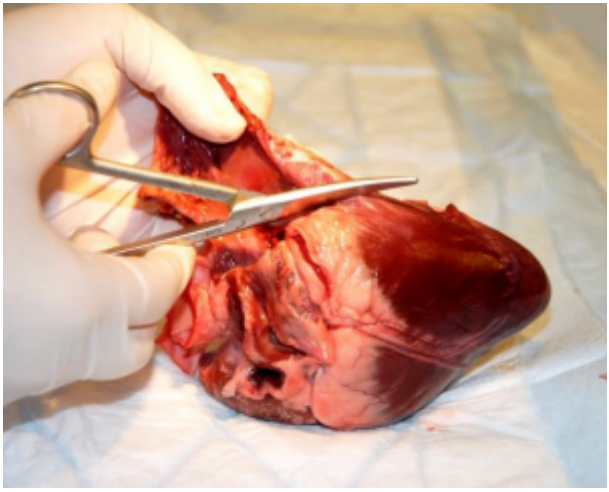

Figure 5.11. Cutting open the right ventricle.

Image by Karolinska Institutet / CC BY 4.0

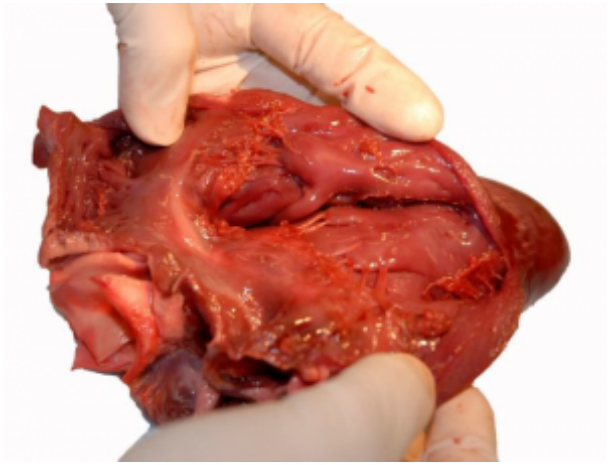

Figure 5.12. Inside of the right ventricle.

Image by Karolinska Institutet / CC BY 4.0

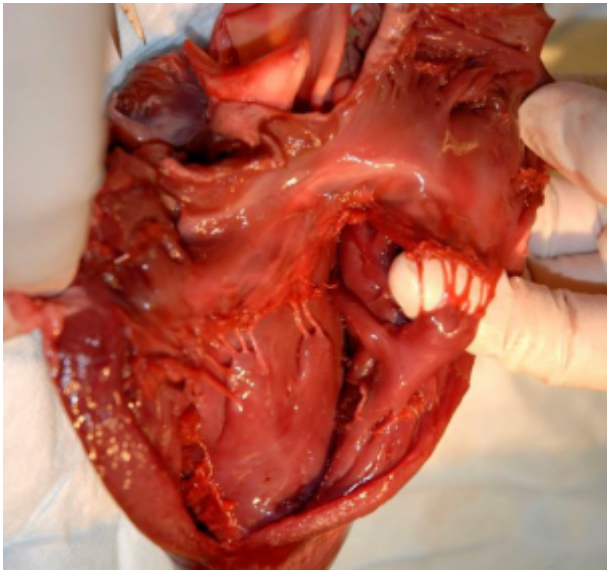

Figure 5.13. One of the cusps of the tricuspid valve, held up by a finger. Note the papillary muscle and chordae tendineae.

Image by Karolinska Institutet / CC BY 4.0

Thought question:

Can you trace the blood flow out of the right ventricle? What organ is the first to receive this blood?

7. Left atrium and ventricle

Cut open the left atrium and ventricle through the entrance for the pulmonary vein into the left atrium (Figure 5.14). Cut along the left side of the heart. The valve between the left atrium and ventricle has

two cusps and is termed the bicuspid or mitral valve (miter = type of hat that tapers to a point). Examine the endocardium and the mitral valve (Figure 5.15). Identify the entrance to the aorta and probe it from the inside of the left ventricle.

Compare the right and left ventricles with regard to their respective sizes and the thickness of the myocardium. Finally, palpate the muscle wall between the right and left ventricles (interventricular septum). Here run the right and left bundle branches, part of the electrical conduction system of the heart.

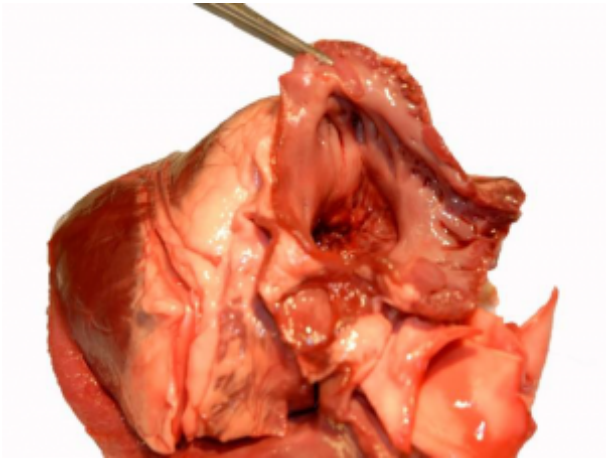

Figure 5.14. Left atrium.

Image by Karolinska Institutet / CC BY 4.0

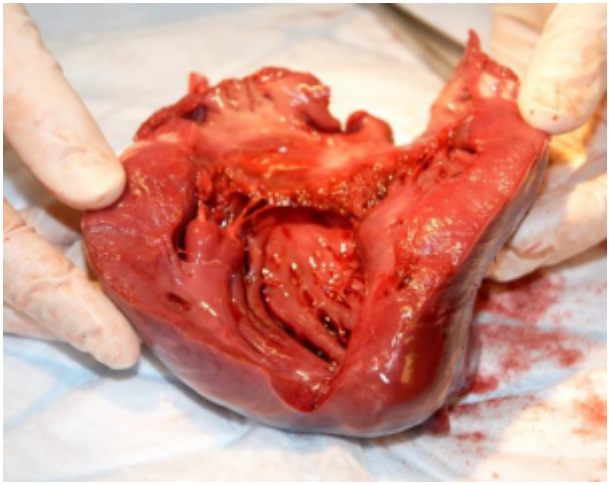

Figure 5.15. Left ventricle.

Image by Karolinska Institutet / CC BY 4.0

Thought question:

Why is the myocardium of the left ventricle thicker than that of the right ventricle?

"Heart Dissection" is MODIFIED from:

- Dissection manual for porcine heart by Karolinska Institutet / CC BY 4.0
- Text: Gustav Nilsonne
- Photos: Lotta Arborelius

SHERYL SHOOK

Respiratory System Anatomy

Learning Objectives

- Identify respiratory system gross anatomical structures.
- Identify respiratory system microscopic structures.

Gross and Microscopic Anatomy

Use local resources to view structures of the respiratory system.

Respiratory System Structures List

Respiratory System- Complete- Anterior view

- Trachea
- Upper right lobe of lungs
- Middle right lobe of lungs
- Lower right lobe of lungs
- Upper left lobe of lungs
- Lower left lobe of lungs

Respiratory System- Circulatory vessels and heart

- Right subclavian vein
- Right internal jugular vein
- Right brachiocephalic vein
- Superior vena cava
- Right atrium
- Right ventricle
- Pulmonary trunk
- Pulmonary veins
- Left atrium
- Left ventricle
- Aorta

Respiratory System- Tracheobronchial tree and lungs

- Right primary bronchus
- Left primary bronchus
- Diaphragm

Respiratory System- Larynx- Anterior view

- Hyoid
- Thyroid membrane
- Thyroid cartilage
- Cricoid cartilage

Respiratory System- Larynx- Posterior view

- Arytenoid cartilage

Respiratory System- Larynx- Left lateral view

- Esophagus

Supplemental Structures

- Horizontal fissure
- Oblique fissure

Attributions for “Respiratory System Anatomy”: Respiratory System Structures List by Marissa Sumida / CC BY 4.0

SHERYL SHOOK

Respiratory Physiology Experiment

Learning Objectives

1. Define the following and label on a graph of spirometry data:
    a. Inspiration
    b. Expiration
    c. Total Lung Capacity (TLC)
    d. Inspiratory Reserve Volume (IRV)
    e. Expiratory Reserve Volume (ERV)
    f. Tidal Volume (TV)
    g. Vital Capacity (VC)
    h. Forced Vital Capacity (FVC)
    i. Forced Expiratory Volume (FEV1)
    j. Residual Volume (RV)
2. Compare FVC to VC
3. Describe, and demonstrate skills to listen to, bronchial and vesicular breathing sounds.
4. Demonstrate proper lung function testing using a spirometer.
5. Explain the clinical significance of reduced lung volume vs. reduced FEV1 in the context of restrictive and obstructive respiratory disorders.

Sounds of the Respiratory System

Listening to respiratory sounds, auscultation with a stethoscope, provides an indication of the health of respiratory tissue and ventilation function.

Bronchial sounds – Measured over the tracheobronchial tree. High pitch, louder sound of air moving through trachea and bronchi.

Vesicular sounds – Measured over the lung tissue. Low pitch, soft rustling sound of the air moving the alveolar sacs.

View and listen to Video 7.1 for descriptions and samples of respiratory sounds.

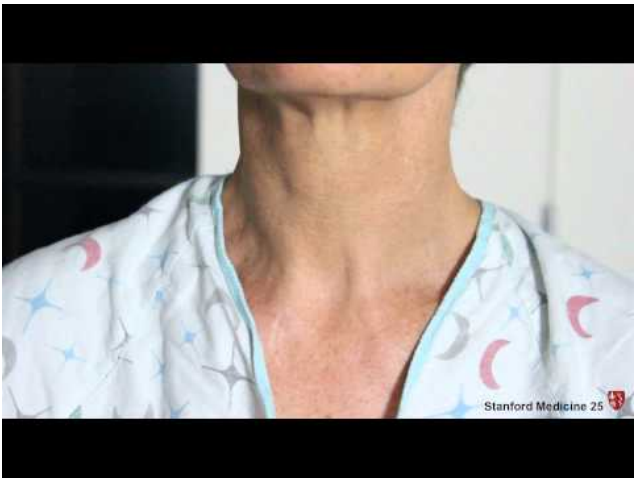

A YouTube element has been excluded from this version of the text. You can view it online here: http://pressbooks.oer.hawaii.edu/anatomyandphysiology2lab/?p=83

Video 7.1. Bronchial and Vesicular Breath Sounds, Stanford Medicine 25

Instructions for Respiratory Sounds

1. Using alcohol and wipes, clean the earpieces and stethoscope diaphragm and allow to dry.
2. Rotate the stethoscope earpieces so they will face slightly anterior before placing in your ears.
3. With the stethoscope diaphragm on the trachea above the suprasternal notch, listen to the bronchial sounds during normal breathing.
4. Find the soft area immediately medial to the inferior section of the medial margin of the scapula. This is the triangle of auscultation, a location optimized for listening to lung sounds because there are fewer muscles over the ribs. Convince yourself of this by looking at the muscle anatomy of the back; observe the small space between the trapezius and latissimus dorsi at this site. Listen to the vesicular sounds, heard primarily upon inspiration.

Lung Volume and Function Tests with Spirometry

Lung volumes can be measured to determine the level of respiratory system health as well as the presence of various respiratory disorders. For example, if someone has pneumonia or tuberculosis, they will have reduced lung volume, and thus a restrictive lung disorder. In lung volume testing, the values differ between healthy individuals based on levels of physical fitness as well as age, sex, and size, so keep in mind the numbers you see in the figure are averages. Table 7.1 shows pulmonary (lung) function test measures. The spirometer—a device that measures movement of air—will provide us with a recording of a range of lung volumes. Residual Volume (RV) is the air that is left in the lungs after a maximal

exhalation, so RV will be estimated today as 1.2 Liters. Capacities, such as Total Lung Capacity (TLC), refer to two or more volumes combined (Figure 7.1). One area that can cause some confusion for students is the reference to Vital Capacity (VC), Slow Vital Capacity (SVC), and Forced Vital Capacity (FVC). In healthy adult participants, VC, SVC, and FVC are practically the same. While VC and SVC are a full exhalation without a time requirement, FVC is forced as quickly as the patient can manage. For our data collection, we will call it FVC because your participant is going to exhale as quickly and forcefully as possible in order to measure the Forced Expiratory Volume in one second (FEV1) as a measure of asthma. To test for obstructive lung disorders such as asthma, the rate of air movement out of the lungs is measured to determine the level of resistance in the airways. If an air passage has increased resistance, the amount of air a person can exhale in one second (FEV1) will be less than for someone without a respiratory disorder.

Pulmonary function measure	Definition
Forced vital capacity (FVC)	Volume of air forcefully exhaled after maximum inhalation
Forced expiratory volume 1 (FEV1)	Volume of air forcefully exhaled, in the first second, after maximum inhalation.
Total lung capacity (TLC)	Volume of air contained in lungs after maximum inhalation.
Peak expiratory flow (PEF)	Maximum speed of forceful exhalation after a maximum inhalation
Residual volume (RV)	Volume of air in lungs after maximum exhalation
Tidal volume (TV)	Volume of air moved in or out of the lungs during relaxed, subconscious breathing
Inspiratory reserve volume (IRV)	Volume of air that can be inhaled beyond tidal inhalation
Expiratory reserve volume (ERV)	Volume of air that can be exhaled beyond tidal exhalation
Residual volume (RV)	Volume of air remaining lungs after maximum exhalation

Table 7.1 Pulmonary Function Testing

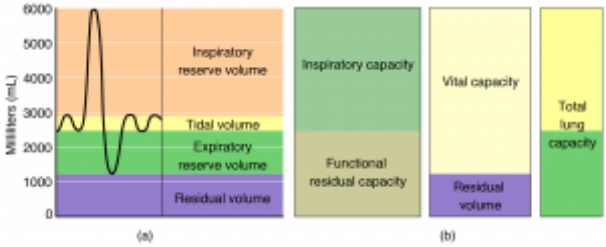

Figure 7.1 Respiratory Volumes and Capacities.

Image by Open Stax / CC BY 4.0. Download for free at Open Stax. ab6e-3ef2482e3e22@12.8″>

Instructions for Spirometry

You have the opportunity to use two different types of spirometers today and then compare the data. It does not matter which device you use first.

Micro I Portable Spirometer

1. If not charged, connect power supply cord to spirometer and then plug into electrical outlet and wait 5 minutes. Spirometer will not work while plugged in. After 5 minutes, unplug from outlet and disconnect power supply cord from device.
2. Attach mouthpiece adaptor (2-inch white plastic tube) to spirometer. This piece is not disposable. Please note the storage location before removing from the case.
3. Attach small end of disposable filter (has disc-like piece in middle) to mouthpiece adaptor.
4. Press on/off button at top of device.

5. Select Quick Exam ("Enter" is the bottom right, of the four buttons on front).
6. Display will show person blowing into unit. This means device is ready.
7. Inhale as deeply as possible, seal lips around mouthpiece, exhale as hard and fast and long as possible until no more air can be exhaled.
8. If test needs to be repeated (e.g. display reads "Poor Effort"), use up and down arrows to select "Blow Again" and press Enter.
9. Record your data.
10. Separate filter from mouthpiece holder to be sure you do not throw the mouthpiece holder away.
11. Return mouthpiece holder to storage case.
12. Place disposable filter in biohazard waste. Only the filter is disposable.
13. To check out, show your professor the pieces in your unit's storage case to confirm all parts, including mouthpiece holder, are stowed properly.

Vernier Spirometer and Logger Pro Software

Materials:

- Laptop or desktop computer with Logger Pro software
- LabQuest Unit
- Vernier Handheld Spirometer
- Plastic disposable filter
- Nose clip
- Masking tape

Equipment and Computer Setup

Caution: If you have a respiratory illness, such as the flu or a cold, do not be the participant in this experiment.

1. Do not turn on anything yet.
2. Plug in the LabQuest unit into an electrical outlet. Note: If you're using the iMac computers in the STEM A&P lab, skip to step 4 below. The LabQuest unit is on the back of the iMac computer.
3. Attach the USB cable to the Lab Quest unit and to an available USB port on the laptop or desktop computer.
4. Plug the spirometer into "Ch 1" of the LabQuest unit.
5. Turn on the computer (If you're using a laptop, make sure it's plugged in to an outlet).
6. Open the Logger Pro application.
7. Click on "File" in the upper toolbar, "Open Recent," then select "19 Lung Volume."
8. Click on "Page" in the upper toolbar and select "Next Page." You should now see a new page on the screen titled "Pg 2: Lung Volume Measurements" with two graphs ("Lung Volume and Capacity" & "Flow Rate").
9. Turn on the LabQuest Unit by pressing the power button on the upper left hand corner. This step is not necessary if using iMac in STEM A&P lab.

Participant Instructions

1. Connect the white plastic bacterial filter to the side of the handheld spirometer marked "Inlet."
2. While holding the spirometer straight and still, not yet in the mouth, click on "Experiment" in the upper toolbar and select "Zero." This sets a baseline where there is no air movement through the spirometer and the participant does not have the

spirometer in their mouth.

3. Prepare your participant for the beginning of the test by having them stand, put on the nosepiece or plug nose with fingers, seal lips around the filter mouthpiece and begin breathing normally into the spirometer. Notice there is no data recording happening at this point; it is preparing the device for collection. Remind the participant that they need to try to breathe normally…a challenge with this setup!
4. After a few normal breaths, the participant signals the computer computer operator when they are at the end of a normal expiration. Decide on the signal (e.g. a wiggle of the tiny finger on the hand holding the spirometer) before beginning recording. At the signal from the participant, the computer operator clicks on the green record button (upper right hand corner of the screen).
5. The data collection portion of the experiment has your participant beginning the experiment by taking:
    1. Three normal breaths, followed by
    2. A maximal inspiration, followed by
    3. A maximal, forceful, fast expiration, followed by
    4. Three normal breaths
6. The participant completes steps “a” through “d” (#5 above) after which the computer operator clicks on the red stop button. You should now see results that look something like this:

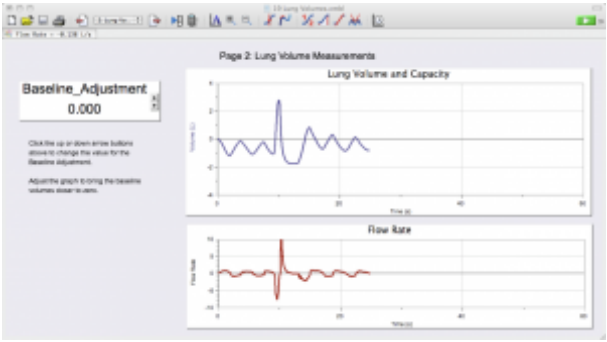

Figure 7.2. Sample data.

If your results don't look like the example in Figure 7.2, click on "Data" in the top toolbar and select "Clear All Data," then start over at step #3.

Measuring Tidal Volume (TV)

1. Place the cursor over the graph and you will see a set of crosshairs appear. Place the crosshairs at one of the valleys in the participant's tidal volume traces and drag it up to the next peak. You will see a blue highlighted box that appears (Figure 7.3).

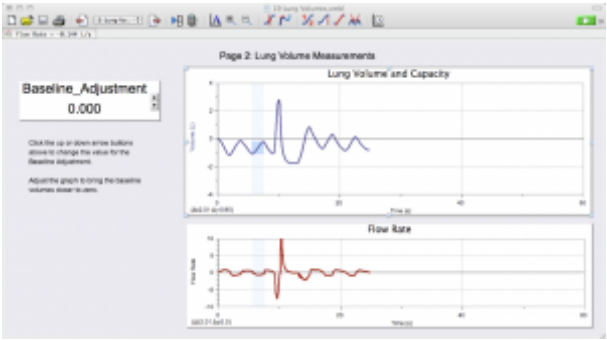

Figure 7.3. Selected data shown in blue shaded area.

2. Your lab group needs to record the Δ y value (0.95 Liters in this example) found in the bottom left corner of the top graph. This is your participant's TV.
3. Now repeat the process of creating a highlighted box from valley to peak and recording the Δ y value for:
4. Inspiratory Reserve Volume (IRV)
5. Expiratory Reserve Volume (ERV)

See Figures 7.4 and 7.5 for sample graphs of these two measurements

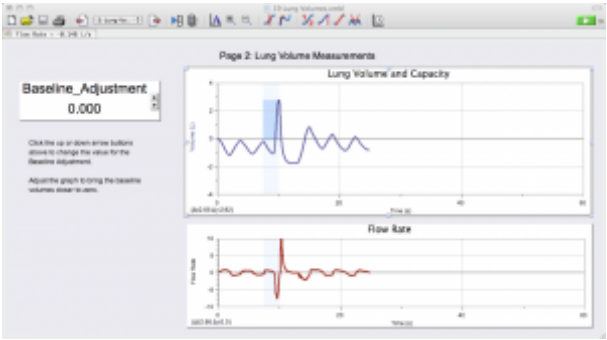

Figure 7.4. IRV: Peak of tidal volume to peak of inspiration. The Δ y value in this example is 2.92 Liters.

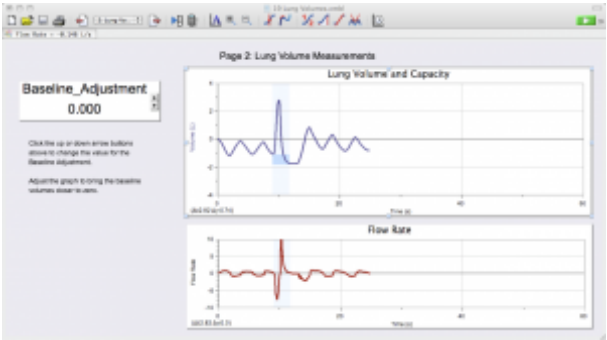

Figure 7.5. ERV: Valley of tidal volume to valley of expiration. The Δ y value in this example is 0.74 Liters.

Performing the Lung Function Tests

1. Click on "File" in the upper toolbar, "Open Recent," then select "21 Analyze Lung

Function." The following screen (Figure 7.6) will open on your computer:

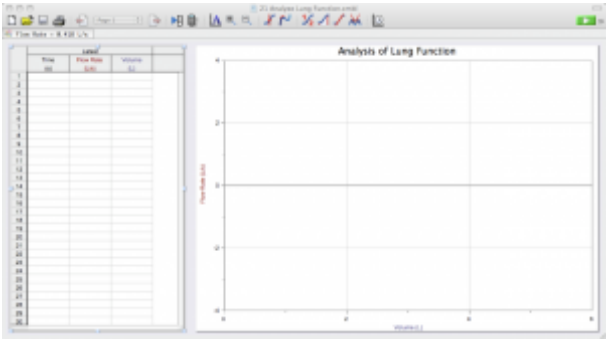

Figure 7.6. Opening screen for lung function analysis.

2. The only difference in running this test compared to the previous one is that the person at the computer will click the green record button when the participant signals that they are at the bottom of a normal expiration. Immediately after this signal, the participant will:
3. Complete a maximal inspiration, followed by
4. A maximal expiration, followed by
5. A maximal inspiration.
6. As soon as the participant completes their maximal inspiration, the computer operator clicks on the red button to stop the recording.

The resulting graph should be similar to the example in Figure 7.7:

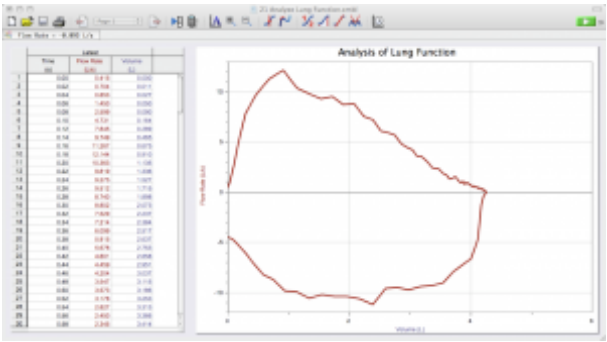

Figure 7.7. FEV1 data.

Measuring Forced Expiratory Volume in One Second (FEV1)

1. Scroll down the left column (Time) until you get to the 1.00 (one second), then record the value in the third column (Volume in Liters). This is your participant's FEV1. In the example below (Figure 7.8), the participant's FEV1 is 3.972 Liters.

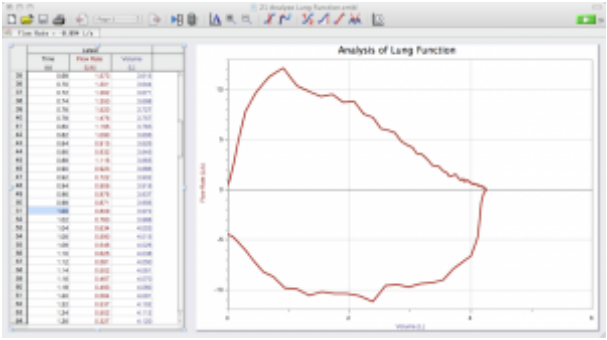

Figure 7.8. Participant's FEV1 is shaded in blue.

Measuring Forced Vital Capacity (FVC)

1. Click on "Analyze" in the top toolbar and then click on the "Examine" function.
2. This will make a vertical line appear when you move your cursor over the graph.

Move that vertical line to the farthest point to the right of the FVC trace and record the value in the small box at the top of the graph. In the sample below (Figure 7.9), the participant's FVC is 4.250 Liters.

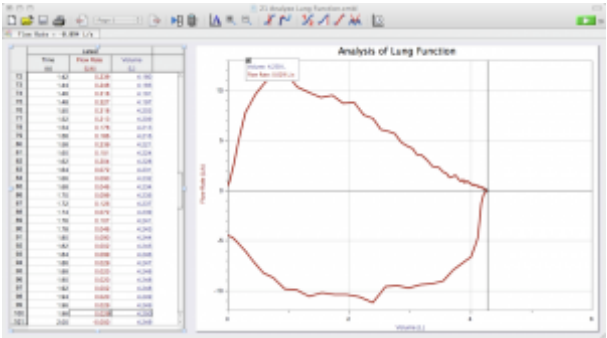

Figure 7.9. FVC data.

IMPORTANT: Please place disposable filters in biohazard bag provided by professor.

Label the graph (Figure 7.10), beginning with the axes, including units and values. Add in the names of the volumes and capacities.

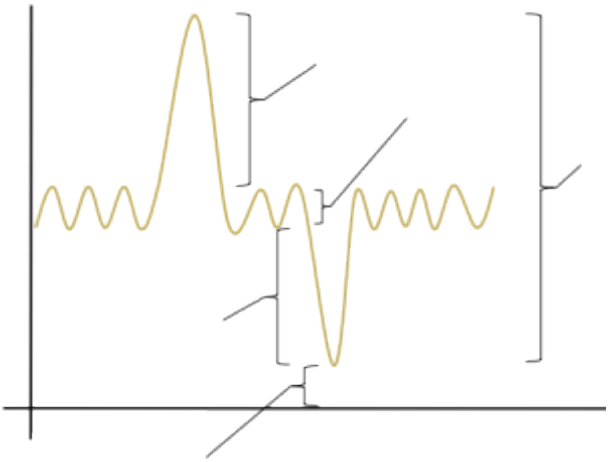

Figure 7.10. Lung Volumes and Capacities.

Image by Laird Sheldahl / CC BY 4.0

Attributions for chapter 7:

The instructions for Vernier Spirometer and Logger Pro Software are MODIFIED from Zoology 142L Lab Packet by Will Jonen / CC BY

SHERYL SHOOK

Digestive System Anatomy

Learning Objectives

- Identify digestive system gross anatomical structures.
- Identify digestive system microscopic structures.

Gross and Microscopic Anatomy

Use local resources to view structures of the digestive system.

Digestive System Structures List

1. Digestive System- Head and neck
    1. Nasal cavity
        1. Nasal conchae
    2. Hard palate
        1. Soft palate
    3. Nasopharynx
    4. Oral cavity

        1. Tongue
    5. Oropharynx
    6. Laryngopharynx
    7. Epiglottis
2. Digestive System- Upper abdomen
    1. Esophagus
    2. Stomach
    3. Duodenum of small intestine
    4. Pancreas
    5. Sphincter of oddi
    6. Liver
        1. Falciform ligament
        2. Left lobe
        3. Right lobe
        4. Common hepatic duct
    7. Gallbladder
    8. Common bile duct
    9. Spleen
3. Digestive System- Opened stomach
    1. Cardia
    2. Fundus
    3. Body
    4. Pyloris
    5. Greater curvature
    6. Lesser curvature
    7. Cardiac sphincter
    8. Pyloric sphincter
    9. Rugae
4. Digestive System- Lower abdomen
    1. Jejunum
    2. Ileum
    3. Ileocecal valve
    4. Cecum
    5. Appendix

    6. Ascending colon
    7. Transverse colon
    8. Descending colon
    9. Sigmoid colon
    10. Rectum
5. Supplemental Structures
    1. Caudate lobe of liver
    2. Quadrate lobe of liver
    3. Hepatic portal vein
    4. Hepatic artery

Attributions for “Digestive System Anatomy”:
Digestive System Structures List by Marissa Sumida / CC BY 4.0

SHERYL SHOOK

Urinary System Anatomy

Learning Objectives

- Identify urinary system gross anatomical structures.
- Identify urinary system microscopic structures.

Gross and Microscopic Anatomy

Use local resources to view structures of the urinary system.

Kidney Structures List

1. *Kidney- Frontal view*

    1. Renal capsule
    2. Renal cortex
    3. Renal medulla
    4. Renal pelvis
    5. Renal artery

    6. Renal vein
    7. Renal column
    8. Renal pyramid
    9. Renal papilla
    10. Renal calyces
        1. Minor calyx
        2. Major calyx
2. Kidney- Frontal view- Enlarged
    1. Segmental artery
    2. Interlobar artery
    3. Arcuate artery
    4. Interlobular artery
    5. Interlobular veins
    6. Arcuate veins
    7. Interlobar veins
    8. Segmental vein

Urinary System Structures List

1. Urinary System- Full view
    1. Adrenal gland
    2. Kidney
    3. Ureter
    4. Urinary bladder
2. Urinary System- Kidney
    1. Renal cortex
    2. Renal medulla
    3. Major calyx
    4. Renal pelvis
    5. Renal artery
    6. Renal vein
3. Urinary System- Bladder

    1. Detrusor muscle
    2. Trigone
    3. Ureteral openings
    4. Urethral opening
    5. Prostate gland
4. Supplemental Structures
    1. Urethra
        1. Prostatic urethra

Attributions for “Urinary System Anatomy”:
Kidney Structures List by Marissa Sumida / CC BY 4.0
Urinary System Structures List by Marissa Sumida / CC BY 4.0

SHERYL SHOOK

Reproductive System Anatomy

Learning Objectives

- Identify male and female reproductive system gross anatomical structures.
- Identify male and female reproductive system microscopic structures.

Gross and Microscopic Anatomy

Use local resources to view structures of the reproductive system.

Female Reproductive Structures List

1. Complete Female Reproductive System- Anterior view
    1. Ovary
    2. Ovarian ligament
    3. Oviduct (Fallopian tube)
2. Complete Female Reproductive System- Lateral view
    1. Ilium

    2. Piriformis muscle
    3. Internal obturator muscle
3. Female Pelvis- Organs removed- Anterior view
    1. Sacrum
4. Female Pelvis- Organs removed- Inferior view
    1. Labia minora
    2. Labia majora
    3. Sacrotuberous ligament
    4. Sacrospinal/sacrospinous ligament
    5. Levator ani muscle
5. Excised Female Pelvis Organs- Superior view
    1. Broad ligament
    2. Round ligament of the uterus
    3. Ureters
    4. Recto-uterine fold
6. Female Pelvic Organs- Sagittal view
    1. Vagina
    2. Uterus
    3. Cervix
7. Female Pelvis- Sagittal view
    1. Urogenital diaphragm
    2. External anal sphincter
    3. Internal anal sphincter

Male Reproductive Structures List

1. Complete Male Reproductive System- Anterior view
    1. Penis
        1. Glans penis
    2. Corona
        1. Prepuce

    3. Scrotum
    4. Spermatic cord
    5. Ureters
2. Complete Male Reproductive System- Sagittal view
    1. Corpus cavernosum
    2. Corpus spongiosum
    3. Bulb of penis
    4. Fundiform ligament
    5. Spongy urethra
    6. Membranous urethra
    7. Bulbourethral gland
    8. Prostate gland
    9. Urogenital diaphragm
    10. Internal anal sphincter
    11. External anal sphincter
    12. Levator ani muscle
    13. Obturator internus muscle
3. Male Reproductive System- Accessory Organs- Sagittal view
    1. Prostatic urethra
    2. Ejaculatory duct
4. Male Reproductive System- Penis and testicle
    1. Scrotum
        1. External membrane
        2. Tunica dartos
        3. Fascia spermatica externa
        4. Cremaster muscle
        5. Fascia spermatica interna
        6. Testis
        7. Epididymis
        8. Ductus deferens

Attributions for “Reproductive System Anatomy”:

Female Reproductive Structures List by Marissa Sumida / CC BY 4.0

Male Reproductive Structures List by Marissa Sumida / CC BY 4.0

SHERYL SHOOK

Fetal Pig Dissection

Learning Objectives

- Identify external urogenital structures of the male and female fetal pig.
- Successfully complete dissection of the fetal pig.
- Identify, on your fetal pig, each structure from the labeled photographs.

Introduction

Several different pig dissections were used to obtain the photographs below. As a result, a structure shown in one photograph may look different than the same structure shown in another photograph. Some of the images have a pig that has been injected with a substance to show arterial flow in red and venous flow in blue. Your pig may or may not have that injection.

Orientation

The following words will be used to help identify the location of structures.

- **Anterior** refers to the head end. If a structure is anterior to another then it is closer to the head.
- **Posterior** refers to the tail end.
- **Dorsal** refers to the back side. The pig in the first photograph below is laying on its dorsal side.
- **Ventral** is the belly side. It is opposite the dorsal side. The pig in the first photograph below has its ventral side up.

External Structures

Obtain a fetal pig and identify the structures listed in the first photograph.

Use the photographs below to identify its sex.

Use your pig and also a pig of the opposite sex to identify the structures in the photographs below. The word "urogenital" refers to an opening that serves both the urinary (excretory) and the reproductive systems.

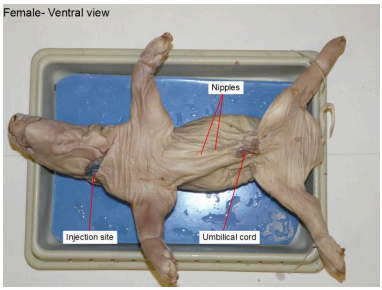

Figure 1. Female: injection site, nipples, umbilical cord.

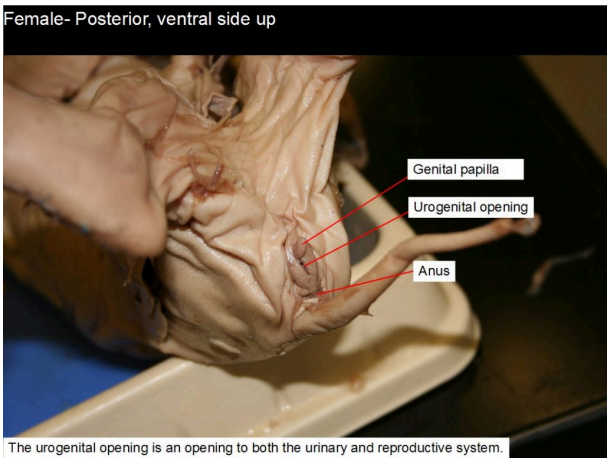

Figure 2. Female genital papilla, urogenital opening, anus

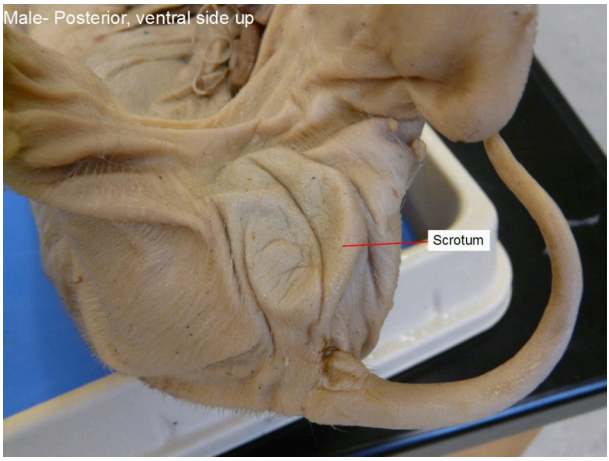

Figure 3. Male: scrotum.

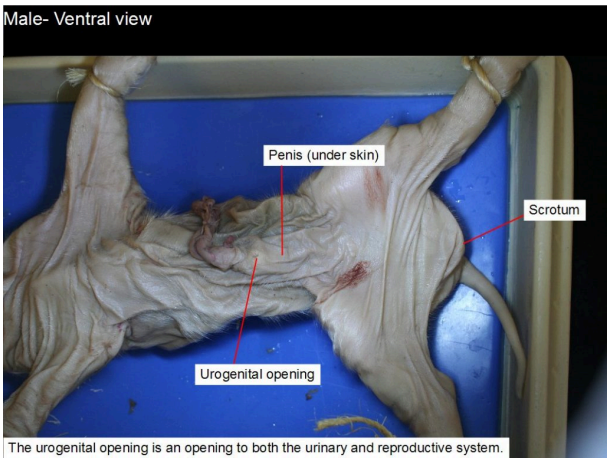

Figure 4. Male: urogenital opening, penis, anus.

Preparation and Initial Cuts

Tie one front leg of the animal with a string that passes underneath the dissecting pan to the other leg. Repeat this with the back leg.

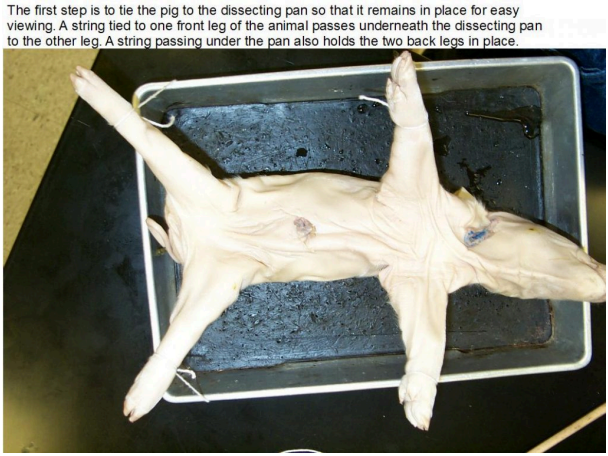

Figure 5. Securing the pig for the dissection.

Insert one blade of scissors through the body wall on one side of the umbilical cord and cut posteriorly to the base of the leg as shown in the first photograph below. Continue cutting from the anterior end of this cut so that it resembles an upside-down U. Your finished cut will be anterior to the navel and along each side of the navel. The flap of body wall that contains the navel can be folded posteriorly to reveal the internal organs of the abdomen.

One blade of the scissors is inserted through the body wall on one side of the umbilical cord and a cut is made posteriorly to the base of the leg.

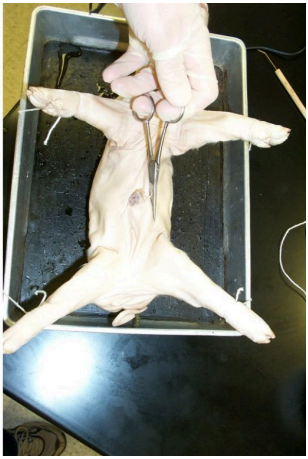

Figure 6. Making the first cut.

The cut is extended from the anterior end around the navel and then posterior again so that it resembles an upside-down U.

The finished cut is anterior to the navel and extends in a posterior direction on each side of the navel.

Figure 7. Completing the first cut.

The flap of body wall that contains the navel can be folded posteriorly to reveal the internal organs of the abdomen.

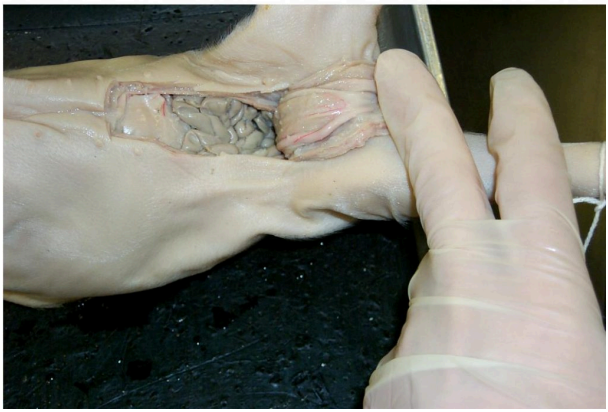

Figure 8. Pulling back the abdominal flap.

Extend a single cut along the midline of the ventral surface of the animal to about 2 cm from the chin. Cut completely through the body wall in the abdominal area but keep the cut shallow in the neck region.

A single cut is extended along the midline of the ventral surface of the animal to about 2 cm. from the chin. In the abdominal area, this cut is completely through the body wall but in the neck area, care must be taken to keep it shallow so that the underlying glands are not destroyed.

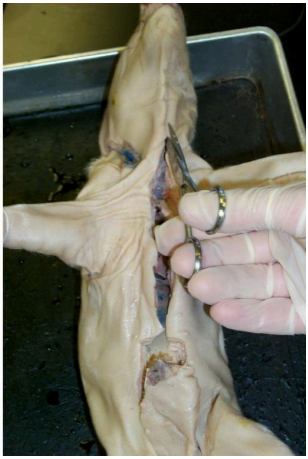

Figure 9. Mid-line thoracic cut.

A cut is made on the side of the animal from the point just posterior

to the diaphragm dorsally. A similar cut is made on the other side. These two cuts will enable you to spread open the abdominal cavity.

Figure 10. Opening the abdominal cavity.

Mouth and Neck Region

Use a scalpel to cut the sides of the mouth so that the bottom jaw can be opened for easier viewing (see the photograph below). You will need to cut through the musculature and the joint that holds the lower jaw to the skull.

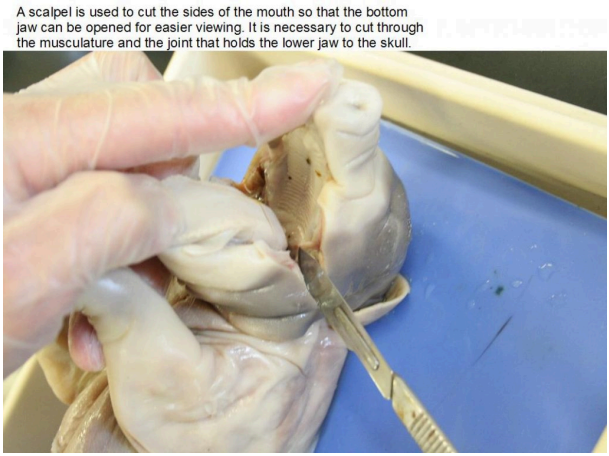

Figure 11. Opening the oral cavity.

Open the jaw wide enough so that the glottis and epiglottis are exposed. The epiglottis projects up into a region called the pharynx. The hard palate and soft palate separate the nasal and oral cavities. When breathing, air passes through the nasal passages to the nasopharynx. Air and food pass through the oropharynx, a space in the posterior portion of the mouth. Below the oropharynx, the laryngopharynx leads to the opening of the larynx and esophagus. From the laryngopharynx, air passes through the glottis to the trachea.

Below: hard palate, soft palate, glottis, epiglottis, tongue

The jaw is opened wide enough so that the glottis and epiglottis are exposed. The epiglottis projects up through the soft palate into a region called the nasopharynx. The hard palate and soft palate separate the nasal and oral cavities. When breathing, air passes through the nasal passages to the pharynx. The pharynx is the space in the posterior portion of the mouth that both food and air pass through. From the pharynx, it passes through the glottis to the trachea.

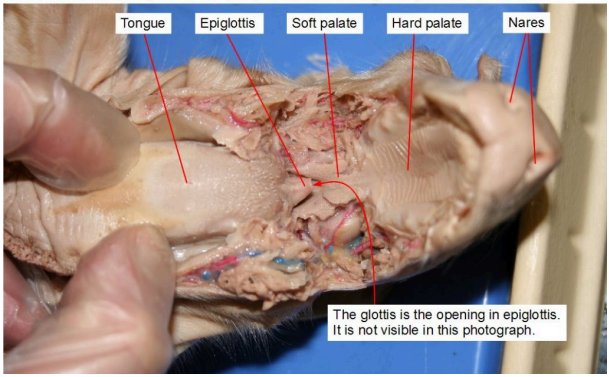

Figure 12. Oral cavity and pharynx.

Carefully, peel the skin away from the incision in the neck region using a blunt probe (a needle or the point of scissors will do if a blunt probe is not available). Use the probe to peel away muscle tissue until the thymus gland on each side of the trachea is exposed.

Use a probe to separate the two lobes of the thymus gland and to further separate the musculature over the trachea. The thyroid gland is darker and lies between the posterior ends of the two lobes of the thymus gland.

The skin is carefully peeled away from the incision in the neck region using either a blunt probe, a needle, or the point of scissors. The muscle tissue around the thymus gland is also peeled away until the thymus gland on each side of the trachea is exposed.

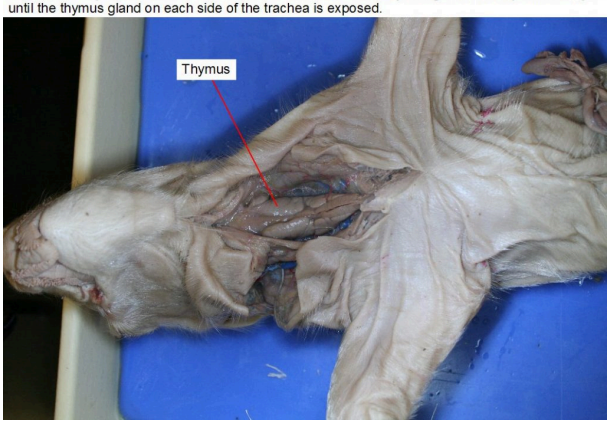

Figure 13. Thymus.

A blunt probe is used to separate the two lobes of the thymus gland and to further separate the musculature over the trachea. The thyroid gland is darker and lies between the posterior ends of the two lobes of the thymus gland.

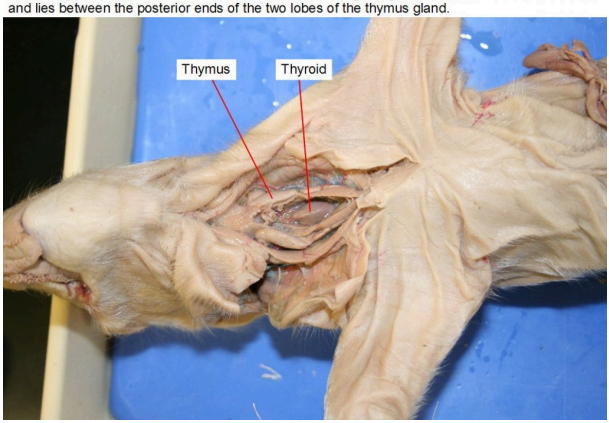

Figure 14. The surrounding tissues have been separated to reveal the thymus and thyroid gland.

Continue separating the tissue with a probe until the trachea and esophagus are exposed. The esophagus is dorsal to the trachea. The large hard structure attached to the trachea is the larynx. It contains the vocal cords.

In the photograph below, the heart and blood vessels of the neck region have been removed so that the trachea can be seen more clearly. You should not remove these structures yet because you will need to identify the blood vessels later in the dissection.

Below: esophagus, larynx, trachea, bronchus, lungs.

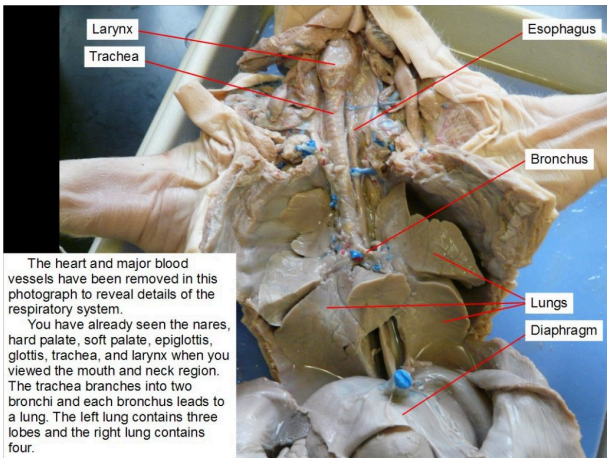

Figure 15. Respiratory system.

Respiratory System

Observe how the diaphragm attaches to the body wall and separates the abdominal cavity from the lung (pleural) and heart (pericardial) cavities (Photographs below). Contraction of the diaphragm forces air into the lungs.

You have already seen the pharynx, hard palate, soft palate, epiglottis, glottis, trachea, and larynx. Follow the trachea to where it branches into two bronchi and observe that each bronchus leads to a lung. The left lung contains three lobes and the right lung contains four. Each lung is located in a body cavity called a pleural cavity.

The diaphragm attaches to the body wall and separates the abdominal cavity from the lung (pleural) and heart (pericardial) cavities. Contraction of the diaphragm forces air into the lungs.

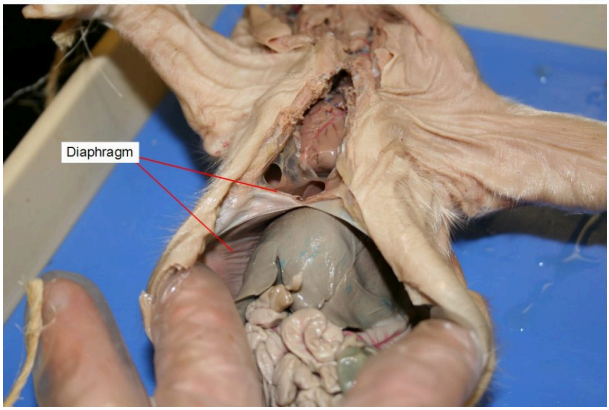

Figure 16. Diaphragm.

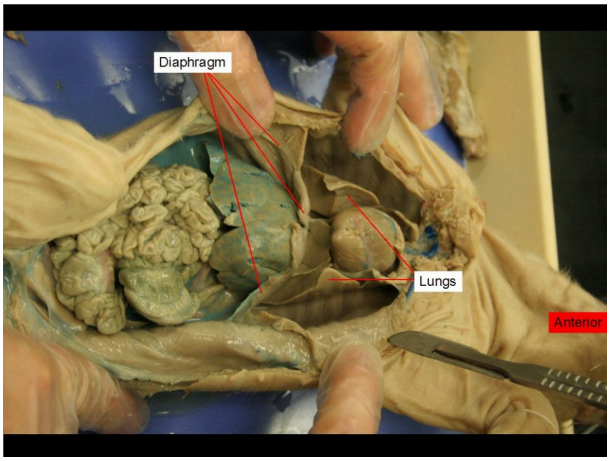

Figure 17. Diaphragm and lungs.

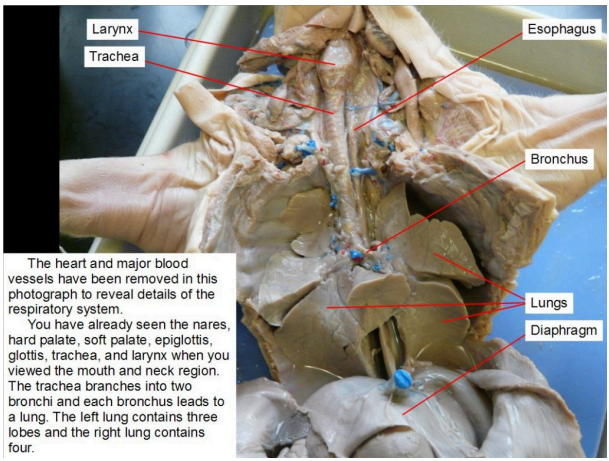

Figure 18. Esophagus, larynx, trachea, bronchus, lung.

Digestive System

You have already seen how the esophagus leads from the pharynx through the neck region. Using a probe, trace follow the esophagus to the stomach. Identify the small intestine and large intestine. Find the posterior part of the large intestine called the rectum and observe that it leads to the anus. Locate the cecum, a blind pouch where the small intestine joins the large intestine.

Identify the liver. Lift the right lobe and find the gallbladder. This structure stores bile produced by the liver. Find the bile duct that leads to the small intestine. The pancreas is located dorsal and posterior to the stomach. It extends along the length of the stomach from the left side of the body (your right) to the point where the stomach joins the small intestine. Lift the stomach and identify this light-colored organ.

The spleen is an elongate, flattened, brownish organ that extends along the posterior part of the stomach ventral to (above) the pancreas.

The cecum is a blind pouch where the small intestine joins the

large intestine. It houses bacteria used to digest plant materials such as cellulose. The cecum is large in herbivores but much of it has been lost during evolution in humans. The appendix in humans is the evolutionary remains of a larger cecum in human ancestors.

Food passes through the esophagus to the stomach, small intestine, and large intestine. The first part of the small intestine is the duodenum. Secretions released from the pancreas and gall bladder empty into the duodenum. In this photograph, the liver has been lifted to show the gall bladder attached underneath.

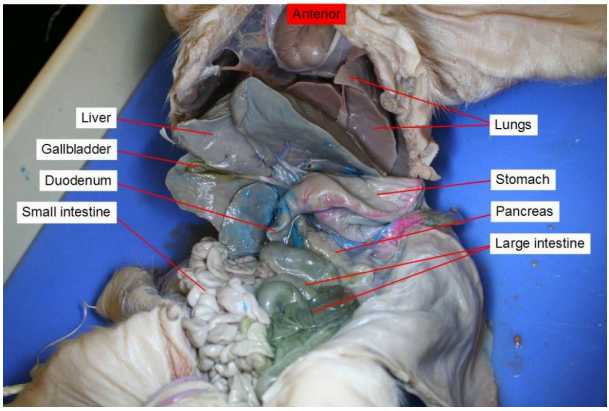

Figure 19. Digestive system.

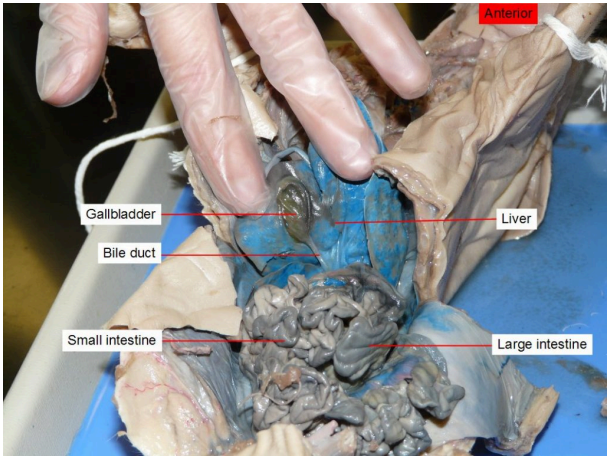

Figure 20. Digestive system with liver lifted to reveal gall bladder.

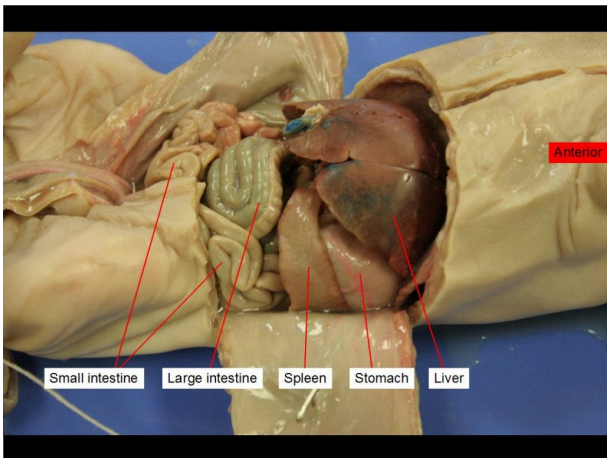

Figure 21. Digestive system with liver in place.

The stomach and spleen have been moved to the right to show the pancreas underneath. See the previous photograph to view these structures before they were moved.

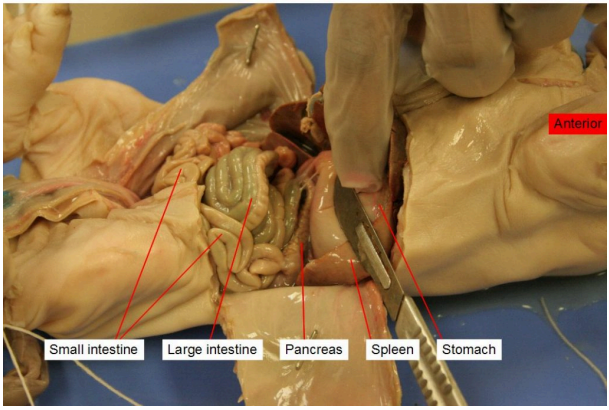

Figure 22. Abdominal cavity.

Figure 23. Stomach and liver lifted to show the pancreas.

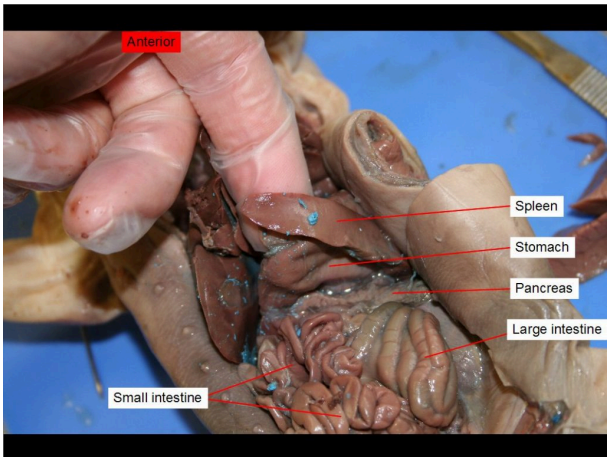

Figure 24. Lifting the spleen.

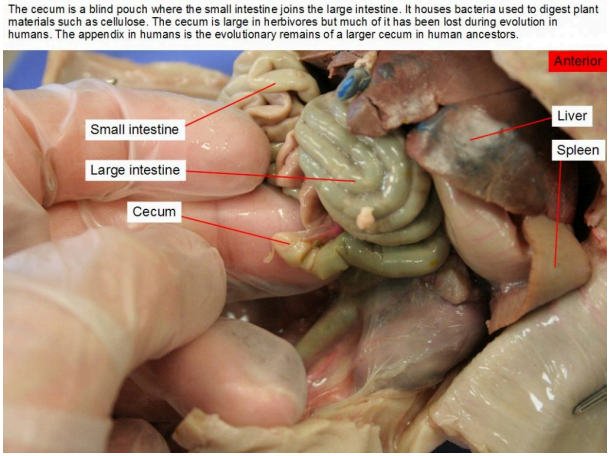

Figure 25. Digestive system with cecum lifted.

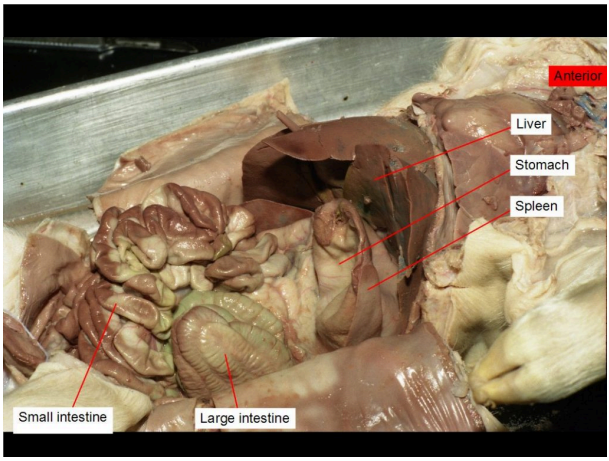

Figure 26. Digestive system.

Circulatory System

The diagrams below summarize the circulatory system of a mammal.

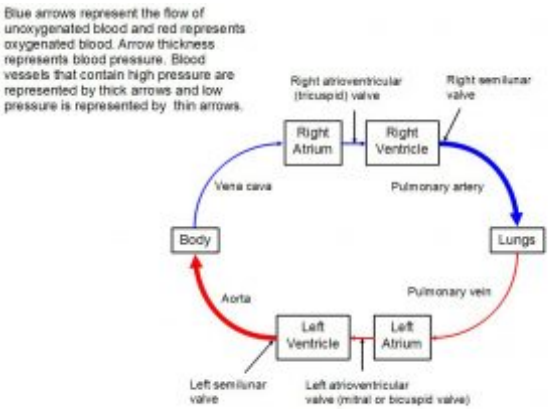

Figure 27. Systemic and pulmonary circulation.

The drawing below shows some of the major arteries that carry blood to the body. Blood vessels that branch from the aorta carry blood to most of the body.

The pulmonary artery is capable of delivering a large amount of blood to the lungs but the lungs are not needed to oxygenate the blood of a fetus, so most of the blood is diverted to the aorta. This diagram shows that the ductus arteriosus connects the pulmonary artery to the aorta and diverts blood that would otherwise go to the lungs.

Shortly after birth, the ductus arteriosus closes and blood in the pulmonary artery goes to the lungs instead of the body.

Blood passes from the left ventricle through the aortic arch and aorta to the body. The first branch of the aorta is the brachiocephalic artery. The second branch is the left subclavian artery which goes to the left front leg. The right subclavian carries blood to the right front leg and the carotids carry blood to the head.

This diagram is similar to the one on the previous page except that the two ventricles are next to each other. This more accurately reflects the structure of the heart.

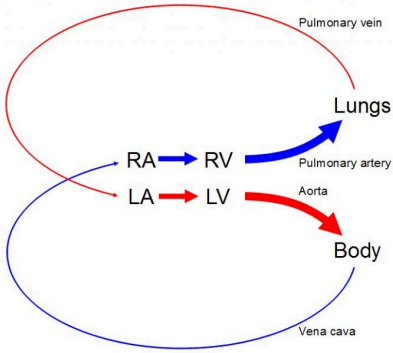

Figure 28. Systemic and pulmonary blood flow.

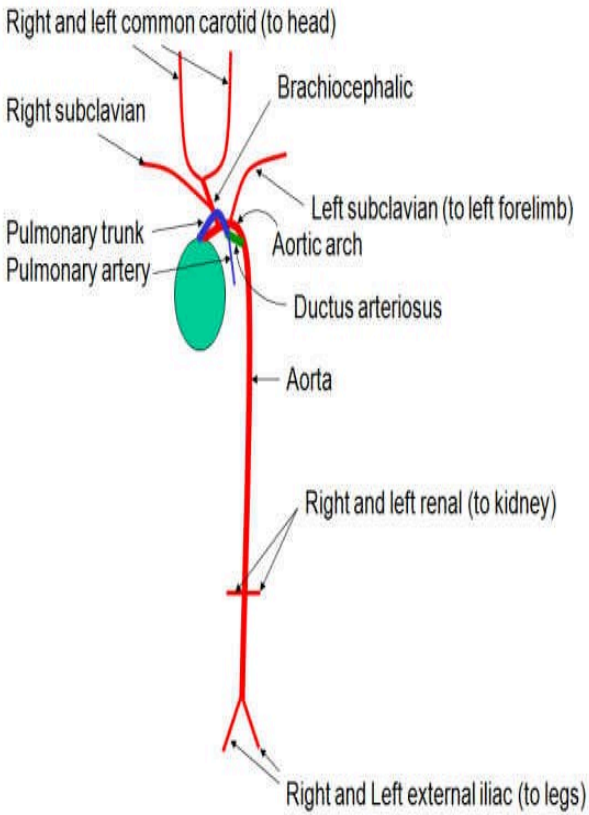

Figure 29. Major arteries.

The pericardium is a membrane that surrounds the heart and lines the pericardial cavity. It contains a lubricating fluid and isolates the heart from body movements such as the expansion and contraction of the nearby pleural (lung) cavity.

To view details of the aortic arch, ductus arteriosus, and pulmonary artery, it will be helpful to remove the left lung. With the left lung removed, the heart can be pushed to the right side to reveal the aorta and other blood vessels shown in the diagram below.

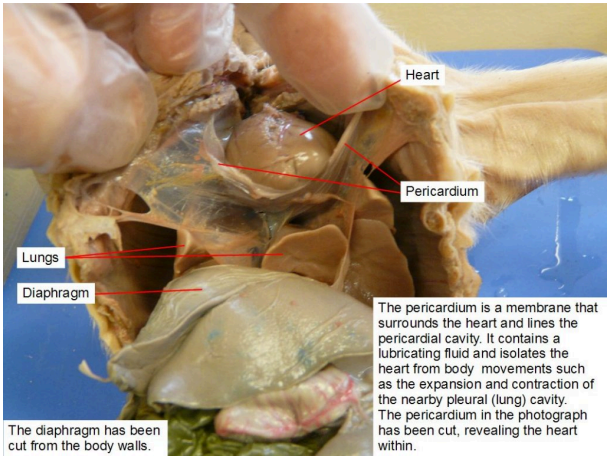

Figure 30. Thoracic cavity.

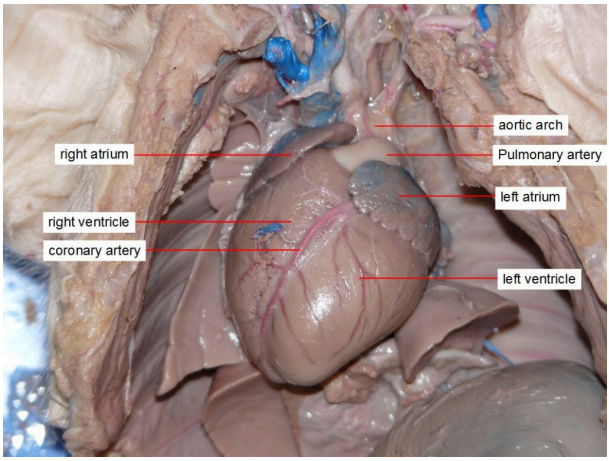

Figure 31. Thoracic cavity.

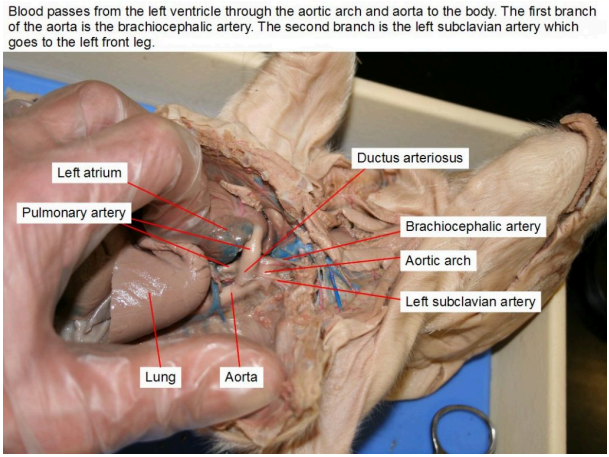

Figure 32. Major vessels.

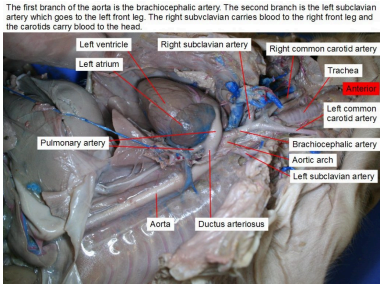

Figure 33. Thoracic cavity.

The anterior vena cava receives blood from the anterior part of the body and carries it to the right atrium.

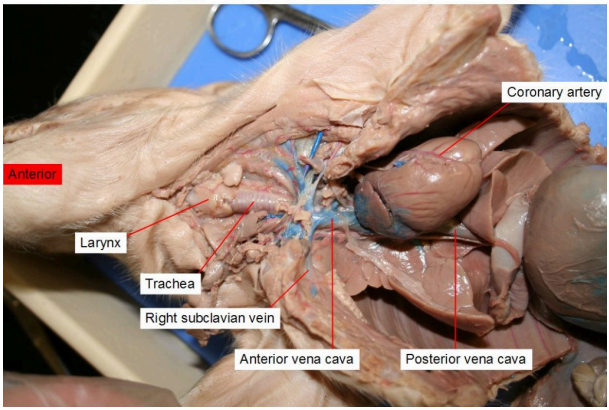

Figure 34. Thoracic cavity and open neck.

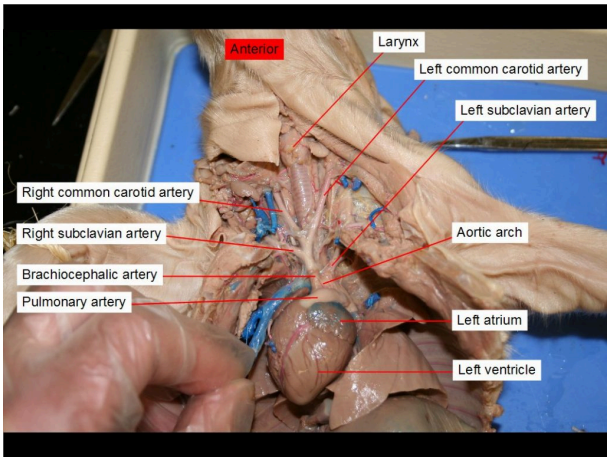

Figure 35. Thoracic cavity and open neck.

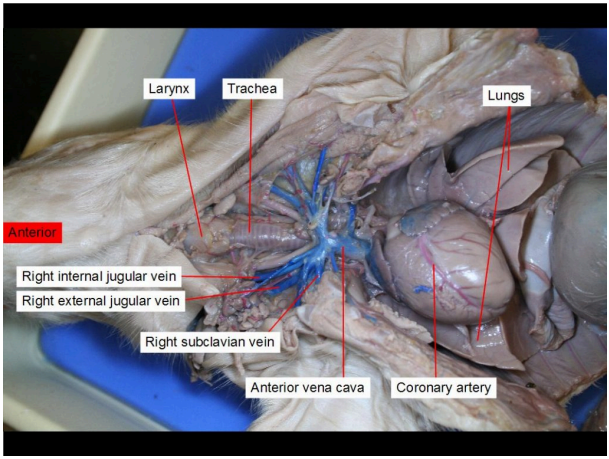

Figure 36. Thoracic cavity and open neck.

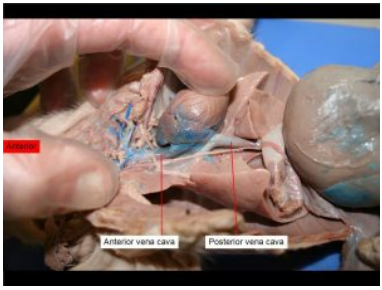

Figure 37. Vena cavae.

The posterior vena cava receives blood from the posterior portion of the body and carries it to the right atrium.

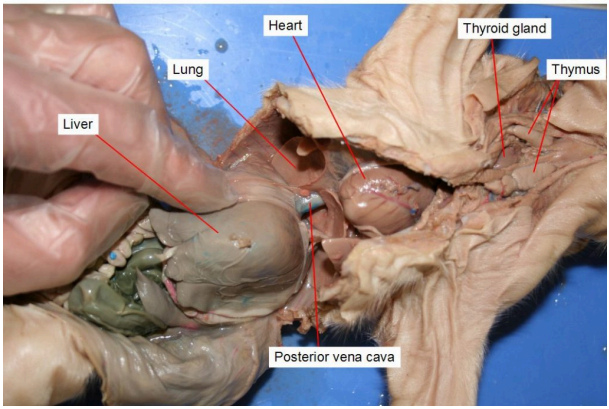

Figure 38. Open neck and thoracic and abdominal cavities.

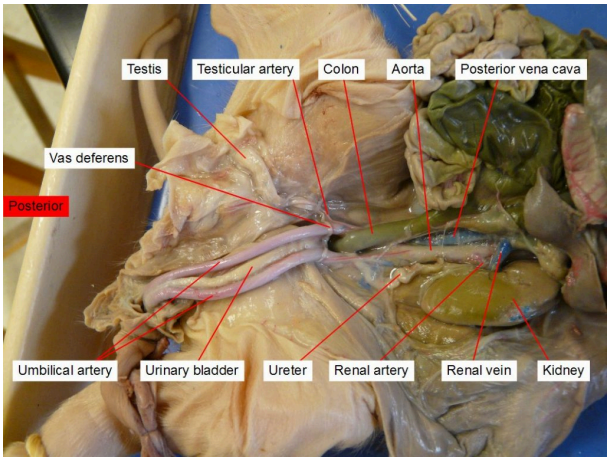

Figure 39. Urinary and male reproductive system.

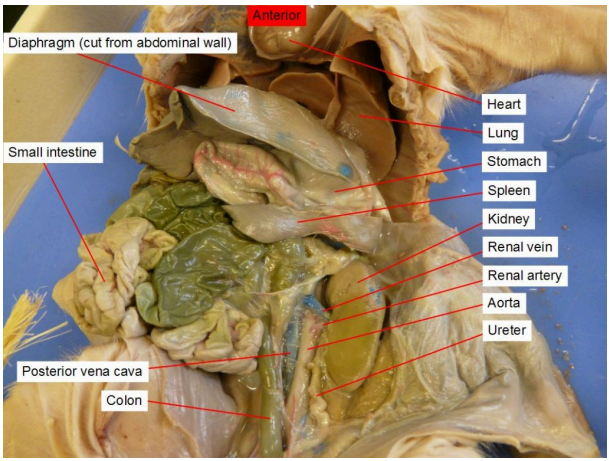

Figure 40. Lower thoracic and abdominal cavities.

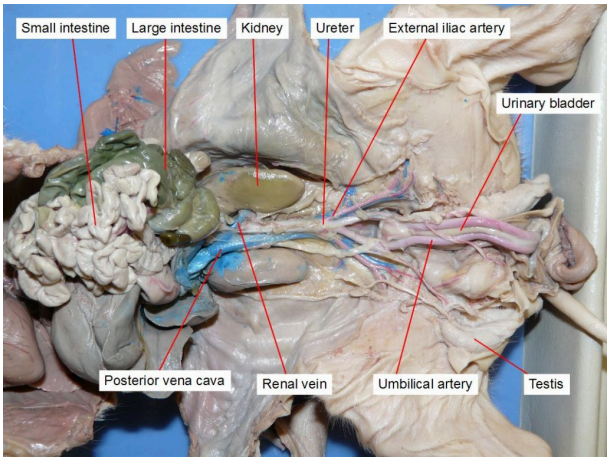

Figure 41. Digestive and urinary systems.

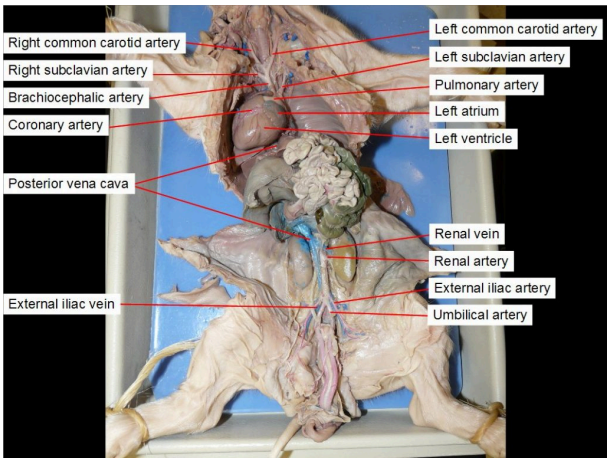

Figure 42. Open ventral surface.

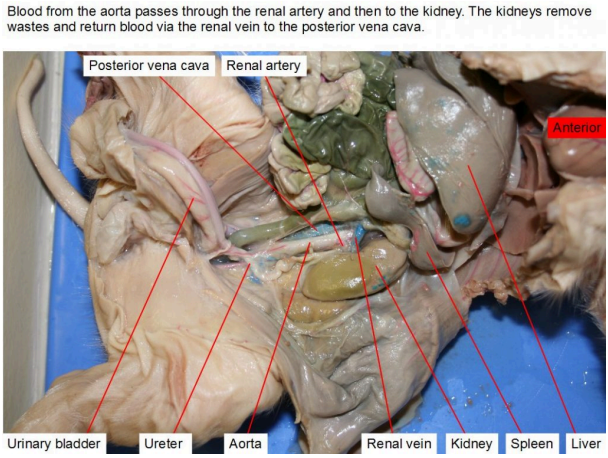

Figure 43. Urinary system.

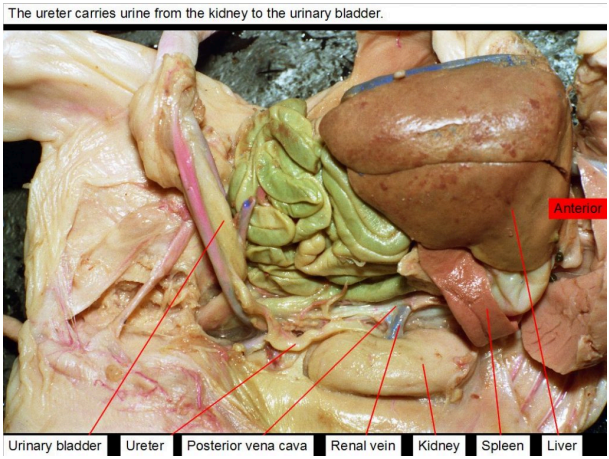

Figure 44. Pelvic cavity.

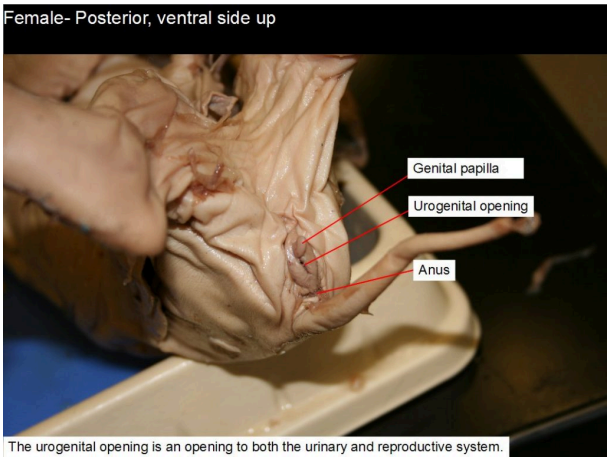

Figure 45. Female, posterior view.

The uterus of a pig is different than that of a human in that the upper part of the pig uterus is divided into two uterine horns. Near the ovaries, the uterine horns become oviducts.

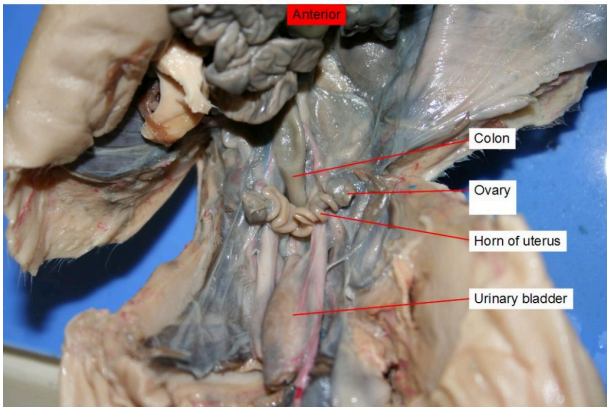

Figure 46. Female reproductive system.

The urethra (carries urine from the bladder) merges with the vagina to form a common duct called the urogenital sinus.

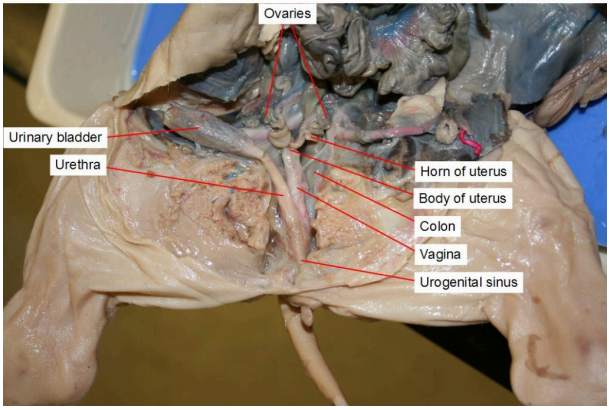

Figure 47. Female reproductive.

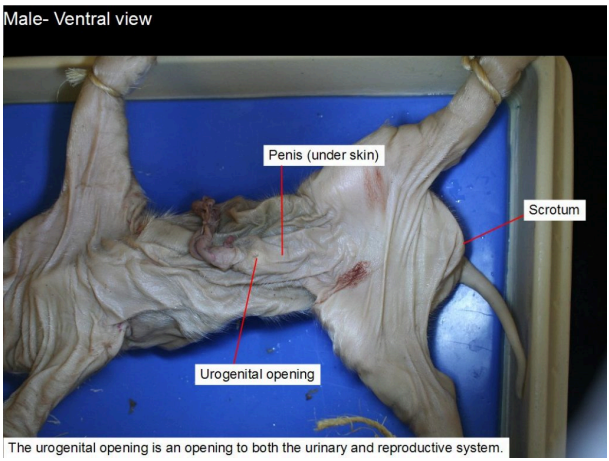

Figure 48. Male reproductive.

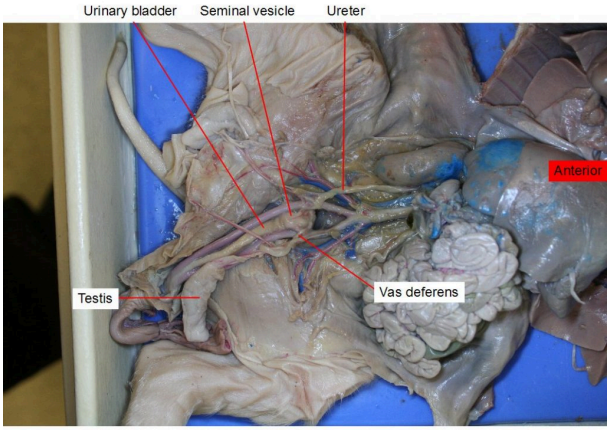

Figure 49. Male abdominal and pelvic cavities.

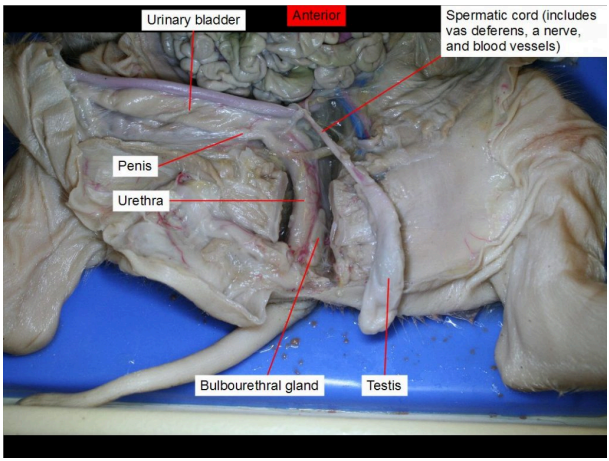

Figure 50. Male reproductive system.

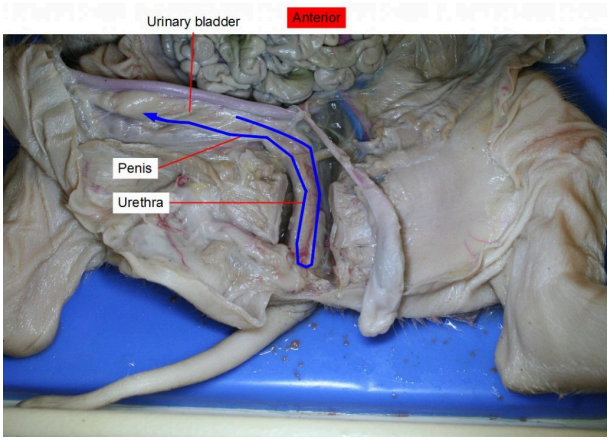

Figure 51. Path of urine flow.

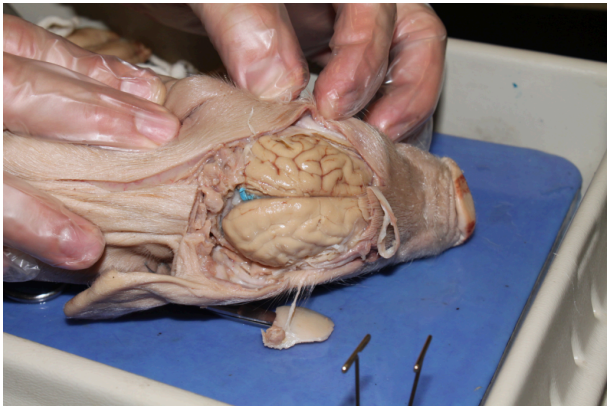

Figure 52. Surface of cerebral cortex. Take extra caution using bone cutters to open the skull.

Attributions for "Fetal Pig Dissection" MODIFIED from:
Original work by Michael J. Gregory, Clinton Community College / CC BY-NC-SA 3.0

SHERYL SHOOK